

## Effect of standard-dose Betahistine on endolymphatic hydrops: an MRI pilot study

R. Gürkov · W. Flatz · D. Keeser · M. Strupp ·  
B. Ertl-Wagner · E. Krause

Received: 11 May 2012 / Accepted: 12 June 2012 / Published online: 4 July 2012  
© Springer-Verlag 2012

**Abstract** This study aimed to assess whether standard-dose Betahistine (48 mg daily) exerts an effect upon the degree of endolymphatic hydrops in patients with Menière's disease using a retrospective case series in the setting of a tertiary neurotology referral centre. In six patients with definite unilateral Menière's disease, the degree of cochlear and vestibular endolymphatic hydrops was assessed before and after treatment with a standard dose of Betahistine (48 mg daily), using high-resolution 3 T MR imaging after intratympanic contrast medium application. The treatment duration was 3–7 months (mean 5 months), and the patients were followed-up for 6–29 months (mean 11 months). In the study cohort, the standard dose of Betahistine did not have an MR morphologically measurable beneficial effect on the degree of endolymphatic

hydrops. The results indicated no effect of standard-dose Betahistine on endolymphatic hydrops found on high-resolution MR imaging. Possible explanations are: (1) insufficient dosage or duration of treatment with betahistine, (2) insufficient resolution of the MR imaging technique, and (3) insufficient length of follow-up. Further studies addressing these issues are warranted.

**Keywords** Menière's disease · Endolymphatic hydrops · Betahistine · Magnetic resonance imaging

### Introduction

Menière's disease (MD) is a chronic inner ear disease of unknown etiology defined as the syndrome of idiopathic endolymphatic hydrops (ELH) [1] and characterized by recurrent spells of vertigo and hearing loss, tinnitus and aural pressure and a progressive loss of audiovestibular functions. The presumed cause of symptoms in MD is endolymphatic hydrops, an enlargement of the cochlear and vestibular endolymphatic space [2]. Despite the plethora of therapeutic modalities in use, there is presently no cure available and there is a lack of consensus on the first-line therapy. In North America, most neurotologists advocate a low-salt diet and diuretics as the initial therapeutic step in the management of MD patients [3]. In Germany [4], the United Kingdom [5] and other European countries, the most widely accepted treatment is oral Betahistine, which is currently routinely used at doses up to 48 mg daily.

Betahistine has a structural similarity to histamine and has a weak agonist effect on H1 and H2 receptors [6], but a strong antagonist effect on H3 receptors [7]. It may have a beneficial effect upon endolymphatic hydrops by

R. Gürkov (✉) · D. Keeser · E. Krause  
Department of Otorhinolaryngology Head and Neck Surgery,  
Integrated Centre for Balance Disorders, Grosshadern Medical  
Centre, University of Munich, Marchioninstr. 15,  
81377 Munich, Germany  
e-mail: robert.guerkov@med.uni-muenchen.de

E. Krause  
e-mail: ekrause@med.uni-muenchen.de

W. Flatz · D. Keeser · B. Ertl-Wagner  
Department of Radiology, Grosshadern Medical Centre,  
University of Munich, Marchioninstr. 15,  
81377 Munich, Germany  
e-mail: wflatz@med.uni-muenchen.de

B. Ertl-Wagner  
e-mail: birgit.ertl-wagner@med.uni-muenchen.de

M. Strupp  
Department of Neurology, Integrated Centre for Balance  
Disorders, Grosshadern Medical Centre, University of Munich,  
Marchioninstr. 15, 81377 Munich, Germany  
e-mail: mstrupp@med.uni-muenchen.de

improving the microcirculation of the stria vascularis [8]. A recent systematic review of Betahistine treatment in MD performed by the Cochrane Collaboration [9], however, concluded that there is a lack of high-quality evidence for the effectiveness of Betahistine in MD.

There is presently no objective monitoring tool available that could measure the effect that a given therapeutic intervention has upon the severity of endolymphatic hydrops. Such a monitoring tool would be of great value when evaluating new therapeutic modalities for their potential to reverse or even halt the progression of endolymphatic hydrops in MD patients. However, it is now possible to visualise endolymphatic hydrops in MD patients by magnetic resonance (MR) imaging [10]. Furthermore, the degree of ELH is correlated with loss of audiovestibular functions [11], underlining the importance of ELH for the natural history of MD. In the present pilot study, we analyse whether a treatment with standard-dose Betahistine over several months has an effect upon the degree of ELH in patients with MD, as determined by MR imaging.

## Methods

Six patients with definite unilateral MD [1] were enrolled in this study after written informed consent. The study protocol was approved by the institutional review board (Ethics Committee of the University of Munich). The study was carried out at a university tertiary referral centre for balance disorders. At the time of diagnosis, ELH was assessed by MR imaging, in addition to routine neurotological testing. Patients then received oral Betahistine at a daily dose of 48 mg (16 mg three times). A second MRI examination was performed after Betahistine treatment and compared to the pre-treatment examination.

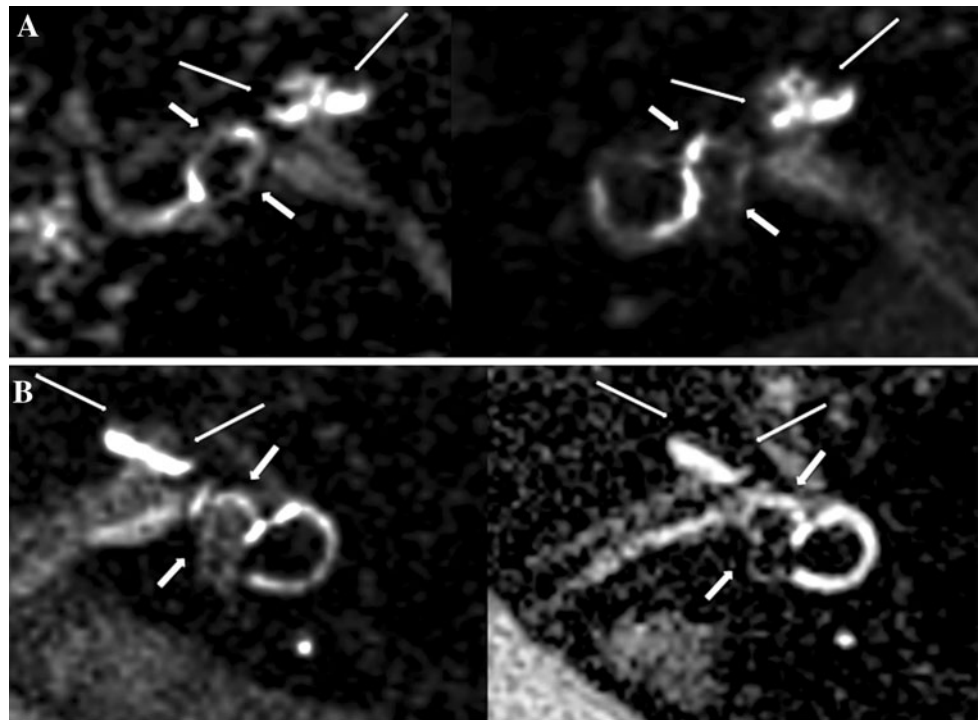
Audiovestibular testing and MR imaging were performed as previously described [11]. In brief, a 1:8 diluted gadolinium-based contrast agent (Omniscan®, GE Healthcare Medical Diagnostics, Amersham, UK) was injected intratympanically, with the patient situated in a supine position with the head turned 45° away from the surgeon. 24 h later, the MRI scan was performed with a 3D FLAIR sequence on a 3 T MR unit (Magnetom Verio, Siemens Healthcare, Erlangen, Germany), using a commercially available four-channel flexible surface coil combined with an eight-channel head coil. The MR image analysis was performed by an experienced neurotologist and an experienced head and neck radiologist in a blinded consensus reading. The degree of ELH was determined as previously described on a scale of 0–3 [11]. The second examination of each individual patient was analyzed for the presence of a change in ELH severity in any direction

**Table 1** Clinical characteristics of the study cohort

Case no.	Age (a)	Disease duration (m)	Duration of treatment (m)	Follow-up (m)	PTA (dB)	SP/AP-ratio	VEMP (IAR)	Canal paresis (%)	Vertigo attacks before therapy (per 6 m)	Vertigo attacks at the end of therapy (per 6 m)	Subjective improvement	ELH Cochlea	ELH Vestibulum
1	75	240	7	14	59	0.75	2.59	4	6	0	Yes	3	3
2	70	240	5	29	84	n.m.	n.m.	64	22	2	Yes	2	3
3	39	84	4	6	39	n.m.	0.65	56	25	0	Yes	2	3
4	29	228	5	6	46	n.m.	n.m.	88	12	0	Yes	1	1
5	61	96	3	7	60	0.84	1.0	35	25	10	Yes	3	3
6	43	8	5	6	43	0.85	n.m.	42	15	4	Yes	2	3

*n.m.* not measurable, *PTA* pure tone average at 0.5–3 kHz, *VEMP* vestibular evoked myogenic potential, *IAR* Interaural amplitude ratio, *ELH* endolymphatic hydrops

**Fig. 1** **a** 3D-FLAIR MR image of the right inner ear of patient no. 2. There is no apparent change in the severity of endolymphatic hydrops in the cochlea (*long arrows*) or in the vestibulum (*short arrows*). **b** 3D-FLAIR MR image of the left inner ear of patient no. 5. There is no apparent change in the severity of endolymphatic hydrops in the cochlea (*long arrows*) or in the vestibulum (*short arrows*)



(improvement or worsening) in comparison to the first examination.

## Results

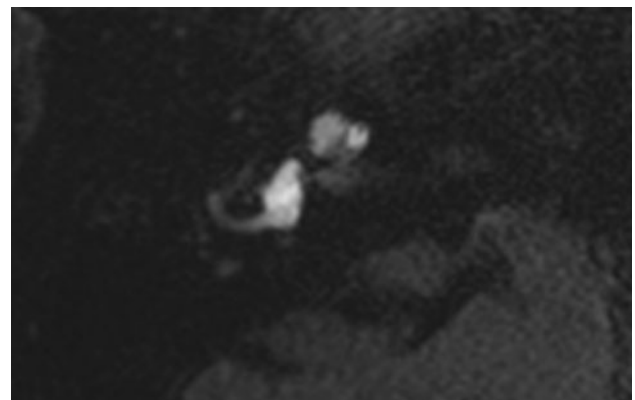
The baseline clinical characteristics of the study cohort are summarized in Table 1. The patients' age ranged from 29 to 75 years (mean 53 years). The disease duration (defined as the time since the onset of the first disease-related symptom, i.e. vertigo, hearing loss, tinnitus or aural pressure) ranged from 8 to 240 months (mean 149 months). The treatment duration ranged from 3 to 7 months (mean 4.8 months). The length of follow-up was 6–29 months (mean 11 months).

The average hearing loss at the frequencies 0.5–3 kHz ranged from 39 to 84 dB nHL (mean 55.1 dB nHL). On electrocochleography, the summing potential/action potential (SP/AP) ratio could be determined in four of the six patients, it was elevated ( $>0.4$ ) in three of these four patients. The vestibular evoked myogenic potential (VEMP) interaural amplitude ratio could be measured in three of the six patients, in the remaining patients no VEMP response could be obtained from the diseased ear. On caloric video-nystagmography, five of the six patients had evidence of horizontal semicircular canal paresis (side difference  $>20\%$ ).

The number of vertigo attacks lasting at least 20 min was recorded during the 6 months before initiation of therapy and during the last 6 months of therapy. In cases

where the treatment duration was shorter than 6 months, the number of vertigo attacks was extrapolated to a 6-month interval. All seven patients subjectively judged the treatment effect as positive, which was reflected by a substantial reduction of the number of vertigo attacks. An improvement of other symptoms such as hearing loss, tinnitus or aural pressure was not consistently reported. All seven patients continued the Betahistine treatment during the follow-up period. One patient's symptoms worsened during follow-up (case no. 2), and this patient opted for endolymphatic sac surgery, with resolution of vertigo attacks thereafter.

The cochlear ELH was classified as grade 1 in one patient, grade 2 in three patients and grade 3 in two



**Fig. 2** 3D-FLAIR MR image of the right inner ear of a healthy control subject. The hypointense endolymphatic space is barely visible and not enlarged

patients. The vestibular ELH was classified as grade 3 in all six patients. In all patients, the severity of ELH did not change after treatment with Betahistine. Representative MR images of the inner ear are shown in Fig. 1. For reference, a healthy control subject without evidence of ELH is shown in Fig. 2. The degree of enlargement of the endolymphatic space (hypointense signal) in comparison to the perilymphatic space (hyperintense signal) did not differ between the two time points in the individual patients.

## Discussion

MR imaging has only recently emerged as a tool for in vivo detection of endolymphatic hydrops. Despite the ongoing debate on a possible ototoxic effect of intratympanically applied gadolinium-based contrast agents (GBCA) [12], this diagnostic modality is being increasingly used [13–17]. However, the morphologic monitoring of the severity of ELH during therapeutic interventions in patients with MD may become a valuable new tool for the assessment of the effect of a treatment on an important morphologic feature of MD. In our study cohort, we could not detect an effect of a standard-dose regimen of oral Betahistine upon the severity of ELH. There are several limitations to our study: First, the mean treatment duration was 7 months. This interval may not be long enough to detect a reduction of endolymph volume caused by Betahistine. Second, the current standard dose of 48 mg daily may not be sufficient to exert a measurable effect upon the ELH in humans. This is supported by the dose dependency of the effect of BH upon the cochlear microcirculation in animal models [18, 19]. Furthermore, retrospective clinical studies have reported that a higher dose of 144 mg daily [20] or even 480 mg daily [21] has a greater effect upon clinical symptoms in MD than the standard-dose. Third, the current state-of-the-art MR imaging technology still has some limitations regarding the quantification of endolymphatic hydrops. The grading of ELH is reliant upon the subjective judgement of the examiner and there is no automated and validated volumetric tool available for the quantification of ELH in humans. It is therefore conceivable that slight changes in the degree of ELH may not be recognized with the imaging techniques currently used.

Future studies should focus on further improving the imaging technology for the quantification of ELH by developing 3D-based volumetry of inner ear compartments and then use this tool for the monitoring of therapeutic interventions during controlled clinical trials in MD.

**Acknowledgments** This study was supported by the Federal German Ministry of Education and Research (Grant no. 01EO0901). The corresponding author had full access to all the data in the study and

takes responsibility for the integrity of the data and the accuracy of the data analysis.

**Conflict of interest** None of the authors have a conflict of interest to declare.

## References

1. Committee on Hearing and Equilibrium guidelines for the diagnosis and evaluation of therapy in Meniere's disease. American Academy of Otolaryngology-Head and Neck Foundation, Inc. (1995) *Otolaryngol Head Neck Surg* 113:181–185
2. Merchant SN, Adams JC, Nadol JB Jr (2005) Pathophysiology of Meniere's syndrome: are symptoms caused by endolymphatic hydrops? *Otol Neurotol* 26:74–81
3. Kim HH, Wiet RJ, Battista RA (2005) Trends in the diagnosis and the management of Meniere's disease: results of a survey. *Otolaryngol Head Neck Surg* 132:722–726
4. Westhofen M (2009) Meniere's disease: evidence and controversies. *HNO* 57:446–454
5. Smith WK, Sankar V, Pfliegerer AG (2005) A national survey amongst UK otolaryngologists regarding the treatment of Meniere's disease. *J Laryngol Otol* 119:102–105
6. Timmerman H (1991) Histamine agonists and antagonists. *Acta Otolaryngol Suppl* 479:5–11
7. Arrang JM, Devaux B, Chodkiewicz JP et al (1988) H3-receptors control histamine release in human brain. *J Neurochem* 51:105–108
8. Martinez DM (1972) The effect of Serc (betahistine hydrochloride) on the circulation of the inner ear in experimental animals. *Acta Otolaryngol Suppl* 305:29–47
9. James AL, Burton MJ (2001) Betahistine for Meniere's disease or syndrome. *Cochrane Database Syst Rev* (1):CD001873
10. Nakashima T, Naganawa S, Sugiura M et al (2007) Visualization of endolymphatic hydrops in patients with Meniere's Disease. *The Laryngoscope* 117:415–420
11. Gurkov R, Flatz W, Louza J et al (2011) In vivo visualization of endolymphatic hydrops in patients with Meniere's disease: correlation with audiovestibular function. *Eur Arch Otorhinolaryngol* 268:1743–1748
12. Louza J, Flatz W, Krause E, Gürkov R (2012) Short-term audiologic effect of intratympanic gadolinium contrast agent application in patients with Meniere's disease. *Am J Otolaryngol* [Epub ahead of print]
13. Suzuki H, Teranishi M, Naganawa S et al (2011) Contrast-enhanced MRI of the inner ear after intratympanic injection of meglumine gadopentetate or gadodiamide hydrate. *Acta Otolaryngol* 131:130–135
14. Kato M, Teranishi M, Katayama N et al (2011) Association between endolymphatic hydrops as revealed by magnetic resonance imaging and caloric response. *Otol Neurotol* 32:1480–1485
15. Hornibrook J, Coates M, Goh A et al (2012) Magnetic resonance imaging for Meniere's disease: correlation with tone burst electrocochleography. *J Laryngol Otol* 126:136–141
16. Horii A, Osaki Y, Kitahara T et al (2011) Endolymphatic hydrops in Meniere's disease detected by MRI after intratympanic administration of gadolinium: comparison with sudden deafness. *Acta Otolaryngol* 131:602–609
17. Fang ZM, Chen X, Gu X, Liu Y, Zhang R, Cao DR, He HG (2012) A new magnetic resonance imaging scoring system for perilymphatic space appearance after intratympanic gadolinium injection, and its clinical application. *J Laryngol Otol* 126(5):454–459

18. Laurikainen E, Miller JM, Nuttall AL et al (1998) The vascular mechanism of action of betahistine in the inner ear of the guinea pig. *Eur Arch Otorhinolaryngol* 255:119–123
19. Laurikainen E, Miller JF, Pyykkö I (2000) Betahistine effects on cochlear blood flow: from the laboratory to the clinic. *Acta Otolaryngol Suppl* 544:5–7
20. Strupp M, Hupert D, Frenzel C (2008) Long-term prophylactic treatment of attacks of vertigo in Meniere's disease—comparison of a high with a low dosage of betahistine in an open trial. *Acta Otolaryngol* 128:520–524
21. Lezius F, Adrion C, Mansmann U et al (2011) High-dosage betahistine dihydrochloride between 288 and 480 mg/day in patients with severe Meniere's disease: a case series. *Eur Arch Otorhinolaryngol* 268:1237–1240