*British Journal of Dermatology* 2000; **142:** 991–1002.

# Re-epithelialization rate and protein expression in the suction-induced wound model: comparison between intact blisters, open wounds and calcipotriol-pretreated open wounds

T.LEIVO,*†‡ U.KIISTALA,‡ M.VESTERINEN,§ K.OWARIBE,¶ R.E.BURGESON,** I.VIRTANEN* AND A.OIKARINEN†

*Department of Anatomy, Institute of Biomedicine, PO Box 9, FIN-00014 University of Helsinki, Helsinki, Finland
†Department of Dermatology, Oulu University Hospital and University of Oulu, Oulu, Finland
‡Department of Dermatology, Central Military Hospital, Helsinki, Finland
§Department of Dentistry, University of Helsinki, Finland
¶Nagoya University, School of Informatics and Sciences/Graduate School of Human Informatics, Biological Systems, Chikusa-ku, Nagoya 464-01, Japan
**Cutaneous Biology Research Center, Harvard Medical School, Massachusetts General Hospital E, Bldg 149, 13th St, Charlestown, MA 02129, U.S.A.

Accepted for publication 31 December 1999

**Summary** We have investigated re-epithelialization following induction of suction blisters in humans in intact blisters, open wounds, i.e. blister roofs removed immediately after blister induction, and calcipotriol-pretreated open wounds. Intact blisters simulate blister healing in bullous disease, while open wounds simulate re-epithelialization during wound healing. Re-epithelialization was clearly faster in open wounds than in intact blisters, and was not affected by calcipotriol pretreatment. Bullous pemphigoid antigen 2 (BP180), bullous pemphigoid antigen 1 (BP230), plectin/hemidesmosomal 1 protein (HD1), laminin 5, laminin $\alpha 5$, laminin $\beta 1$, type VII collagen, tenascin-C, $\beta 4$, $\alpha v\beta 5$, $\alpha 5$ and $\alpha 9$ integrins were studied in intact blisters and open wounds by immunohistochemistry. Hemidesmosomal plaque proteins BP230 and plectin/HD1, which connect the keratin cytoskeleton to the hemidesmosome, appeared earlier at the leading edge in intact blisters than in open wounds. Band-like immunostaining in the basement membrane for laminin 5, $\alpha 5$ and $\beta 1$ chains was continuous in blister bases, but partially discontinuous in open wound bases. The other antigens studied showed similar expression in intact blisters and open wounds. BP180, BP230, plectin/HD1, $\beta 4$ integrin, laminin 5 and tenascin-C expression were further studied in calcipotriol-pretreated open wounds. Calcipotriol did not affect the expression of these antigens. The immunohistochemical results suggest that the keratin cytoskeleton is linked to the basal plasma membrane of migrating basal cells via BP230 and plectin/HD1 earlier in the more slowly re-epithelializing blisters than in open wounds. An intact laminin sheath may inhibit keratinocyte migration in intact blisters.

*Key words*: calcipotriol, hemidesmosome, integrin, laminin, suction blister, wound healing

Re-epithelialization of cutaneous wounds includes keratinocyte proliferation, migration and differentiation. Uninjured keratinocytes along the wound edges are stimulated to proliferate and migrate laterally to cover the wound bed.[1] This requires the keratinocytes to be released from their cell-adhering structures, e.g. hemidesmosomes, which are multiprotein complexes at the basal plasma membrane of basal cells. Hemidesmosomes mediate stable keratinocyte anchorage to the basement membrane.[2,3] Keratinocytes use adhesion molecules, such as integrins, to mediate cell–cell and cell–matrix interactions during re-epithelialization. The association of the two subunits, $\alpha$ and $\beta$, is necessary for the functional expression of integrin on the cell surface. Integrins recognize matrix components, such as collagens, fibronectin, tenascin and laminins.[4] Laminins are the major structural components of the cutaneous basement membrane, but also function as signalling

Correspondence: Tomi Leivo M.D., Melkonkatu 1 B 51, 00210 Helsinki, Finland.

molecules modulating proliferation, migration and differentiation. Laminins consist of three polypeptide chains, $\alpha$, $\beta$ and $\gamma$, which all have several isoforms. Laminin 5, which is a component of anchoring filaments, serves as a ligand for hemidesmosomal $\alpha 6\beta 4$ integrin.[2,5]

Calcipotriol is a vitamin D analogue that is used as an antipsoriatic drug for its direct antiproliferative effects on keratinocytes.[6] It enhances the secretion and activity of transforming growth factor (TGF)-$\beta$1, which has antiproliferative effects on keratinocytes but is also considered to promote re-epithelialization.[7–9] Vitamin D inhibits cell migration.[10] These data suggest that calcipotriol might either retard or enhance re-epithelialization. As the effects of this extensively used drug on wound healing have not been studied in humans *in vivo*, we decided to study its effect on re-epithelialization.

In the present study, we used the suction blister method,[11] where suction-induced blister formation takes place within the lamina lucida layer of the basement membrane, to study re-epithelialization. We studied: (i) intact blisters; (ii) open wounds; and (iii) calcipotriol-pretreated open wounds. Intact blisters simulate blister healing in bullous disease and open wounds simulate re-epithelialization during wound healing. We studied the re-epithelialization rate and the immunohistochemical expression of hemidesmosomal proteins, integrins and matrix components in our re-epithelialization models. Some hemidesmosomal proteins were also studied by body site, to ensure that our results apply to the whole body surface, as regional variation has previously been described in bullous pemphigoid antigen with patient sera.[12]

To our knowledge, this is the first morphological and immunohistochemical study in which human blister healing has been compared with open wound healing, and in which bullous pemphigoid antigen 2 (BP180), bullous pemphigoid antigen 1 (BP230), (HD1) and α9 integrin have been studied in human cutaneous wound healing.

## Materials and methods

### *Tissues*

All volunteers, aged 19–24 years, were healthy males with no skin disease and using no systemic or topical medication.

*Part 1.* Suction blisters were induced bilaterally on the lower abdominal skin in six volunteers. In three volunteers, the blister roofs were protected from mechanical trauma with foamy plastic rings until the biopsies were taken (Table 1). Only intact blister samples were taken. In the other three volunteers, the blister roofs were removed immediately after blister induction (Table 1) and the open wounds were covered with dry wound dressings until the biopsies were taken. The biopsies were taken on the second, fourth and ninth days after blister induction from all the six volunteers.

*Part 2.* Three volunteers participated in a double-blind study. Two areas of 8 × 8 cm were marked bilaterally on the lower abdominal skin. Every volunteer applied vehicle to the left-hand side and 50 $\mu g\ g^{-1}$ calcipotriol cream (Daivonex® cream,

**Table 1.** Number of samples studied per wound type

| Wound type | Day | HE | BP180 | BP230 | Plectin | β4 | αvβ5 | α5 | α9 | Ln5 | Lnα5 | Lnβ1 | VII | Tn |
|---|---|---|---|---|---|---|---|---|---|---|---|---|---|---|
| Blister | 2nd | 3 | 3 | 3 | 3 | 3 | 3 | 2 | 1 | 3 | 2 | 2 | 2 | 3 |
| Open wound | 2nd | 3 | 3 | 3 | 3 | 1 | 3 | 2 | 2 | 2 | 2 | 2 | 2 | 3 |
| Blister | 4th | 3 | 3 | 3 | 3 | 3 | 3 | 2 | 2 | 2 | 2 | 2 | 2 | 3 |
| Open wound | 4th | 3 | 2 | 2 | 2 | 1 | 2 | 2 | 2 | 2 | 2 | 2 | 2 | 2 |
| Blister | 9th | 3 | 3 | 2 | 3 | 2 | 3 | 2 | 1 | | | | | 3 |
| Open wound | 9th | 3 | 3 | 2 | 3 | 2 | 3 | 2 | 1 | | | | | 3 |
| Vehicle | | | | | | | | | | | | | | |
| Open wound | 2nd | 2 | 2 | 2 | 2 | 2 | | | | 2 | | | | 1 |
| Open wound | 4th | 3 | 3 | 3 | 3 | 3 | | | | 2 | | | | 3 |
| Calcipotriol | | | | | | | | | | | | | | |
| Open wound | 2nd | 2 | 2 | 2 | 2 | 2 | | | | 2 | | | | 1 |
| Open wound | 4th | 3 | 3 | 3 | 3 | 3 | | | | 2 | | | | 3 |

HE, haematoxylin-eosin; Plectin, plectin/HD1; β4, β4 integrin; αvβ5, αvβ5 integrin; α5, α5 integrin; α9, α9 integrin; Ln5, laminin 5; Lnα5, laminin α5 chain; Lnβ1, laminin β1 chain; VII, VII collagen; Tn, tenascin-C; vehicle, pretreatment with vehicle; calcipotriol, pretreatment with calcipotriol.

Lövens, Copenhagen, Denmark) to the right-hand side twice a day for 14 days. Compliance was assessed with a diary and ranged from 26/28 to 28/28 days. After 2 weeks' pretreatment, suction blisters were induced on both sides and the blister roofs were removed immediately. The wound areas were covered with dry wound dressings. Biopsies were taken on the second and fourth days after blister induction (Table 1). Each volunteer served as his own control, as biopsies were taken from both the calcipotriol- and the vehicle-treated sides on each occasion in order to exclude any interindividual variation between the two study groups. In all cases, neither the investigator nor the subjects were aware of the content of the cream used at each

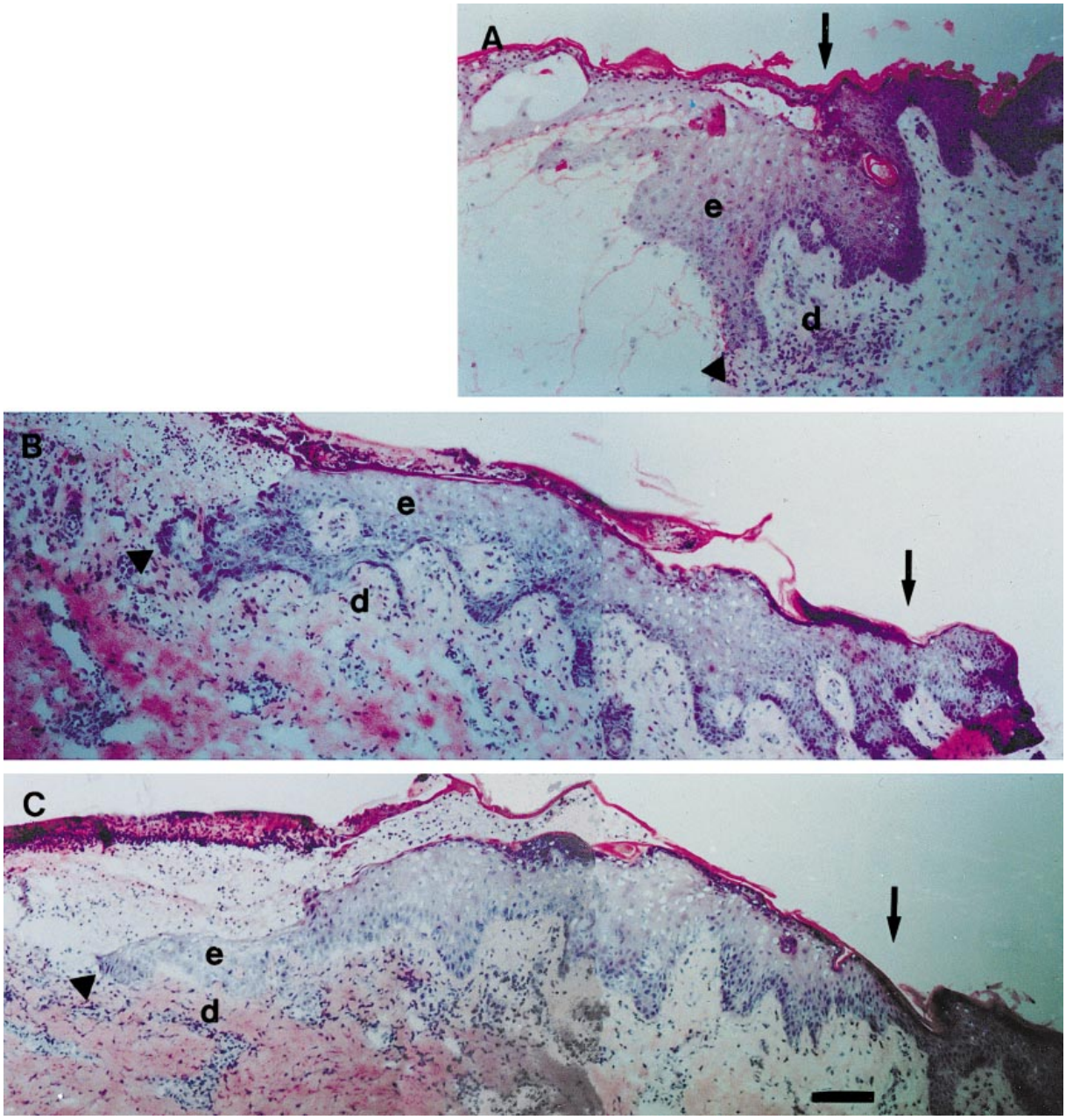


**Figure 1.** Re-epithelialization rate in 4-day-old samples. Blisters (A) showed considerably slower re-epithelialization than open wounds (B). Vehicle-pretreated (B) open wounds showed a re-epithelialization rate comparable with that in calcipotriol-pretreated (C) open wounds. (A–C) e = epidermis, d = dermis, arrow = edge of the regenerating area, arrowhead = tip of the leading edge. Scale bar, 36 μm.

side. The code was broken after the findings had been analysed.

*Part 3.* Nineteen biopsies of normal skin were taken from different body sites in 10 volunteers: proximal extensor arm (five), proximal flexor arm (four), extensor knee (two), popliteal fossa (two), scalp (three) and upper chest (three).

In parts 1 and 2, every biopsy was cut in half in the middle of the wounded area. Thus, all the sections studied had a wounded area approximately 6 mm wide with one re-epithelialization front on both sides or new epidermis on the wounded area in the older samples. All biopsies were snap-frozen in liquid nitrogen and stored at − 70 °C until used.

This study was done with the approval of the research ethics committee of the Central Military Hospital, Helsinki.

### *Antibodies*

The following monoclonal antibodies were used: 1D1 (1 : 8) to BP180 antigen and IE5 (1 : 30) to BP230 antigen,[13] HD-121 (1 : 20) to plectin/HD1 antigen,[14,15] AA3 (1 : 100) to β4 integrin (Chemicon, Temecula, CA, U.S.A.[16]), P1F6 (1 : 800) to αvβ5 complex (Becton Dickinson, San Jose, CA, U.S.A.[17]), BIE5 (1 : 5) to α5 integrin (Dr C.H.Damsky, Department of Stomatology, University of California, San Francisco, CA, U.S.A.[18]), P1D6 (1 : 1000) to α5 integrin (Chemicon), Y9A2 (1 : 2) to α9 integrin (Dr D.Sheppard, Lung Biology Center, University of California, San Francisco, CA, U.S.A.[19]), 4C7 (1 : 3000) to laminin α5 chain (Dr E.Engvall, La Jolla Cancer Research Center, La Jolla, CA, U.S.A.[20]), 114DG10 (1 : 2000) to laminin β1 chain,[21] NP32 (1 : 500) to collagen VII[22] and BC-4 (1 : 5) to tenascin-C (Dr L.Zardi, Istituto Nazionale per la Ricerca sul Cancro, Genoa, Italy[23,24]). Polyclonal kalinin 4101 (1 : 400) was used to detect laminin 5.[25]

### *Light microscopy*

The tissue specimens were sectioned at 6 μm and stained with haematoxylin and eosin.

### *Immunohistochemistry*

An indirect immunofluorescence technique was used. The frozen tissue specimens were first sectioned at 6 μm and fixed in acetone precooled to − 20 °C. The sections were then incubated with the respective primary antisera, followed by fluorescein isothiocyanate (FITC)-coupled goat antimouse IgG serum, FITC-coupled goat antirat IgG serum or FITC-coupled goat antirabbit IgG serum (Jackson Immunoresearch, West Grove, PA, U.S.A.). The dermal structures in our skin samples and other human tissue samples served as positive controls in the immunohistochemical studies. Staining controls also included wound samples processed by omitting the specific antiserum. No staining reactions were seen in these experiments (data not shown).

## Results

The normal open wound healing results (haematoxylin and eosin stained and immunohistochemistry) include the vehicle-pretreated open wound samples.

### *Haematoxylin and eosin staining*

On the second and fourth days, re-epithelialization was clearly faster in the open wounds (Fig. 1B) than in the samples with intact blister roofs (Fig. 1A). On the ninth day, all the wound bases in both open wounds and

**Figure 2.** BP180, BP230 and plectin/HD1 in regenerating epidermis. (A) No or negligible immunoreactivity for BP180 at the leading regenerating edge (thick arrows) and at the wound base (arrowheads) in a 4-day-old open wound sample (re-epithelialization from left to right in this figure). Weak immunoreactivity for BP180 in basal cell layer behind the leading edge (thin arrow). Broken line = upper pole of the regenerating epidermis. (B) Strong cytoplasmic/pericellular and band-like basement membrane zone immunoreactivity for BP180 in the regenerating area (arrows) in a 4-day-old blister sample (re-epithelialization from right to left in this figure). (C) Discontinuous band-like immunoreactivity for BP180 in a plain wound base (arrows) in a 2-day-old sample. (D) No immunoreactivity for BP230 at the leading edge (thick arrows) in a 2-day-old open wound sample (re-epithelialization from right to left in this figure). Weak band-like positivity for BP230 behind the leading edge in the regenerating area (thin arrows). (E) Distinct band-like and cytoplasmic positivity for BP230 in the regenerating area (arrows) in a 2-day-old blister (re-epithelialization from right to left in this figure). (F) Distinct band-like immunoreactivity for BP230 in the basement membrane zone in regenerating area (arrows) in a 4-day-old open wound sample (re-epithelialization from right to left in this figure). (G) No immunoreactivity for plectin/HD1 in the leading edge of a 2-day-old open wound sample (arrows) (re-epithelialization from right to left in this figure). (H) In contrast, distinct band-like immunoreactivity for plectin/HD1 in the regenerating area (arrows) in a 2-day-old blister, blister roof (arrowheads). (A,B,D–H) Asterisk = tip of the leading edge (A–H) d = dermis (A,B,D–H) e = epidermis. Scale bar (A,B,D,E,G,H) 36 μm; (C,F) 22 μm.

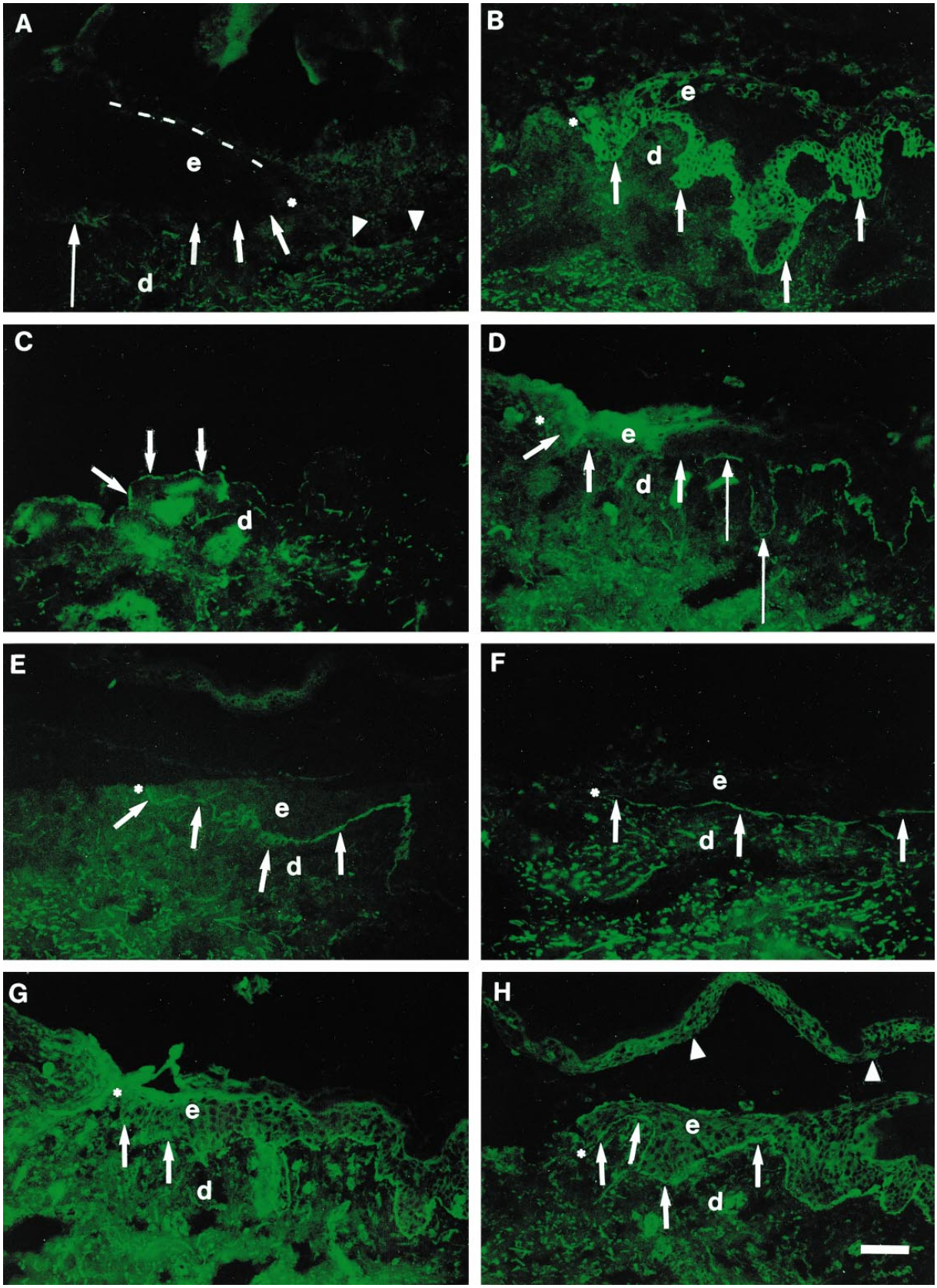
A
e
d
B
e
d
C
d
D
e
d
E
e
d
F
e
d
G
e
d
H
e
d

**Table 2** Summary of immunofluorescence results in 2- and 4-day-old blisters and open wounds

| Molecule | Localization and intensity of staining | |
|---|---|---|
| | Blisters | Open wounds |
| BP180 | | |
| edge | Cytoplasmic/pericellular and band-like BMZ positivity (− to ++) | Cytoplasmic/pericellular and band-like BMZ positivity (− to ++) |
| base | (−) | Discontinuous band-like positivity (+) in one sample, others (−) |
| BP230 | | |
| edge | Band-like BMZ positivity (+/++) | 2-day-old, cytoplasmic positivity (−/+); 4-day-old, band-like BMZ positivity (+/++) |
| base | (−) | (−) |
| Plectin/HD1 | | |
| edge | Band-like BMZ positivity (+/++) | 2-day-old (−); 4-day-old, band-like BMZ positivity (+/++) |
| base | (−) | (−) |
| β4 integrin | | |
| edge | Diffuse positivity (+/++), polarization in cells next to wound bed (++) | Diffuse positivity (+/++), polarization in cells next to wound bed (++) |
| base | (−) | (−) |
| Laminin 5 | | |
| edge | Cytoplasmic positivity (− to ++) | Cytoplasmic positivity (− to ++) |
| under regen. epid. | Continuous band-like staining (++) | Continuous band-like staining (++) |
| base | Continuous band-like staining (++) | Discontinuous band-like staining (+/++) |
| roof | Discontinuous band-like/cytoplasmic staining (+/++) | |
| Laminins α5 and β1 | | |
| edge | (−) | (−) |
| under regen. epid. | Continuous band-like staining (++) | Continuous band-like staining (++) |
| base | Continuous band-like staining (++) | Discontinuous band-like staining (+/++) |
| roof | (−) | |
| Tenascin-C | | |
| edge | Cytoplasmic positivity (−/+) | Cytoplasmic positivity (−/+) |
| base | (++) | (++) |
| under regen. epid. | (++) | (++) |
| Collagen VII | | |
| αvβ5 complex | As in normal skin | As in normal skin |
| α5 and α9 integrin | (−) staining in regen. epid. | (−) staining in regen. epid. |

Intensity of the staining: (−), no or negligible; (+), weak; (++), strong. Regen. epid: regenerating epidermis, BMZ: basement membrane zone.

blisters were similarly covered by new acanthotic epidermis. In our double-blind study, calcipotriol pretreatment (Fig. 1C) for 14 days did not alter the re-epithelialization rate on the fourth day in the open wounds compared with the vehicle-pretreated open wounds (Fig. 1B) in the same individuals. The regenerating epidermis in calcipotriol- and vehicle-pretreated skin did not differ in the gross appearance of epidermal cells and cellular differentiation.

### *BP180, BP230 and plectin/HD1*

In normal-appearing skin, immunoreactivity for BP180 was detected as a strong band-like pattern in the basement membrane zone (BMZ) and was often accompanied by weak pericellular/cytoplasmic positivity in the basal cell layer. Cytoplasmic/pericellular and band-like BMZ immunoreactivity for BP180 ranged from absent (Fig. 2A) to strong (Fig. 2B) at the leading edge of regenerating epidermis in 2- and 4-day-old blisters and open wounds. Behind the leading edge in the 4-day-old samples weak/strong band-like BMZ immunoreactivity was detected and accompanied by cytoplasmic/pericellular positivity in the basal cell layer(s) in most cases. BP180 remnants were often seen in 2-day-old blister roofs. In all but one case (Fig. 2C), plain (i.e. not yet re-epithelialized) wound bases were negative for BP180 in both wound types.

In normal-appearing skin, strong band-like immunoreactivity for BP230 was detected in the BMZ. The tips of the re-epithelialization fronts in the 2-day-old open wound samples showed no immunoreactivity (Fig. 2D) or weak cytoplasmic immunoreactivity for BP230. Behind the tip of the leading edge,

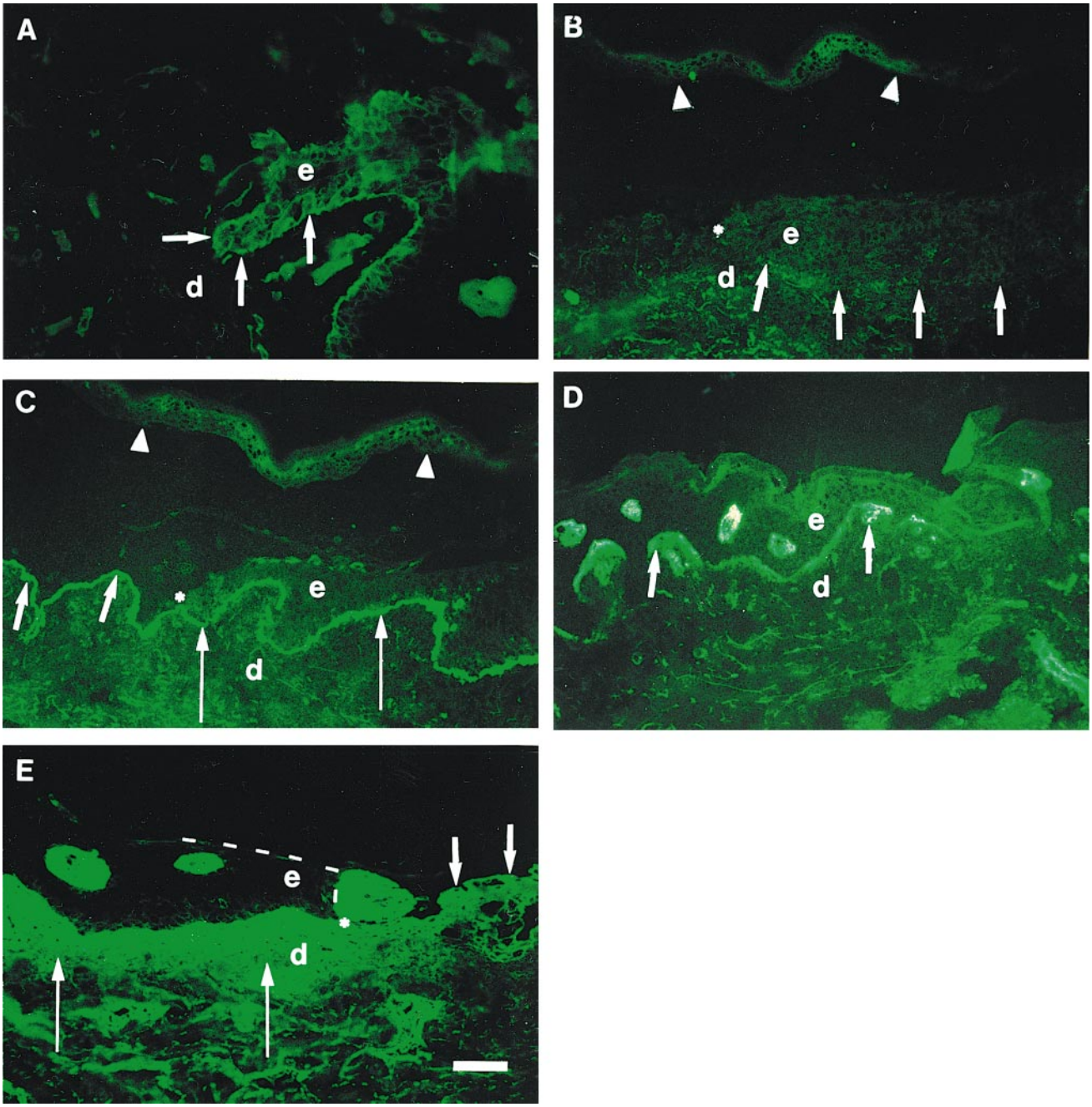


**Figure 3.** β4 and αvβ5 integrin, type VII collagen and tenascin-C in regenerating skin. (A) Band-like basement membrane zone immunoreactivity for β4 integrin at the leading edge (arrows) in a 2-day-old blister sample. Diffuse immunostaining in keratinocytes at the leading edge. (B) No or negligible immunoreactivity for the αvβ5 complex in the regenerating epidermis (arrows) in a 2-day-old blister sample (re-epithelialization from right to left in this figure). Blister roof (arrowheads). (C) Band-like immunoreactivity for type VII collagen in the blister floor (thick arrows) and under the regenerating epidermis (thin arrows). No immunoreactivity for type VII collagen in the blister roof (arrowheads). (D) Distinct immunoreactivity for tenascin-C in the upper dermis (arrows) in normal skin. Positivity in epidermal area is due to tangential sectioning along adjacent dermal papillae. (E) Strong immunoreactivity for tenascin-C in the blister base (thick arrows) and under the regenerating epidermis (thin arrows) (re-epithelialization from left to right in this figure). Faint cytoplasmic immunoreactivity in the lower epidermal cell layers in the migrating epidermal tongue. Broken line = upper pole of the regenerating epidermis. Positivity in epidermal area is due to tangential sectioning along adjacent dermal papillae. (B,C,E) Asterisk = tip of the leading edge; (A–E) d = dermis, e = epidermis. Scale bar (A) 22 μm; (B–E) 36 μm.

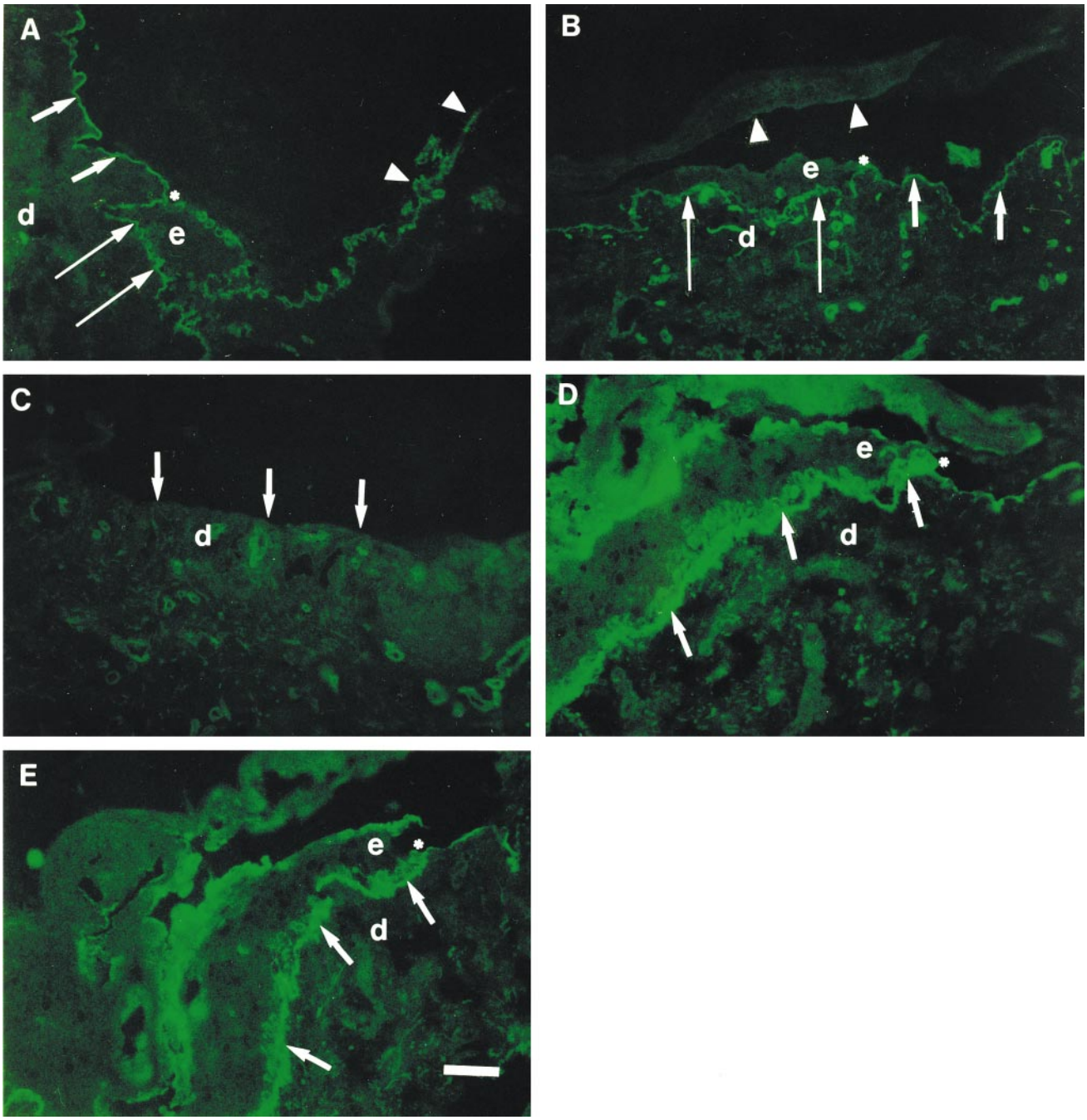


**Figure 4.** Laminin 5, laminin β1 chain and laminin α5 chain in regenerating skin. (A) Intact band-like immunoreactivity for laminin 5 in the blister floor (thick arrows) and under the regenerating epidermis (thin arrows) in a 2-day-old blister sample. Discontinuous positivity for laminin 5 in the blister roof (arrowheads). (B) Continuous band-like immunoreactivity for the laminin β1 chain in the blister floor (thick arrows) and under the regenerating epidermis (thin arrows) in a 2-day-old blister sample. No immunoreactivity for laminin β1 chain in the blister roof (arrowheads). (C) No immunoreactivity for laminin α5 chain in a 2-day-old open wound base (arrows). In calcipotriol-pretreated skin (D), the staining pattern for laminin 5 was similar to that in vehicle-pretreated skin (E), in 2-day-old open wound samples; note cytoplasmic and band-like basement membrane zone positivity at the leading front (arrows). (A,B,D,E) Asterisk = tip of the leading edge; (A–E) d = dermis; (A,B,D,E) e = epidermis. Scale bar (A–C) 36 μm; (D,E) 26 μm.

discontinuous weak or strong band-like positivity for BP230 was detected in the BMZ of regenerating epidermis, sometimes accompanied by weak cytoplasmic positivity in the basal cell layer. In contrast, the 2-day-old blister samples showed a stronger and more continuous band-like staining pattern in the regenerating skin, often accompanied by some cytoplasmic positivity (Fig. 2E). In 4-day-old open wounds (Fig. 2F) and blisters, weak to strong band-like immunoreactivity for BP230 was detected in the BMZ in the regenerating area.

In normal-appearing skin, strong band-like immunoreactivity for plectin/HD1 was detected in the BMZ. In some cases, weak pericellular/cytoplasmic positivity for plectin/HD1 was observed in the epidermal cell layers in both regenerating and normal skin. The leading edges of new epidermis in the 2-day-old open wounds were negative (Fig. 2G) or showed a very weak discontinuous band-like positivity in the BMZ. In contrast, the staining for plectin/HD1 in the 2-day-old blisters was stronger and more continuous in the BMZ of regenerating epidermis (Fig. 2H). The 4-day-old open wounds and blisters showed distinct band-like immunoreactivity for plectin/HD1 in the BMZ in regenerating epidermis. On the ninth day, the immunoreactivities for plectin/HD1, BP180 and BP230 were similar to those seen in normal skin.

### *β4, αvβ5, α5 and α9 integrins, type VII collagen and tenascin-C*

Weak/strong immunoreactivity for β4 integrin was detected at the leading edge in the basal cell layer and often also in the suprabasal cell layers in 2- and 4-day-old specimens (Fig. 3A). In addition, strong band-like reactivity for the β4 integrin was detected at the basal pole of basal keratinocytes at the leading edge in most 2-day-old samples and in all 4-day-old samples. The polarized immunostaining for β4 integrin was often discontinuous on the second day, but became continuous by the fourth day. On the ninth day, faint pericellular positivity was detectable in the suprabasal cell layers in contrast with the normal epidermis. The β4 integrin staining pattern was similar in intact blisters and open wounds. No or negligible immunoreactivity was detected for the αvβ5 complex (Fig. 3B), α5 integrin in regenerating and normal epidermis and for α9 integrin in regenerating epidermis. In some specimens, weak immunoreactivity was detected for α9 integrin in the basal cell layer in normal epidermis. In wounded skin, immunoreactivity for type VII collagen (Fig. 3C) corresponded fully with that in normal skin. Increased strong immunoreactivity was detected for tenascin-C from day 2 to day 9 in the upper dermis both under the regenerating/regenerated epidermis and in the plain wound bases in open wound and blister samples (Fig. 3D,E). In all but one 4-day-old sample, the plain wound bases showed equally as strong immunoreactivity as the upper dermis under the regenerating/regenerated epidermis. In most cases, faint cytoplasmic immunoreactivity for tenascin-C was detected in the lower epidermal cell layers in regenerating/regenerated epidermis (Fig. 3E).

### *Laminin 5, laminin α5 and laminin β1*

Strong continuous band-like immunoreactivity for laminin 5 (Fig. 4A), α5 and β1 (Fig. 4B) was detected in the plain blister floor in 2- and 4-day-old intact blisters. In open wound bases, the laminin 5, α5 and β1 immunostaining was partially discontinuous. In some open wound bases, there were also areas that completely lacked laminin 5, α5 (Fig. 4C) and β1 immunoreactivity. Under the regenerating epidermis, strong band-like BMZ immunoreactivity was detected for laminin 5 (Fig. 4E), α5 and β1 (Fig. 4B) in both wound types. No positivity was detected for laminin α5 or β1 (Fig. 4B) in epidermal cells at the leading front, while weak to strong cytoplasmic positivity was often detected for laminin 5 (Fig. 4E) at the leading front in both wound types. In contrast to laminin α5 and β1 (Fig. 4B), strong or weak reactivity for laminin 5 was often seen as a discontinuous linear or intracytoplasmic staining pattern in the blister roof in 2-day-old blisters (Fig. 4A).

Calcipotriol pretreatment did not alter the staining pattern for BP180, BP230, plectin/HD1, β4 integrin, tenascin-C or laminin 5 (Fig. 4D,E) in either regenerating or healthy areas. Staining for BP180, BP230 and plectin/HD1 in specimens from all sites showed similar levels of immunoreactivity.

## Discussion

Re-epithelialization was considerably slower in intact blisters than in roofless open wounds. This was unexpected, as it has been demonstrated that occluded wounds heal faster than non-occluded wounds.[26] The reasons for the slower re-epithelialization rate in intact blisters are not known, but may include intact laminin sheath in blister bases, contact inhibition by the pressure of the blister fluid, difference in protease or

cytokine expression or in interstitial fluid calcium concentration, accumulation of inhibitory compounds into the blister cavity and lack of inflammation in intact blisters. Calcipotriol pretreatment had no effect on the morphology of the regenerating epidermis, or on BP180, BP230, plectin/HD1, β4 integrin, laminin 5 or tenascin-C expression in either regenerating or normal epidermis. This was unexpected due to its potent effects in psoriasis and its antiproliferative effect in keratinocyte cultures.

Hemidesmosomal BP180 is thought to contribute to hemidesmosome assembly. Its extracellular domain extends to the lamina densa layer of the basement membrane. BP180 gene defects cause dermoepidermal cleavage in lamina lucida.[2,3,27,28] Notable inter-individual variation in BP180 expression was detected at the leading edge in 2- and 4-day-old samples regardless of the re-epithelialization rate and the wound type. This may suggest that, at the leading edge, BP180 is not directly involved in keratinocyte attachment to the wound bed. This would be in keeping with a recent study where the initial adhesion of BP180-deficient keratinocytes to extracellular matrix proteins, e.g. laminin 5 and fibronectin, was not substantially impaired.[29] In mucosal wounds, however, band-like BMZ positivity has been described beneath the entire length of the epithelial outgrowth.[30] BP180 was often found in blister roofs, but only once in a wound base. This is in line with an earlier suction blister study using bullous pemphigoid sera, and suggests that the basement membrane interactions of the extracellular domain are of lower affinity than the interactions of the cytoplasmic domain.[31]

BP230 and plectin/HD1 are located at the inner hemidesmosomal plaque and are involved in the linkage of the keratin cytoskeleton to the hemidesmosome. Plectin/HD1 gene mutations which cause tissue separation at the level of the inner hemidesmosomal plaque, and BP230 knockout mice which show skin blistering resulting from basal cell rupturing parallel to and just above the cell base, demonstrate the importance of these proteins in providing integrity within basal keratinocytes.[2,3,32] On the second day, BP230 and plectin/HD1 were better expressed at the leading edge in blisters than in open wounds. In view of the faster re-epithelialization rate in open wounds, it is interesting that a retardation of re-epithelialization was noted in BP230 knockout mice.[32] On the fourth day, band-like BMZ immunoreactivity both in blisters and in open wounds was detected for both plaque proteins at the leading edge, suggesting keratin cytoskeleton linkage to the basal plasma membrane of migrating basal cells. BP180, BP230 and plectin/HD1 expression showed no regional variation, and hence the results on these proteins apply to the whole body surface. This confirms that the decreased expression of BP230 and plectin/HD1 recently detected in uninvolved dermatitis herpetiformis skin is not due to regional variation, as the same antibody dilutions were used in both studies.[33]

The β4, αvβ5 and α5 integrins were studied because a difference in their expression between the two wound types could explain the retarded re-epithelialization rate in intact blisters, and α9 integrin because its role has not been studied previously in human wound healing. The expression of hemidesmosomal β4 integrin in open wounds and intact blisters was comparable with the β4 expression earlier reported in full-thickness skin wounds.[34] The α5 subunit of the fibronectin receptor α5β1 integrin has been shown to be upregulated in full-thickness wounds.[34] Using the same antibody, we detected negligible positivity for α5 in regenerating and normal epidermis in both wound types. This is in line with an earlier suction blister study, where weak positivity for α5, but no upregulation, was detected in the basal layer in both regenerating and normal epidermis.[35] The difference in the α5 staining intensity may be due to different affinities of the used antibodies. Our results suggest that β4 expression at the leading edge is independent of the composition of the wound bed, and that α5 is upregulated only upon contact with dermal structures *in vivo*. Our results for the vitronectin receptor αvβ5 confirm the earlier assumptions that only major dermal trauma upregulates αvβ5 in regenerating epidermis *in vivo*.[36–38] In contrast to the earlier studies using mouse tissues, the α9 subunit of tenascin-C binding α9β1 integrin was poorly expressed in normal epidermis and was not upregulated in healing skin.[39–41] Our results for type VII collagen suggest that, in contrast to blister healing in dermatitis herpetiformis, type VII collagen is not a target for degrading proteases during blister or open wound healing.[42] Tenascin-C is a large glycoprotein of the extracellular matrix and may have an antiadhesive effect.[43] During wound healing, tenascin-C has been shown to be upregulated beneath the regenerating epidermis.[44] In our study, the intensity and distribution of the increased tenascin-C immunostaining was the same both in plain open wound and plain blister bases and beneath the regenerating epidermis. This suggests that the keratinocyte-derived cytokines in suction blister fluid do not affect

tenascin-C synthesis in the upper dermis to a considerable extent, and that dermoepidermal cleavage leads to increased tenascin-C expression of dermal origin. The recently described tenascin-C synthesis by regenerating keratinocytes was limited in our samples to an extent which could not be distinguished by immunohistochemistry from the tenascin-C expression of dermal origin.[44]

The laminin antibodies used recognize all laminin isoforms currently thought to be located in the human cutaneous basement membrane, i.e. laminin 5 ($\alpha3\beta3\gamma2$), laminin 6 ($\alpha3\beta1\gamma1$), and laminin 10 ($\alpha5\beta1\gamma1$).[2,20,45] Our results for laminin 5 are parallel to an earlier suction blister study where laminin $\gamma2$ chain synthesis was shown at the leading edge.[46] However, no distinction between open wounds and intact blisters was done in that study. In contrast with laminin 5, we did not detect laminin $\alpha5$ or laminin $\beta1$ at the leading edge or in the blister roof. This suggests that laminin 10 and laminin 6 are not synthesized at the leading edge of either wound type. This also suggests that laminin 10 has greater affinity with the basement membrane than with its potential keratinocyte receptors, e.g. $\alpha3\beta1$ integrin,[47] and that laminin 6 has greater affinity with the basement membrane than with the laminin 5 subunit of the laminin 5–6 complex or, if the complex is not split during blister formation, that the laminin 5–6 complex has greater affinity with the basement membrane than with its keratinocyte receptors, $\alpha3\beta1$ and $\alpha6\beta4$ integrins.[2,5,48] Whether exogenous or endogenous laminin 5 promotes or inhibits keratinocyte migration has remained unclear.[49,50] In our study, the band-like immunostaining for laminin 5, laminin $\alpha5$ and $\beta1$ chains was always continuous in the blister bases while in the open wound bases it was partially discontinuous. The fragmentation could be due to the action of various proteases released from the inflammatory cells present in the wound base. It is possible that the intact laminin sheath may have inhibitory effects on the re-epithelialization rate.

## Acknowledgments

The skilful assistance of Ms Paula Hasenson, Ms Marja-Leena Piironen, Mr Reijo Karppinen and Mr Hannu Kamppinen is acknowledged. We thank Ms Outi Rauanheimo for secretarial assistance. The study was supported by funds from MATINE, the Research Institute of Military Medicine, Helsinki, Finland and the Oulu University Hospital.

## References

1 Martin P. Wound healing-aiming for perfect skin regeneration. *Science* 1997; **276**: 75–81.
2 Burgeson RE, Christiano AM. The dermal-epidermal junction. *Curr Opin Cell Biol* 1997; **9**: 651–8.
3 Jones JCR, Hopkinson SB, Goldfinger LE. Structure and assembly of hemidesmosomes. *BioEssays* 1998; **20**: 488–94.
4 Eble JA. Integrins—a versatile and old family of cell adhesion molecules. In: *Integrin–Ligand Interaction* (Eble JA, Kuhn K, eds). London: Chapman & Hall, 1997: 1–40.
5 Aumailley M, Krieg T. Laminins: a family of diverse multifunctional molecules of basement membranes. *J Invest Dermatol* 1996; **106**: 209–14.
6 Svendsen ML, Daneels G, Geysen J *et al.* Proliferation and differentiation of cultured human keratinocytes is modulated by 1,25(OH)2D3 and synthetic vitamin D3 analogues in a cell density-, calcium- and serum-dependent manner. *Pharmacol Toxicol* 1997; **80**: 49–56.
7 Koli K, Keski-Oja J. Vitamin D3 and calcipotriol enhance the secretion of transforming growth factor-beta 1 and -beta 2 in cultured murine keratinocytes. *Growth Factors* 1993; **8**: 153–63.
8 Nickoloff BJ, Mitra RS, Riser BL *et al.* Modulation of keratinocyte motility. Correlation with production of extracellular matrix molecules in response to growth promoting and antiproliferative factors. *Am J Pathol* 1988; **132**: 543–51.
9 Schmid P, Cox D, Bilbe G *et al.* TGF-betas and TGF-beta type II receptor in human epidermis: differential expression in acute and chronic skin wounds. *J Pathol* 1993; **171**: 191–7.
10 Yudoh K, Matsui H, Tsuji H. Effects of 1,25-dihydroxyvitamin D3 on tumor cell invasion to the extracellular matrix in human fibrosarcoma HT1080 cells and its correlation with laminin. *Tumor Biol* 1997; **18**: 69–79.
11 Kiistala U. Suction blister device for separation of viable epidermis from dermis. *J Invest Dermatol* 1968; **50**: 129–37.
12 Goldberg DJ, Sabolinski M, Bystryn J-C. Regional variation in the expression of bullous pemphigoid antigen and location of lesions in bullous pemphigoid. *J Invest Dermatol* 1984; **82**: 326–8.
13 Owaribe K, Nishizawa Y, Franke WW. Isolation and characterization of hemidesmosomes from bovine corneal epithelial cells. *Exp Cell Res* 1991; **192**: 22–30.
14 Hieda Y, Nishizawa Y, Uematsu J, Owaribe K. Identification of a new hemidesmosomal protein, HD1: a major, high molecular mass component of isolated hemidesmosomes. *J Cell Biol* 1992; **116**: 1497–506.
15 Gache Y, Chavanas S, Lacour JP *et al.* Defective expression of plectin/HD1 in epidermolysis bullosa simplex with muscular dystrophy. *J Clin Invest* 1996; **97**: 2289–98.
16 Tamura RN, Rozzo C, Starr L *et al.* Epithelial integrin $\alpha6\beta4$; complete primary structure of $\alpha6$ and variant forms of $\beta4$. *J Cell Biol* 1990; **111**: 1593–604.
17 Wayner EA, Orlando RA, Cheresh DA. Integrins $\alpha v\beta3$ and $\alpha v\beta5$ contribute to cell attachment to vitronectin but differentially distribute on the cell surface. *J Cell Biol* 1991; **113**: 919–29.
18 Werb Z, Tremble PM, Behrendtsen O *et al.* Signal transduction through the fibronectin receptor induces collagenase and stromelysin gene expression. *J Cell Biol* 1989; **109**: 877–9.
19 Wang A, Yokosaki Y, Ferrando R *et al.* Differential regulation of airway epithelial integrins by growth factors. *Am J Respir Cell Mol Biol* 1996; **15**: 664–72.
20 Tiger CF, Champliaud MF, Pedrosa-Domellof F *et al.* Presence of laminin $\alpha5$ chain and lack of laminin $\alpha1$ chain during human

muscle development and in muscular dystrophies. *J Biol Chem* 1997; **272**: 28590–5.
21 Virtanen I, Lohi J, Tani T *et al.* Distinct changes in the laminin composition of basement membranes in human seminiferous tubules during development and degeneration. *Am J Pathol* 1997; **150**: 1421–31.
22 Sakai LY, Keene DR, Morris NP, Burgeson RE. Type VII collagen is a major structural component of anchoring fibrils. *J Cell Biol* 1986; **103**: 1577–86.
23 Siri A, Carnemolla B, Saginati M *et al.* Human tenascin: primary structure, pre-mRNA splicing patterns and localization of the epitopes recognized by two monoclonal antibodies. *Nucleic Acids Res* 1991; **19**: 525–31.
24 Balza E, Siri A, Ponassi M *et al.* Production and characterization of monoclonal antibodies specific for different epitopes of human tenascin. *FEBS Lett* 1993; **332**: 39–43.
25 Rousselle P, Lunstrum GP, Keene DR, Burgeson RE. Kalinin: an epithelium-specific basement membrane adhesion molecule that is a component of anchoring filaments. *J Cell Biol* 1991; **114**: 567–76.
26 Nemeth AJ, Eaglstein WH, Taylor JR *et al.* Faster healing and less pain in skin biopsy sites treated with an occlusive dressing. *Arch Dermatol* 1991; **127**: 1679–83.
27 Masunaga T, Shimizu H, Yee C *et al.* The extracellular domain of BPAG2 localizes to anchoring filaments and its carboxyl terminus extends to the lamina densa of normal human epidermal basement membrane. *J Invest Dermatol* 1997; **109**: 200–6.
28 Yancey KB, Yee C. Localization of the extracellular domain of BPAG2 in human epidermal basement membrane. (Letter.) *J Invest Dermatol* 1998; **110**: 302.
29 Borradori L, Chavanas S, Schaapveld RQJ *et al.* Role of the bullous pemphigoid antigen 180 (BP180) in the assembly of hemidesmosomes and cell adhesion-reexpression of BP180 in generalized atrophic benign epidermolysis bullosa keratinocytes. *Exp Cell Res* 1998; **239**: 463–76.
30 Dabelsteen E, Gron B, Mandel U, Mackenzie I. Altered expression of epithelial cell surface glycoconjugates and intermediate filaments at the margins of mucosal wounds. *J Invest Dermatol* 1998; **111**: 592–7.
31 Woodley D, Sauder D, Talley MJ *et al.* Localization of basement membrane components after dermal-epidermal junction separation. *J Invest Dermatol* 1983; **81**: 149–53.
32 Guo L, Degenstein L, Dowling J *et al.* Gene targeting of BPAG1: abnormalities in mechanical strength and cell migration in stratified epithelia and neurologic degeneration. *Cell* 1995; **81**: 233–43.
33 Leivo T, Lohi J, Kariniemi A-L *et al.* Hemidesmosomal molecular changes in dermatitis herpetiformis; decreased expression of BP230 and plectin/HD1 in uninvolved skin. *Histochem J* 1999; **31**: 109–16.
34 Cavani A, Zambruno G, Marconi A *et al.* Distinctive integrin expression in the newly forming epidermis during wound healing in humans. *J Invest Dermatol* 1993; **101**: 600–4.
35 Hertle MD, Kubler M-D, Leigh IM, Watt FM. Aberrant integrin expression during epidermal wound healing and in psoriatic epidermis. *J Clin Invest* 1992; **89**: 1892–901.
36 Kim JP, Zhang K, Chen JD *et al.* Vitronectin-driven human keratinocyte locomotion is mediated by the αvβ5 integrin receptor. *J Biol Chem* 1994; **269**: 26926–32.
37 Clark RAF, Ashcroft GS, Spencer M-J *et al.* Re-epithelialization of normal human excisional wounds is associated with a switch from αvβ5 to αvβ6 integrins. *Br J Dermatol* 1996; **135**: 46–51.
38 Haapasalmi K, Zhang K, Tonnesen M *et al.* Keratinocytes in human wounds express αvβ6 integrin. *J Invest Dermatol* 1996; **106**: 42–8.
39 Stepp MA, Zhu L, Sheppard D, Cranfill RL. Localized distribution of α9 integrin in the cornea and changes in expression during corneal epithelial cell differentiation. *J Histochem Cytochem* 1995; **43**: 353–62.
40 Stepp MA, Zhu L. Upregulation of α9 integrin and tenascin during epithelial regeneration after debridement in the cornea. *J Histochem Cytochem* 1997; **45**: 189–202.
41 Yokosaki Y, Matsuura N, Higashiyama S *et al.* Identification of the ligand binding site for the integrin α9β1 in the third fibronectin type III repeat of tenascin-C. *J Biol Chem* 1998; **273**: 11423–8.
42 Airola K, Reunala T, Salo S, Saarialho-Kere U. Urokinase plasminogen activator is expressed by basal keratinocytes before interstitial collagenase, stromelysin-1, and laminin-5 in experimentally induced dermatitis herpetiformis lesions. *J Invest Dermatol* 1997; **108**: 7–11.
43 Vollmer G. Biologic and oncologic implications of tenascin-C/hexabrachion proteins. *Crit Rev Oncol Hematol* 1997; **25**: 187–210.
44 Latijnhouwers M, Bergers M, Ponec M *et al.* Human epidermal keratinocytes are a source of tenascin-C during wound healing. *J Invest Dermatol* 1997; **108**: 776–83.
45 Miner JH, Patton BL, Lentz SI *et al.* The laminin α chains: expression, developmental transitions, and chromosomal locations of α1–5, identification of heterotrimeric laminins 8–11, and cloning of a novel α3 isoform. *J Cell Biol* 1997; **137**: 685–701.
46 Kainulainen T, Häkkinen L, Hamidi S *et al.* Laminin-5 expression is independent of the injury and the microenvironment during reepithelialization of wounds. *J Histochem Cytochem* 1998; **46**: 353–60.
47 Kikkawa Y, Sanzen N, Sekiguchi K. Isolation and characterization of laminin-10/11 secreted by human lung carcinoma cells, laminin-10/11 mediates cell adhesion through integrin α3β1. *J Biol Chem* 1998; **273**: 15854–9.
48 Eble JA, Wucherpfennig KW, Gauthier L *et al.* Recombinant soluble human alpha 3 beta 1 integrin: purification, processing, regulation, and specific binding to laminin-5 and invasion in a mutually exclusive manner. *Biochem* 1998; **37**: 10945–55.
49 O'Toole EA, Marinkovich MP, Hoeffler WK *et al.* Laminin 5 inhibits human keratinocyte migration. *Exp Cell Res* 1997; **233**: 330–9.
50 Zhang K, Kramer RH. Laminin 5 deposition promotes keratinocyte motility. *Exp Cell Res* 1996; **227**: 309–22.