

Effect of candesartan cilexetil (TCV-116) in rats with chronic renal failure

MASAKUNI NODA, TAKANORI MATSUO, RYO FUKUDA, MASAYUKI OHTA, HIROKO NAGANO, YUMIKO SHIBOUTA, TAKEHIKO NAKA, KOHEI NISHIKAWA, and YOSHIMI IMURA

Pharmaceutical Research Laboratories II, Drug Safety Research Laboratories, and Research Management Department, Pharmaceutical Research Division, Takeda Chemical Industries, Ltd., Osaka, Japan

Effect of candesartan cilexetil (TCV-116) in rats with chronic renal failure.

Background. Inhibition of the renin-angiotensin system by both angiotensin II type 1 receptor antagonists (AT₁As) and angiotensin I-converting enzyme inhibitors (ACEIs) shows renoprotective effects in rats with chronic renal failure when treatment is started in the early phase of renal injury. In this study, we examined the renal protective effects of candesartan cilexetil (TCV-116), an AT₁A, and enalapril, an ACEI, in the progressive phase of renal injury in 5/6 nephrectomized rats.

Methods. Candesartan cilexetil (1 mg/kg/day) and enalapril (10 mg/kg/day) were orally administered once a day for 4 weeks (the short-term experiment) or 16 weeks (the long-term experiment) to 5/6 nephrectomized rats beginning 15 weeks after the nephrectomy, that is, after they had already showed marked proteinuria.

Results. In vehicle-treated rats, proteinuria, glomerulosclerosis, and interstitial fibrosis developed. Moreover, enhanced expression of transforming growth factor- β_1 (TGF- β_1) in the injured glomeruli was observed. These adverse changes progressed with time, and in the short-term experiment, both drugs inhibited them. In the long-term experiment, the progressive proteinuria and the elevation of blood pressure were similarly attenuated by both drugs. However, candesartan cilexetil significantly inhibited the progression of glomerulosclerosis, the expression of TGF- β_1 , and interstitial fibrosis, whereas enalapril did not.

Conclusion. These results indicate that candesartan cilexetil shows potent and long-term preventive effects against the progression of previously developed renal injury.

Glomerular capillary hypertension is associated with progressive renal failure [1]. Angiotensin II (Ang II), the primary effector product of the renin-angiotensin system (RAS), is thought to be a crucial factor in progres-

sive renal failure, as Ang II not only contributes to glomerular capillary hypertension, but also has a direct influence on some functions of the mesangial cells and the glomerular filtration barrier [2, 3]. In fact, inhibition of the RAS by Ang II type 1 receptor antagonists (AT₁As) or Ang I-converting enzyme inhibitors (ACEIs) has been shown to have renoprotective effects in animal models with renal diseases and in patients with chronic renal failure or diabetic nephropathy [4–11].

Both AT₁As and ACEIs ultimately block the RAS, but the mechanism of the RAS inhibition is different. Namely, AT₁As selectively inhibit the binding of Ang II to AT₁ receptors, resulting in increasing plasma Ang II and renin levels [12]. The increased Ang II may act on an Ang II type 2 (AT₂) receptor, a counter receptor for AT₁ receptors [13], and the activated AT₂ receptor is thought to contribute to the effects of AT₁As. In contrast, ACEIs inhibit Ang I-converting enzyme (ACE), which also degrades bradykinin (BK), resulting in elevating plasma renin levels and kinin activities, as well as decreasing plasma Ang II levels [14, 15]. BK is thought to contribute to the effects of ACEIs via nitric oxide, endothelium-derived hyperpolarizing factor, and eicosanoid production [16]. All of this evidence seems to indicate the existence of some differences between the pharmacological effects of AT₁As and ACEIs; however, it remains unclear which kind of RAS blocker has more beneficial effects in various diseases, including renal diseases.

Recent studies have raised some doubts as to the long-term efficacy of ACEIs, especially in post-treatment studies [17, 18]. Perico et al reported that in streptozotocin-induced diabetic rats, moexipril, an ACEI, completely prevented the progression of glomerulosclerosis when it was administered in the early phase of pathogenesis but that the compound did not prevent it when treatment was started during the progressive phase with marked proteinuria [17]. Verseput et al reported that in spontaneously hypertensive fawn-hooded rats, which

Key words: renoprotection, angiotensin II receptor antagonist, nephrectomy, progressive renal disease, injury, ACE inhibitor.

Received for publication June 16, 1998

and in revised form April 15, 1999

Accepted for publication April 24, 1999

© 1999 by the International Society of Nephrology

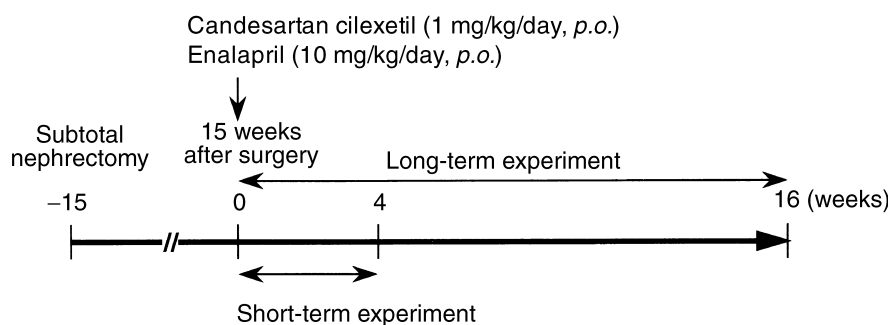


Fig. 1. Schematic presentation of the experimental protocol.

develop proteinuria and renal damage, early stage treatment with the ACEI lisinopril completely protected against glomerulosclerosis, whereas the compound did not prevent further development of glomerulosclerosis when it was administered in the progressive phase of glomerulosclerosis, despite fine control of both the systemic blood pressure and glomerular capillary pressure [18].

The 5/6 nephrectomized (5/6 NX) rat has commonly been used as a model to investigate the effects of drugs on pathophysiological events in the progression of glomerulosclerosis. These rats also show renal functional and structural changes similar to those observed in patients with end-stage kidney disease. This evidence prompted us to compare the renal protective effects of long-term treatment with candesartan cilexetil (TCV-116) [19–21], an AT₁A, and enalapril, an ACEI, in the progressive phase of renal injury in 5/6 NX rats. To evaluate the effect of post-treatment, these drugs were administered to the rats 15 weeks after the nephrectomy, that is, after they had already developed renal damage.

METHODS

Experimental design

Male five-week-old Sprague-Dawley rats, purchased from Japan Clea Laboratory (Tokyo, Japan), were subjected to a 5/6 renal NX, consisting of the surgical excision of approximately 2/3 of the renal cortex of the right kidney. One week later, the left kidney was removed. As shown in Figure 1, drugs were administered once a day in the morning beginning 15 weeks after the nephrectomy, and the effects of drugs on the 4-week administration (the short-term experiment) and the 16-week administration (the long-term experiment) were evaluated. The short-term experiment consisted of the following four groups: vehicle-treated ($N = 5$), candesartan cilexetil-treated (1 mg/kg, p.o., $N = 5$), and enalapril-treated (10 mg/kg, p.o., $N = 5$) 5/6 NX rats, as well as sham-operated normal two-kidney rats ($N = 3$). The long-term experiment consisted of following four groups: vehicle-treated ($N = 7$), candesartan cilexetil-treated (1 mg/kg,

p.o., $N = 7$), and enalapril-treated (10 mg/kg, p.o., $N = 7$) 5/6 NX rats, as well as sham-operated normal two-kidney rats ($N = 5$). At the onset of the both experiments, NX rats were divided into three groups with equivalence of the values of urinary albumin excretion, urinary protein excretion, creatinine clearance (C_{Cr}), and blood pressure to ensure equal severity of lesions in the remnant kidney. A one-way analysis of variance was used to confirm the equal initial values of the previously mentioned four parameters in the both experiments. At the onset of intervention in the short-term experiment, urinary total protein was 86.6 ± 9.8 , 89.4 ± 11.1 , and 88.6 ± 9.4 mg/day ($P = 0.981$). Urinary albumin was 38.3 ± 8.3 , 39.0 ± 9.1 , and 38.4 ± 8.2 mg/day ($P = 0.998$). C_{Cr} was 0.25 ± 0.02 , 0.24 ± 0.02 , and 0.26 ± 0.03 ml/min/100 g body wt ($P = 0.803$). Blood pressure was 145.4 ± 4.5 , 143.6 ± 3.5 , and 144.2 ± 6.0 mm Hg ($P = 0.964$) in the vehicle-treated, candesartan cilexetil-treated, and enalapril-treated groups, respectively. At the onset of the intervention in the long-term experiment, urinary total protein was 89.3 ± 9.7 , 85.9 ± 11.6 , and 89.8 ± 15.5 mg/day ($P = 0.971$). Urinary albumin was 39.0 ± 8.1 , 39.3 ± 7.1 , and 39.0 ± 9.5 mg/day ($P = 0.999$). C_{Cr} was 0.23 ± 0.01 , 0.24 ± 0.02 , and 0.23 ± 0.01 ml/min/100 g body wt ($P = 0.998$). Blood pressure was 149.9 ± 2.7 , 145.0 ± 4.1 , and 143.0 ± 4.4 mm Hg ($P = 0.444$) in vehicle-treated, candesartan cilexetil-treated, and enalapril-treated group, respectively. The doses of candesartan cilexetil and enalapril (1 and 10 mg/kg, respectively) used in the experiments were chosen because they have been shown to provide equivalent hypotensive effects in spontaneously hypertensive rats [22]. At the end of both experiments, rats were anesthetized with sodium pentobarbital (50 mg/kg, intraperitoneally), and a terminal blood sample was collected from the abdominal aorta. Then remnant kidneys of the 5/6 NX rats and the right kidneys of the sham-operated rats were removed and fixed in 10% neutral-buffered formalin for routine histological studies or were frozen for immunohistochemical studies. All animal experiments were performed according to the guidelines of the Takeda Experimental Animal Care and Use Committee.

Measurement of blood pressure

Systolic blood pressure was measured five hours after the morning dose. Rats were maintained in individual chambers warmed at 37°C, and systolic blood pressure was measured using a tail-cuff (PS-8000; Riken Kaihatsu, Tokyo, Japan).

Measurements of serum and urine parameters

Twenty-four-hour urine samples were collected with the aid of metabolic cages. Blood was collected from conscious rats via a tail vein using ethylenediaminetetraacetic acid (EDTA) as an anticoagulant, and the plasma was stored below -20°C. Urinary total protein, urinary albumin, urinary and plasma creatinine, and blood urea nitrogen (BUN) were measured by conventional methods, using commercially available kits (Wako Pure Chemicals, Osaka, Japan). Plasma renin activity (PRA) was estimated as the activity of Ang I production from endogenous angiotensinogen using a radioimmunoassay kit (SRL, Tokyo, Japan). Urinary prostaglandin E₂ (PGE₂) was extracted from 24-hour urine samples according to the method of Powell [23]. In brief, the urine was acidified to pH 3 with 1 N HCl and was passed through Sep-pak light C18 cartridges (Millipore, Bedford, MA, USA), and PGE₂ was eluted with ethanol/water (15:85). The amount of the extracted PGE₂ was measured using an enzyme immunoassay kit (Amersham, Tokyo, Japan). In the long-term experiment, hematocrit values were measured at the end of the 16-week administration period.

Histological studies

The kidneys were fixed in 10% neutral-buffered formalin and were embedded in paraffin. Sections of 4 μm in thickness were stained with hematoxylin and eosin (H&E), periodic acid-methenamine silver (PAM), and Azan for the evaluation of glomerulosclerosis and tubulointerstitial lesions. For each rat, all glomerular cross-sections present in a specimen were evaluated, and the percentage of glomeruli exhibiting focal or global glomerulosclerosis was determined. Glomerulosclerosis was evidenced by segmental increases in the glomerular matrix, segmental collapse of capillary lumina, and/or adhesion to Bowman's capsule. Tubulointerstitial lesions were defined as mononuclear cell infiltration and interstitial fibrosis. Lesions were assessed using the following scale: 0 = normal, 1 = small focal lesion, 2 = multifocal lesion, 3 = diffuse lesion, and 4 = extensive lesion involving the entire cortex. To examine the expression of transforming growth factor-β₁ (TGF-β₁) in glomeruli, an immunohistochemical study was performed. Sections of fresh frozen tissue (12 μm thick) were incubated with a mouse monoclonal antibody against human TGF-β₁ (Antigenix America Inc., New York, NY, USA) and

were processed by the indirect immunoperoxidase technique. The number of glomeruli showing positive staining was expressed as a percentage of the total number of glomeruli present in a specimen. A negative control value was obtained by replacing the primary antibody with phosphate-buffered saline.

Drugs

Candesartan cilexetil (TCV-116), (±)-1-(cyclohexyloxy-carbonyloxy) ethyl 2-ethoxy-1-[[2'-(1*H*-tetrazol-5-yl) biphenyl-4-yl] methyl]-1*H*-benzimidazole-7-carboxylate, and enalapril maleate were synthesized by Takeda Chemical Industries, Ltd. (Osaka, Japan).

Statistical analysis

Data are expressed as mean ± SE. Differences between the vehicle-treated group and the sham-operated group in values of urinary albumin excretion, total protein excretion, systolic blood pressure, C_{Cr}, plasma creatinine, BUN, hematocrit, body weight, and kidney wet weight were analyzed by Student's *t*-test. Differences between the vehicle-treated group and the drug-treated groups for all parameters were analyzed by Dunnett's test. Because the variance homogeneity criterion of the parametric test was not fulfilled in all data, the logarithm scale transformation was applied to homogenize variances where necessary, and the transformed data were used in the analysis. A *P* < 0.05 was considered to indicate a significant difference.

RESULTS

Proteinuria

Figure 2 shows urinary total protein excretion (Fig. 2A) and urinary albumin excretion (Fig. 2B) in both the short- and long-term experiments. Urinary total protein and urinary albumin excretion in the vehicle-treated rats increased with time, and the severity of the proteinuria began to increase sharply eight weeks after the first dose in the long-term experiment. Candesartan cilexetil and enalapril significantly prevented the progression of proteinuria in both experiments, and the effects of the two compounds were comparable.

Blood pressure

The 5/6 nephrectomy resulted in the development of systemic hypertension (Fig. 3). In the short-term experiment, candesartan cilexetil tended to show a hypotensive effect, and enalapril significantly decreased the systolic blood pressure (124.3 ± 2.2, 149.4 ± 4.0, 140.4 ± 4.7, and 129.0 ± 4.8 mm Hg for sham operated, vehicle, candesartan cilexetil, and enalapril, respectively). In the long-term experiment, both candesartan cilexetil and enalapril showed significant and comparable antihypertensive effects at the end of the 16-week administration

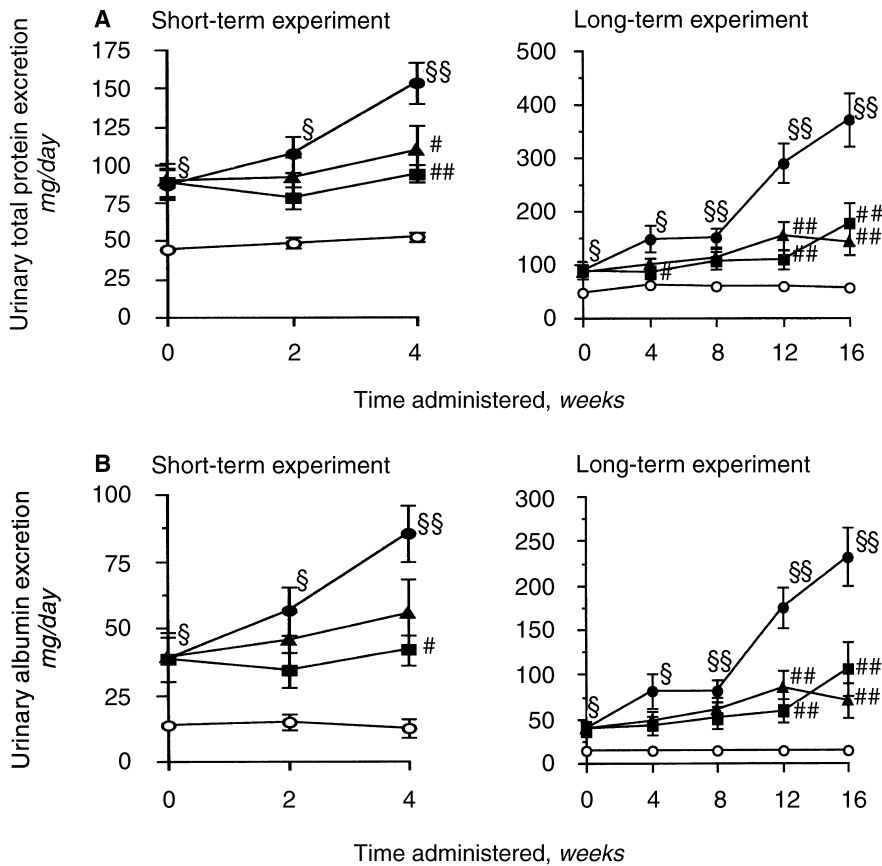


Fig. 2. Effects of candesartan cilexetil and enalapril on urinary total protein (A) and albumin (B) excretion in 5/6 nephrectomized rats. Symbols are: (●) vehicle; (▲) candesartan cilexetil 1 mg/kg; (■) enalapril 10 mg/kg; (○) sham operated; §*P* < 0.05, §§*P* < 0.01 vs. sham-operated rats (sham operated) with Student's *t*-test; #*P* < 0.05, ##*P* < 0.01 vs. vehicle-treated rats (vehicle) with Dunnett's test. Data are presented as mean ± se.

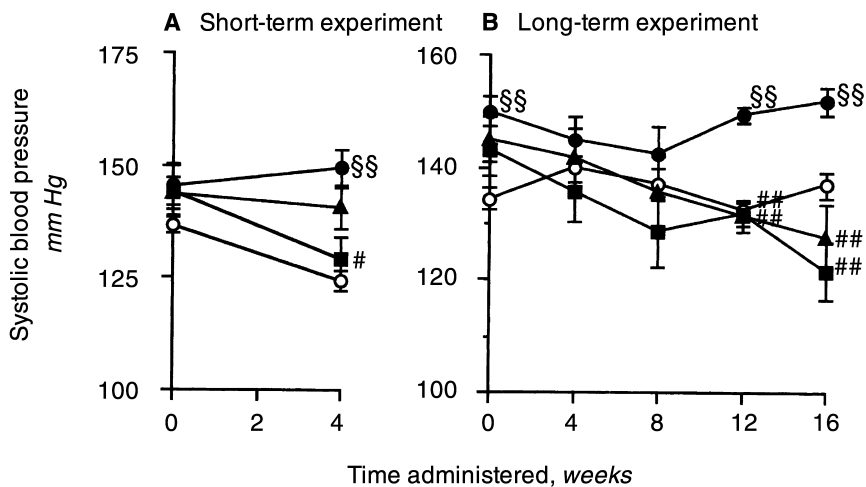


Fig. 3. Effects of candesartan cilexetil and enalapril on systolic blood pressure in 5/6 nephrectomized rats. Symbols are: (●) vehicle; (▲) candesartan cilexetil 1 mg/kg; (■) enalapril 10 mg/kg; (○) sham operated; §§*P* < 0.01 vs. sham-operated rats (sham operated) with Student's *t*-test; #*P* < 0.05, ##*P* < 0.01 vs. vehicle-treated rats (vehicle) with Dunnett's test. Data are presented as mean ± se.

period (137.0 ± 2.3 , 151.9 ± 2.6 , 127.7 ± 5.9 , and 121.6 ± 5.1 mm Hg for sham operated, vehicle, candesartan cilexetil and enalapril, respectively).

Histological findings

Table 1 shows the histological findings in the short-term experiment. In the vehicle-treated rats, the number

of glomeruli with sclerotic lesions markedly increased, and interstitial fibrosis and mononuclear cell infiltration were also observed. Both candesartan cilexetil and enalapril inhibited the progression of glomerulosclerosis and tended to prevent the interstitial fibrosis and mononuclear cell infiltration.

Figures 4 and 5 show representative histological sec-

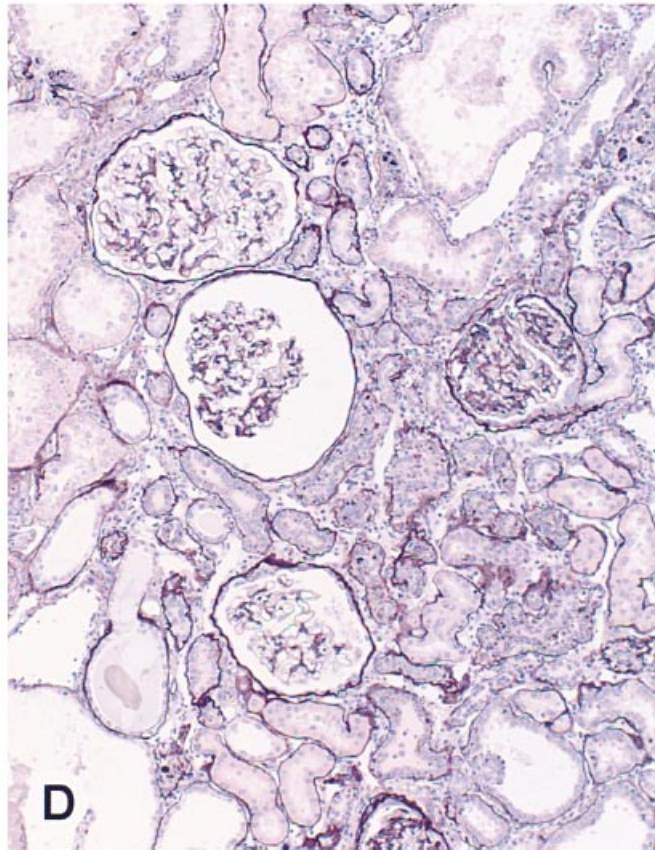
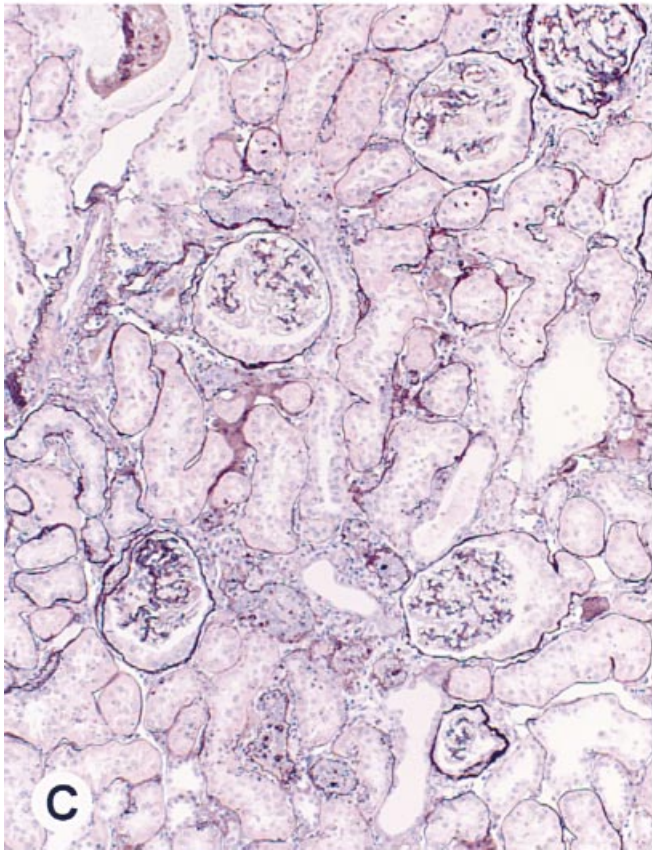
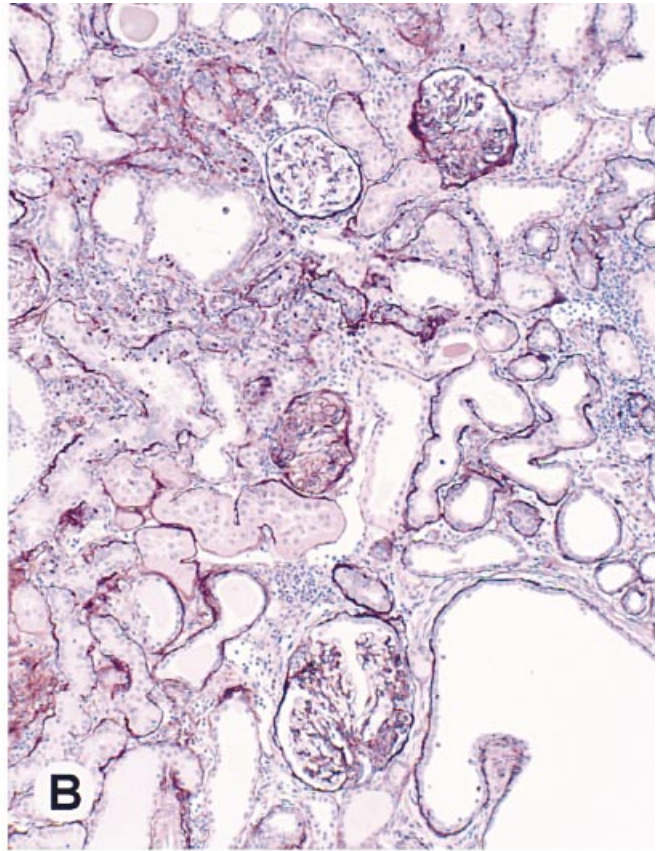
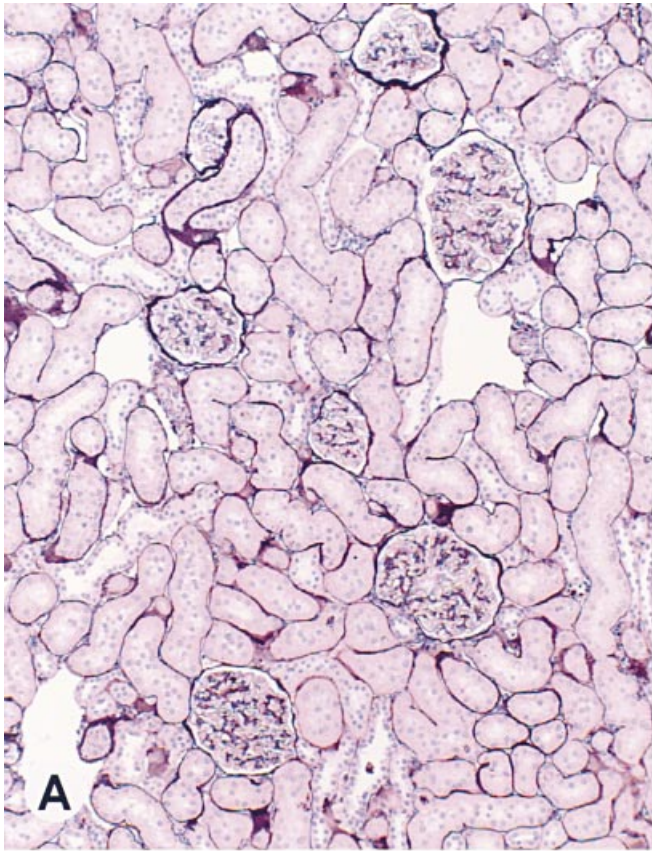


Fig. 4. Effects of candesartan cilexetil and enalapril on the glomerulosclerosis in 5/6 nephrectomized rats in the long-term experiment. Photomicrographs of periodic acid-methenamine silver-stained preparations (magnification $\times 105$) show glomeruli from a sham-operated rat (A), a vehicle-treated rat (B), a candesartan cilexetil (1 mg/kg/day, p.o.)-treated rat (C), and an enalapril (10 mg/kg/day, p.o.)-treated rat (D).

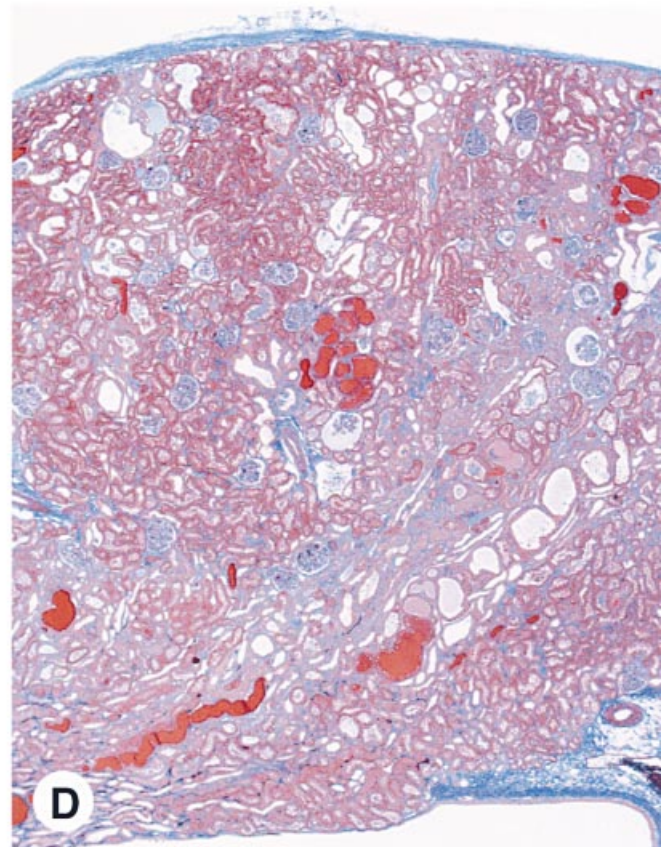
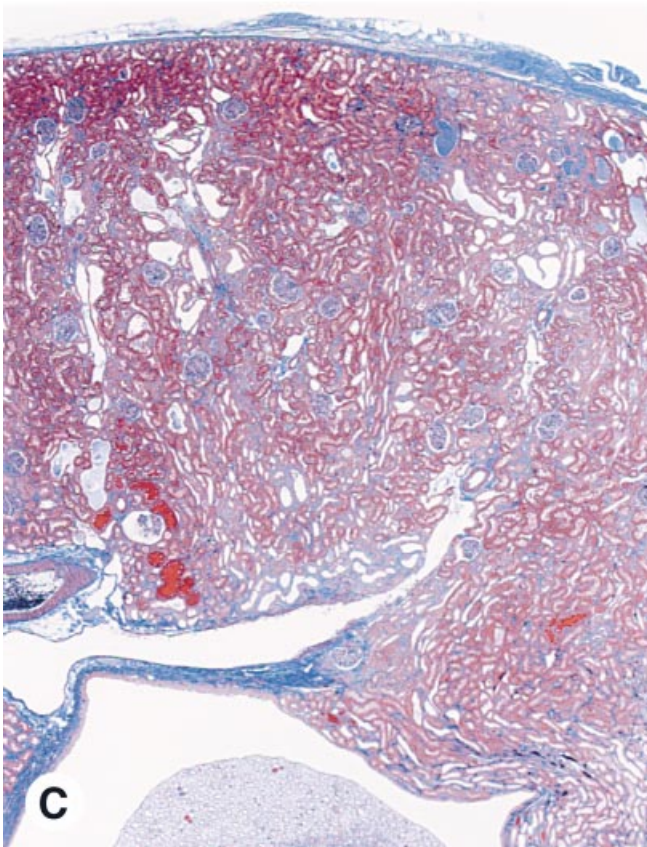
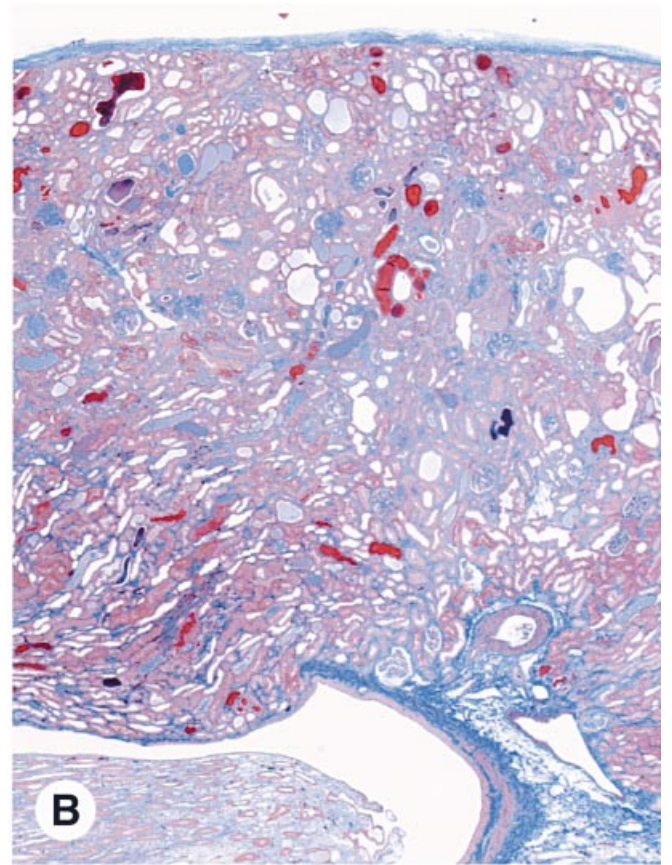
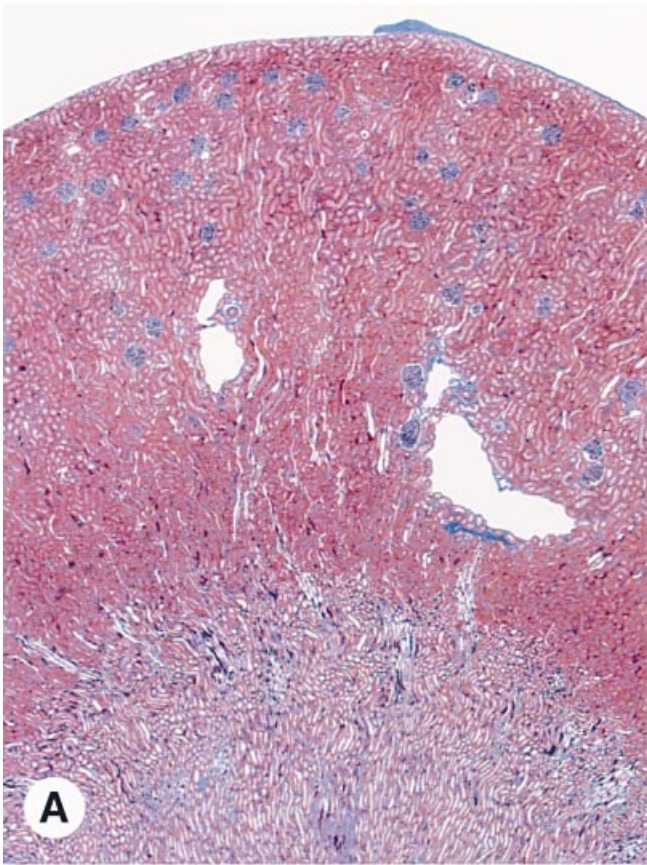


Fig. 5. Effects of candesartan cilexetil and enalapril on the interstitial fibrosis in 5/6 nephrectomized rats in the long-term experiment. Microphotographs of AZAN-stained preparations (magnification $\times 21$) show glomerular and tubulointerstitial regions from a sham-operated rat (A), a vehicle-treated rat (B), a candesartan cilexetil (1 mg/kg/day, p.o.)-treated rat (C), and an enalapril (10 mg/kg/day, p.o.)-treated rat (D).

Table 1. Effects of candesartan cilexetil and enalapril on renal injury in 5/6 nephrectomized rats at the end of the short-term experiment

	Sham op.	Vehicle	Candesartan cilexetil	Enalapril
Glomerulosclerosis %	0.8 ± 0.3	25.5 ± 4.4	12.3 ± 3.1 ^a	8.7 ± 2.7 ^b
TGF-β ₁ expression %	0.0 ± 0.0	25.3 ± 5.0	7.9 ± 4.2 ^a	2.2 ± 0.6 ^b
Interstitial fibrosis (score)	0.0 ± 0.0	2.6 ± 0.2	1.6 ± 0.4	1.8 ± 0.4
MNC interstitial infiltration (score)	0.0 ± 0.0	2.4 ± 0.4	2.0 ± 0.3	2.0 ± 0.3

Data are presented as mean ± SE. Abbreviations are: op., operated; TGF-β₁, transforming growth factor-beta₁; MNC, mononuclear cell.

^aP < 0.05, ^bP < 0.01 vs. vehicle-treated rats (vehicle) with Dunnett's test

tions of glomeruli and interstitial areas, respectively, in the long-term experiment. Prominent glomerulosclerosis (Fig. 4) and severe interstitial fibrosis (Fig. 5) were observed in the vehicle-treated rats. ED1-positive inflammatory cells (macrophages) were also observed in both the glomeruli and interstitial areas (data not shown). Figure 6 shows the quantitative analysis of these histological findings. Candesartan cilexetil significantly inhibited the progression of the glomerulosclerosis (1.0 ± 0.4, 25.9 ± 4.4, 9.7 ± 3.2, and 15.2 ± 4.6% for sham operated, vehicle, candesartan cilexetil, and enalapril-treated groups, respectively; Fig. 6A) and interstitial fibrosis (0.0 ± 0.0, 3.3 ± 0.2, 1.9 ± 0.3, and 2.6 ± 0.2 score for sham operated, vehicle, candesartan cilexetil, and enalapril-treated groups, respectively; Fig. 6B), whereas enalapril did not show significant preventive effects. Both drugs inhibited the mononuclear cell infiltration comparatively (0.0 ± 0.0, 3.6 ± 0.2, 2.1 ± 0.3, and 2.1 ± 0.3 score for sham operated, vehicle-treated, candesartan cilexetil-treated, and enalapril-treated groups, respectively; Fig. 7). Immunoreactive TGF-β₁ was expressed in the glomeruli of the vehicle-treated rats, and the area of expression was comparable to the location of sclerotic lesions (Fig. 8). TGF-β₁ expression could not be detected in the interstitium. Figure 9 shows the quantitative analysis of the glomerular TGF-β₁ expression in both short- and long-term experiments. The number of glomeruli showing TGF-β₁ expression in the vehicle-treated rats increased with time. Candesartan cilexetil and enalapril significantly inhibited the expression of TGF-β₁ in the glomeruli in the short-term experiment (0.0 ± 0.0, 25.3 ± 5.0, 7.9 ± 4.2, and 2.2 ± 0.6% for sham operated, vehicle-treated, candesartan cilexetil-treated, and enalapril-treated groups, respectively). In the long-term experiment, candesartan cilexetil markedly prevented the increase in the expression of TGF-β₁, whereas the preventive effect of enalapril decreased as compared with that in the short-term experiment, and a significant effect was not observed in the enalapril-treated rats (3.9 ± 1.9, 37.4 ± 6.4, 10.4 ± 2.1, and 23.7 ± 8.7% for sham operated, vehicle-treated, candesartan cilexetil-treated, and enalapril-treated groups, respectively).

Urinary prostaglandin E₂ excretion

As shown in Figure 10, urinary PGE₂ excretion in the enalapril-treated 5/6 NX rats was markedly increased at the end of the 16-week administration period.

Renal physiological parameters

Creatinine clearance, plasma creatinine, BUN, kidney weight, and body weight at the end of the short-term experiment, and hematocrit in addition to these parameters at the end of the long-term experiment were shown in Table 2. In vehicle-treated groups, a significant increase in plasma creatinine and BUN levels were observed in the short-term experiment. Both drugs had no effect on these renal physiological parameters. At the end of the long-term experiment, a significant decrease in C_{Cr} and an increase in plasma creatinine and BUN in the vehicle-treated group were observed. Neither drug inhibited these adverse changes significantly. The hematocrit value in the vehicle-treated rats decreased as compared with that in the sham-operated rats and was not affected by either drug at the end of long-term experiment. The wet weight of the remnant kidney in the vehicle-treated rats was higher than that of the normal right kidney in the sham-operated rats. Neither drug had any effect on kidney weight in both of the experiments. Figure 11 shows PRA in the short-term experiments. PRA in the vehicle-treated rats showed a significant decrease as compared with the value in the sham-operated rats. PRA in the candesartan cilexetil- and enalapril-treated rats was increased significantly as compared with that in the vehicle-treated rats.

DISCUSSION

The aim of this study was to compare the renal protective effects of candesartan cilexetil, an AT₁A, and enalapril, an ACEI, on 4-week (short-term) and 16-week (long-term) administration during the progressive phase of renal injury in 5/6 NX rats. Drugs were administered to 5/6 NX rats starting 15 weeks after the nephrectomy. In the short-term experiment, candesartan cilexetil and enalapril showed marked renal protective effects. Both drugs suppressed proteinuria and glomerulosclerosis (Fig. 2 and Table 1). These results coincided with the

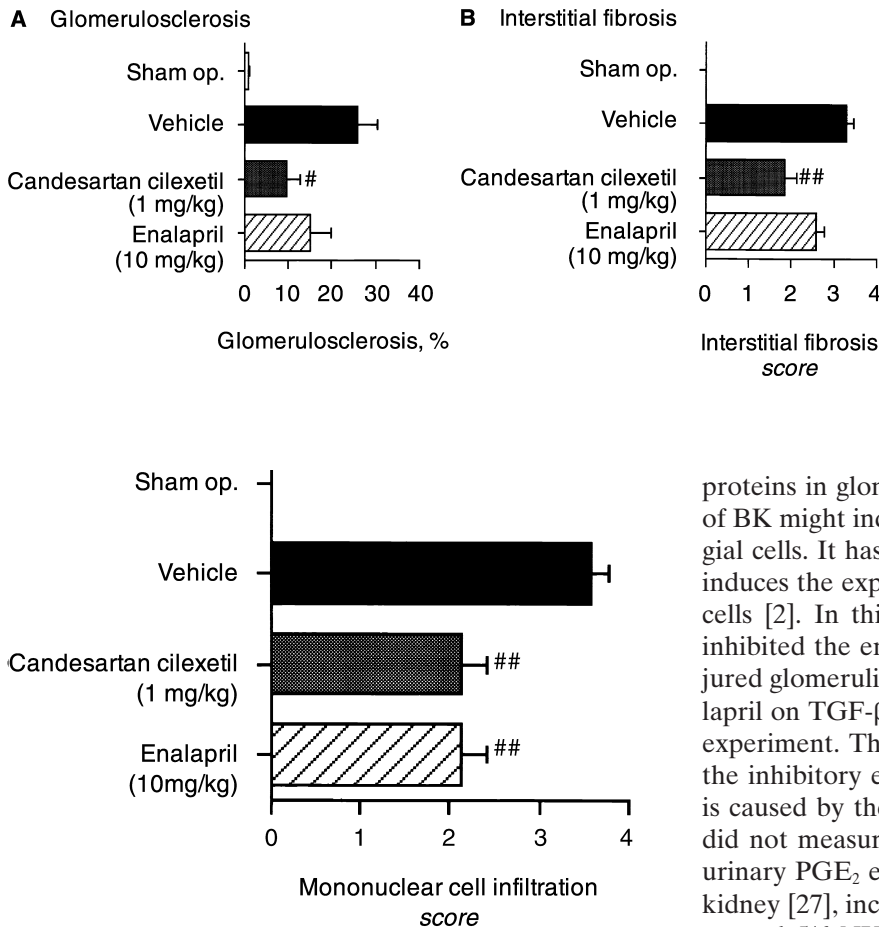


Fig. 6. Quantitative analysis of the effects of candesartan cilexetil and enalapril on the glomerulosclerosis (A) and the interstitial fibrosis (B) in 5/6 nephrectomized rats in the long-term experiment. [#] $P < 0.05$; ^{##} $P < 0.01$ vs. vehicle-treated rats (vehicle) with Dunnett's test. Data are presented as mean \pm SE.

Fig. 7. Effects of candesartan cilexetil and enalapril on the interstitial mononuclear cell infiltration in 5/6 nephrectomized rats in the long term experiment. ^{##} $P < 0.01$ vs. vehicle-treated rats (vehicle) with Dunnett's test. Data are presented as mean \pm SE.

results of many previous studies designed to examine the renoprotective effects of earlier treatment with AT₁As and ACEIs in 5/6 NX rats [4–9, 24]. In the long-term experiment, candesartan cilexetil significantly ameliorated the progression of glomerulosclerosis, the glomerular expression of immunoreactive TGF- β_1 , and interstitial fibrosis, but enalapril did not, although both drugs showed the same hypotensive and antiproteinuric effects. The differences between candesartan cilexetil and enalapril with regard to renal protective effects may be explained as follows.

First, the inhibition of ACE, namely, kininase II, by an ACEI results in the accumulation of BK [15]. As BK stimulates the proliferation of cultured rat mesangial cells [25], and as the proliferation of mesangial cells plays an important role in the progression of glomerulosclerosis, this effect of BK might counteract the renal protective effects of ACEIs. BK also activates AP-1 [25], one of the major transcriptional factors of TGF- β_1 , which plays a pivotal role in the accumulation of extracellular matrix

proteins in glomeruli [26]. Therefore, the accumulation of BK might induce the expression of TGF- β_1 in mesangial cells. It has also been reported that Ang II directly induces the expression of TGF- β_1 in cultured mesangial cells [2]. In this study, candesartan cilexetil markedly inhibited the enhanced expression of TGF- β_1 in the injured glomeruli. However, the suppressive effect of enalapril on TGF- β_1 expression decreased in the long-term experiment. These results suggest that the weakness of the inhibitory effect of enalapril on TGF- β_1 expression is caused by the accumulation of BK. In this study, we did not measure the content of BK in the kidney, but urinary PGE₂ excretion, which is induced by BK in the kidney [27], increased significantly in only the enalapril-treated 5/6 NX rats in the long-term experiment (Fig. 10), suggesting the accumulation of BK in the kidney. The level of urinary PGE₂ excretion in vehicle-treated group was lower than that of the sham-operated group. It is conceivable that this reduction might be caused by the decrease in PGE₂-producing cells of the remnant kidney because of both the initial renal ablation and the progression of injuries. Enalapril markedly increased the urinary PGE₂ excretion compared with vehicle; therefore, the elevation of the PGE₂ excretion by enalapril might be caused in part by the accumulation of BK. Because glomerular capillary hypertension induces glomerular dysfunction, the amelioration of glomerular capillary hypertension via a reduction of efferent arteriolar tone is thought to prevent the development of glomerular injury [4–7]. It has been reported that the antagonism of Ang II with an AT₁A causes less reduction in the glomerular efferent arteriolar tone than the inhibition of ACE with an ACEI, because the accumulated BK causes efferent arteriole dilation [28, 29]. This suggests that BK contributes to the renoprotective effects of ACEIs; however, in our study, enalapril did not show any advantage over candesartan cilexetil.

Second, an AT₁A can completely inhibit Ang II's effects at the level of AT₁ receptors, whereas enalapril cannot inhibit the effect of Ang II produced by proteases

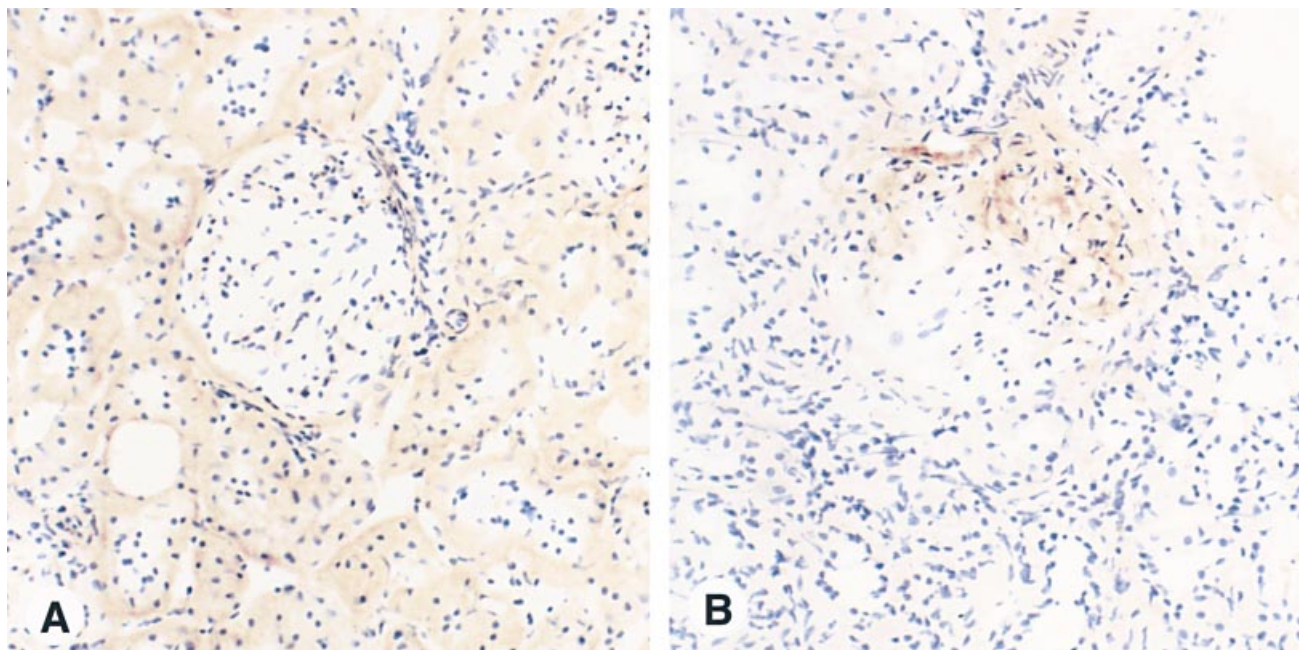


Fig. 8. Expression of immunoreactive transforming growth factor- β_1 (TGF- β_1) in a glomerulus from a sham-operated rat (A) and a 5/6 nephrectomized rat (B) at the end of the long-term experiment (magnification $\times 210$).

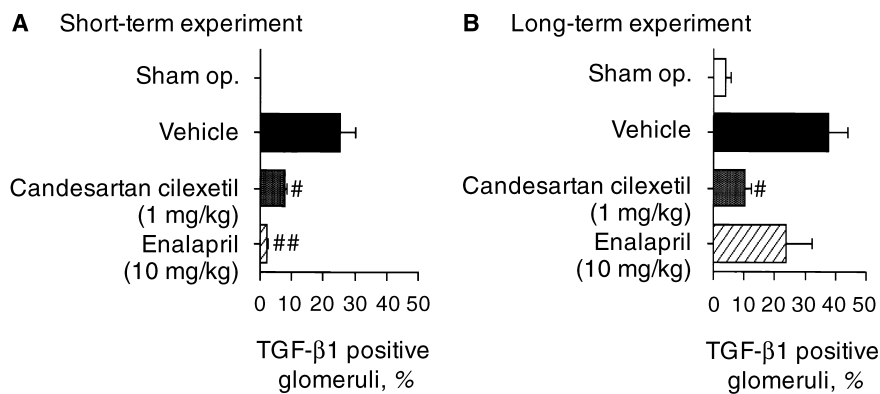


Fig. 9. Quantitative analysis of the effects of candesartan cilexetil and enalapril on the glomerular expression of transforming growth factor- β_1 (TGF- β_1) in 5/6 nephrectomized rats in the (A) short- and (B) long-term experiments. [#] $P < 0.05$; ^{##} $P < 0.01$ vs. vehicle-treated rats (vehicle) with Dunnett's test. Data are presented as mean \pm SE.

other than ACE. In some organs, ACE-independent Ang I conversion is predominant in the generation of Ang II [30, 31]. Urata, Strobel, and Ganten reported that chymase, an ACEI-insensitive Ang II-forming protease, exists in the human renal cortex [32]. In the rat kidney, some Ang II-forming pathways other than that involving ACE exist, and these may have contributed to the failure of the renoprotective effects of enalapril in the long-term experiment. For instance, cathepsin G contained in infiltrating monocytes can generate Ang II from angiotensinogen directly [33].

Third, AT₁As are reported to activate AT₂ receptors via the elevation of plasma Ang II [16]. As AT₂ receptors mediate antiproliferative and antifibrotic effects, AT₁ and AT₂ receptors might mediate counterbalancing sig-

nals [13]. Because AT₂ receptors exist in the kidney of adult rats [34], activation of AT₂ receptors might have contributed to the beneficial renal protective effects of candesartan cilexetil, especially in the long-term experiment. According to a recent report, however, indirect AT₂ receptor activation stimulates the glomerular infiltration of monocytes/macrophages via RANTES expression, resulting in the progression of renal injury [35]. However, in this study, AT₂ receptor activation did not seem to be an important factor for the infiltration of inflammatory cells because candesartan cilexetil and enalapril caused comparable inhibition of interstitial mononuclear cell infiltration.

It has been established that the augmented production of TGF- β_1 is important in the progression of interstitial

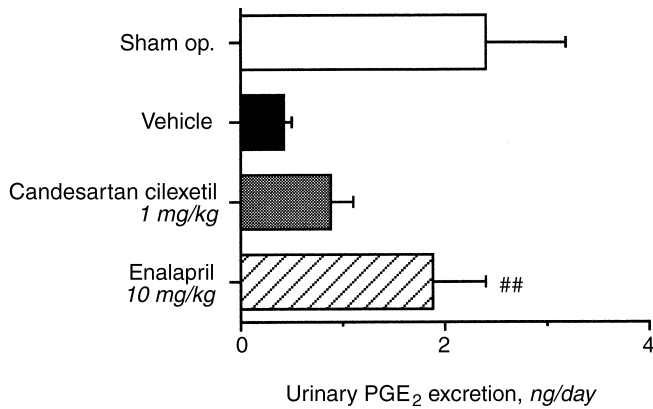


Fig. 10. Effects of candesartan cilexetil and enalapril on urinary prostaglandin E₂ (PGE₂) excretion in 5/6 nephrectomized rats in the long-term experiment. ^{##}*P* < 0.01 vs. vehicle-treated rats (vehicle) with Dunnett's test. Data are presented as mean ± SE.

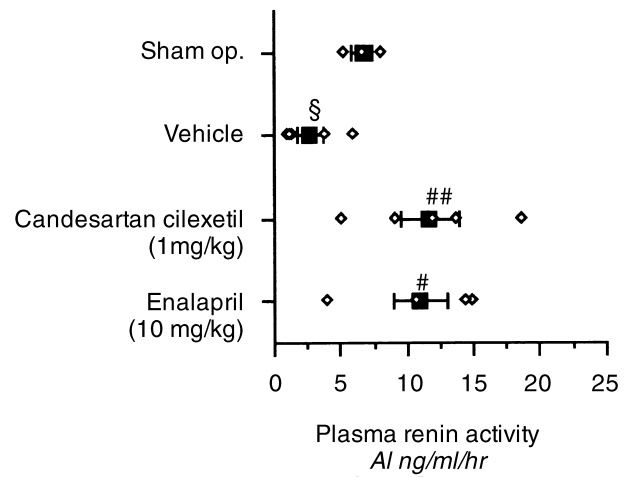


Fig. 11. Effects of candesartan cilexetil and enalapril on plasma renin activity (PRA) in 5/6 nephrectomized rats in the short-term experiments. The open diamonds and closed squares indicate individual values and mean values for PRA, respectively. [§]*P* < 0.05 vs. sham-operated rats (sham op.) with Student's *t*-test. [#]*P* < 0.05; ^{##}*P* < 0.01 vs. vehicle-treated rats (vehicle) with Dunnett's test. Data are presented as mean ± SE.

Table 2. Effects of candesartan cilexetil and enalapril on creatinine clearance (C_{Cr}, plasma creatinine, blood urea nitrogen (BUN), hematocrit, kidney wet weight and body weight in 5/6 NX rats at the end of both experiments

	Sham op.	Vehicle	Candesartan cilexetil	Enalapril
Short-term				
C _{Cr} ml/min/100g body wt	0.38 ± 0.03	0.31 ± 0.02	0.30 ± 0.02	0.29 ± 0.03
Plasma creatinine mg/dl	0.59 ± 0.05	0.93 ± 0.02 ^a	0.89 ± 0.04	0.99 ± 0.06
BUN mg/dl	21.7 ± 0.8	47.3 ± 2.0 ^a	44.4 ± 3.6	51.5 ± 4.4
Kidney weight g/100g body wt	0.28 ± 0.03 ^c	0.41 ± 0.02 ^a	0.41 ± 0.03	0.39 ± 0.01
Body weight g	655.0 ± 8.7	628.0 ± 24.1	619.8 ± 29.8	620.0 ± 21.4
Long-term				
C _{Cr} ml/min/100g body wt	0.47 ± 0.05	0.22 ± 0.02 ^a	0.26 ± 0.03	0.20 ± 0.03
Plasma creatinine mg/dl	0.62 ± 0.06	1.64 ± 0.26 ^a	1.23 ± 0.12	1.96 ± 0.44
BUN mg/dl	17.5 ± 1.3	74.7 ± 5.4 ^a	59.6 ± 5.7	69.8 ± 8.5
Hematocrit %	44.1 ± 0.3	34.1 ± 1.6 ^a	34.9 ± 1.2	31.7 ± 1.7
Kidney weight g/100g body wt	0.25 ± 0.01 ^c	0.42 ± 0.02 ^a	0.36 ± 0.03	0.39 ± 0.03
Body weight g	755.0 ± 21.2	673.4 ± 4.8 ^b	639.0 ± 12.7	632.6 ± 20.6

Data are presented as mean ± SE.

^a*P* < 0.01, ^b*P* < 0.05 vs. sham operated rats (Sham op.) with Student's *t*-test

^cThe wet weight of the intact right kidney

fibrosis as well as glomerulosclerosis [24, 36–39]. In this study, the expression of TGF-β₁ in the interstitium was not observed. Wu et al reported that the expression of TGF-β₁ mRNA was detected in sclerotic glomeruli, areas of tubulointerstitial injury, and sites of mononuclear cell infiltration by *in situ* hybridization for TGF-β₁ mRNA [24]. Muchaneta-Kubara, Sayed-Ahmed, and Nahas also reported that immunoreactive TGF-β₁ expression in the interstitium was observed in the remnant kidney of 5/6 NX rats [40]. On the other hand, it has been reported that positive staining of TGF-β₁ was seen in the injured glomeruli but not in the interstitium [41]. The reason for these differences remains unclear.

The inhibition of the RAS by AT₁As and ACEIs elevates PRA [42]. As renin is produced in juxtaglomerular cells and secretion is regulated by the blockade of the

AT₁ receptors, which are expressed in the same cells [42], PRA seems to be an indicator of the extent of RAS inhibition. After the four-week administration of both drugs in the short-term experiment, PRA increased to the same level, indicating that the extent of RAS inhibition by the two drugs was the same.

Despite marked improvements of proteinuria and histopathological changes, candesartan cilexetil did not show a significant effect on renal function, demonstrated by C_{Cr}, plasma creatinine, and BUN. It was reported that the progression rate of decrease in renal function was slower than the changes of proteinuria and histopathology [43]. In our study, the marked decrease in renal function was not observed during the intervention, even in the long-term experiment. As candesartan cilexetil significantly inhibited both proteinuria and histopatho-

logical changes and tended to improve the adverse changes of C_{Cr} , plasma creatinine, and BUN, the more prolonged follow-up may be helpful to clarify the preferential benefits of candesartan cilexetil on renal function.

One of the aims of this study was to investigate whether the AT_1 antagonists and ACE inhibitors would show differential renal protective effects. Very recently, Taal and Brenner reported that a 24-week treatment of candesartan cilexetil and enalapril equally reduced the progression of previously developed renal injury in 5/6 NX Munich Wistar rats [44]. In our study, significant differences were not documented between the beneficial effects of candesartan cilexetil and enalapril, although enalapril did not show significant effects on glomerulosclerosis and tubular interstitial fibrosis in the long-term experiments. A more prolonged follow-up study may be necessary to clarify this puzzle.

In conclusion, the renal protective effects of candesartan cilexetil and enalapril were examined during the progressive phase of renal injury in 5/6 NX rats. Four-week treatment with the two drugs showed renal protective effects. The 16-week treatment with candesartan cilexetil inhibited proteinuria and progressive histopathological changes such as glomerulosclerosis and interstitial fibrosis. Enalapril inhibited proteinuria but did not significantly inhibit glomerulosclerosis or interstitial fibrosis. Thus, the AT_1 receptor antagonist candesartan cilexetil may be very useful for long-term treatment of patients with chronic renal failure.

ACKNOWLEDGMENTS

We thank Mrs. Hitomi Hamajyo for her excellent technical assistance. A portion of this study was presented at the satellite symposium of the 14th International Society of Nephrology, Coolum, Australia, June 1–3, 1997.

Reprint requests to Masakuni Noda, Ph.D., Pharmaceutical Research Laboratories II, Pharmaceutical Research Division, Takeda Chemical Industries, Ltd., 2-17-85 Juso-Honmachi, Yodogawa-ku, Osaka 532-8686, Japan.

E-mail: Noda_Masakuni@takeda.co.jp

APPENDIX

Abbreviations in this article are: ACEIs, angiotensin I-converting enzyme inhibitors; Ang II, angiotensin II; AT_1A , angiotensin II type 1 receptor antagonist; BK, bradykinin; C_{Cr} , creatinine clearance; BUN, blood urea nitrogen; EDTA, ethylenediaminetetraacetic acid; H&E, hematoxylin and eosin; 5/6 NX rats, 5/6 nephrectomized rats; PAM, periodic acid-methenamine silver; PGE_2 , prostaglandin E_2 ; PRA, plasma renin activity; RAS, renin-angiotensin system.

REFERENCES

- HOSTETTER TH, OLSON JL, RENNKE HG, VENKATACHALAM MA, BRENNER BM: Hyperfiltration in remnant nephrons: A potentially adverse response to renal ablation. *Am J Physiol* 241:F85–F93, 1981
- KAGAMI S, BORDER WA, MILLER DE, NOBLE NA: Angiotensin II stimulates extracellular matrix protein synthesis through induction of transforming growth factor- β expression in rat glomerular mesangial cells. *J Clin Invest* 93:2431–2437, 1994
- MATSUSAKA T, HYMES J, ICHIKAWA I: Angiotensin in progressive renal diseases: Theory and practice. *J Am Soc Nephrol* 7:2025–2043, 1996
- ANDERSON S, MEYER TW, RENNKE HG, BRENNER BM: Control of glomerular hypertension limits glomerular injury in rats with reduced renal mass. *J Clin Invest* 76:612–619, 1985
- ANDERSON S, RENNKE HG, BRENNER BM: Therapeutic advantage of converting enzyme inhibitors in arresting progressive renal disease associated with systemic hypertension in the rat. *J Clin Invest* 77:1993–2000, 1986
- MACKENZIE HS, TROY JL, RENNKE HG, BRENNER BM: TCV-116 prevents progressive renal injury in rats with extensive renal mass ablation. *J Hypertens* 12(Suppl 9):S11–S16, 1994
- LAFFAYETTE RA, MAYER G, PARK SK, MEYER TW: Angiotensin II receptor blockade limits glomerular injury in rats with reduced renal mass. *J Clin Invest* 90:766–771, 1992
- KAKINUMA Y, KAWAMURA T, BILLS T, YOSHIOKA T, ICHIKAWA I, FOGO A: Blood pressure-independent effect of angiotensin inhibition on vascular lesions of chronic renal failure. *Kidney Int* 42:46–55, 1992
- POLLOCK DM, DIVISH BJ, POLAKOWSKI JS, OPGENORTH TJ: Angiotensin II receptor blockade improves renal function in rats with reduced renal mass. *J Pharmacol Exp Ther* 267:657–663, 1993
- LEWIS EJ, HUNSICKER LG, BAIN RP, ROHDE RD: The effect of angiotensin-converting-enzyme inhibition on diabetic nephropathy. *N Engl J Med* 329:1456–1462, 1993
- MASCHIO G, ALBERTI D, JANIN G, LOCATELLI F, MANN JFE, MOTOLESE M, PONTICELLI C, RITZ E, ZUCHELLI P, THE ANGIOTENSIN-CONVERTING-ENZYME INHIBITION IN PROGRESSIVE RENAL INSUFFICIENCY STUDY GROUP: Effect of the angiotensin-converting-enzyme inhibitor benazepril on the progression of chronic renal insufficiency. *N Engl J Med* 334:939–945, 1996
- CAMPBELL DJ, KLADIS A, VALENTIJN AJ: Effects of losartan on angiotensin and bradykinin peptide and angiotensin-converting enzyme. *J Cardiovasc Pharmacol* 26:233–240, 1995
- DZAU VJ, MUROYAMA M, PRATT RE: Molecular biology of angiotensin receptor: Target for drug research? *J Hypertens* 12(Suppl 2):S1–S5, 1994
- GAVRAS I: Bradykinin-mediated effects of ACE inhibition. *Kidney Int* 42:1020–1029, 1992
- CAMPBELL DJ, KLADIS A, DUNCAN AM: Effects of converting enzyme inhibitors on angiotensin and bradykinin peptides. *Hypertension* 23:439–449, 1994
- LIU YH, YANG XP, SHAROV VG, NASS O, SABBAB HN, PETERSON E, CARRETERO OA: Effects of angiotensin-converting enzyme inhibitors and angiotensin II type 1 receptor antagonists in rats with heart failure: Role of kinins and angiotensin II type 2 receptors. *J Clin Invest* 99:1926–1935, 1997
- PERICO N, AMUCHASTEGUI SC, COLOSIO V, SONZOGNI G, BERTANI T, REMUZZI G: Evidence that an angiotensin-converting enzyme inhibitor has different effect on glomerular injury according to the different phase of the disease at which the treatment is started. *J Am Soc Nephrol* 5:1139–1146, 1994
- VERSEPUT GH, PROVOOST AP, BRAAM BB, WEENING JJ, KOOMANS HA: Angiotensin-converting enzyme inhibition in the prevention and treatment of chronic renal damage in the hypertensive fawn-hooded rat. *J Am Soc Nephrol* 8:249–259, 1997
- NODA M, SHIBOUTA Y, INADA Y, OJIMA M, WADA T, SANADA T, KUBO K, KOHARA Y, NAKA T, NISHIKAWA K: Angiotensin II receptor antagonistic action of candesartan (CV-11974) in the rabbit aorta. *Jpn Pharmacol Ther* 24:121–126, 1996
- KUBO K, KOHARA Y, YOSHIMURA Y, INADA Y, SHIBOUTA Y, FURUKAWA Y, KATO T, NISHIKAWA K, NAKA T: Nonpeptide angiotensin II receptor antagonists: Synthesis and biological activity of potential prodrugs of benzimidazole-7-carboxylic acids. *J Med Chem* 36:2343–2349, 1993
- INADA Y, WADA T, SHIBOUTA Y, OJIMA M, SANADA T, OHTSUKI K, ITOH K, KUBO K, KOHARA Y, NAKA T, NISHIKAWA K: Antihypertensive effects of a highly potent and long-acting angiotensin II subtype-1 receptor antagonist (\pm)-1-(cyclohexyloxy-carbonyloxy) ethyl-2-ethoxy-1-[[2'-(1H-tetrazol-5-yl) biphenyl-4-yl] methyl]-1H-

- benzimidazole-7-carboxylate (TCV-116), in various hypertensive rats. *J Pharmacol Exp Ther* 268:1540–1547, 1994
22. KANAGAWA R, WADA T, SANADA T, OJIMA M, INADA Y: Regional hemodynamic effects of candesartan cilexetil (TCV-116), an angiotensin II AT₁-receptor antagonist, in conscious spontaneously hypertensive rats. *Jpn J Pharmacol* 73:185–190, 1997
 23. POWELL WS: Rapid extraction of oxygenated metabolites of arachidonic acid from biological samples using octadecylsilyl silica. *Prostaglandin* 20:947–957, 1980
 24. WU LL, COX A, ROE CJ, DZIADEK M, COOPER ME, GILBERT RE: Transforming growth factor β_1 and renal injury following subtotal nephrectomy in the rat: Role of the renin-angiotensin system. *Kidney Int* 51:1553–1567, 1997
 25. EL-DAHR SS, DIPP S, YOSIPIV IV, BARICOS W: Bradykinin stimulates c-fos expression, AP-1-DNA binding activity and proliferation of rat glomerular mesangial cells. *Kidney Int* 50:1850–1855, 1996
 26. KIM S, ANGEL P, LAFYATIS R, HATTORI K, KIM KY, SPORN MB, KARIN M, ROBERTS AB: Autoinduction of transforming growth factor β_1 is mediated by the AP-1 complex. *Mol Cell Biol* 10:1492–1497, 1990
 27. COOPER CL, MALIK KU: Evidence that bradykinin stimulates renal prostaglandin synthesis by a mechanism distinct from that of other vasoactive substances. *Circ Res* 60:914–922, 1987
 28. KON V, FOGO A, ICHIKAWA I: Bradykinin causes selective efferent arteriolar dilatation during angiotensin I converting enzyme inhibition. *Kidney Int* 44:545–550, 1993
 29. ICHIKAWA I: Will angiotensin II receptor antagonists be renoprotective in human? *Kidney Int* 50:684–692, 1996
 30. NISHIMURA H, HOFFMANN S, BALATU O, SUGIMURA K, GANTEN D, URATA H: Angiotensin I converting enzyme and chymase in cardiovascular tissues. *Kidney Int* 49(Suppl 55):S18–S23, 1996
 31. WOLNY A, CLOZEL JP, REIN J, MORY P, VOGT P, TURINO M, KIOWSKI W, FISCHLI W: Functional and biochemical analysis of angiotensin II-forming pathways in the human heart. *Circ Res* 80:219–227, 1997
 32. URATA H, STROBEL F, GANTEN D: Widespread tissue distribution of human chymase. *J Hypertens* 12(Suppl 9):S17–S22, 1994
 33. WINTROUB BU, KLINKSTEIN LB, DZAU VJ, WATT WK: Granulocyte angiotensin system: Identification of angiotensinogen as the plasma protein substrate of leukocyte cathepsin G. *Biochemistry* 23:227–232, 1984
 34. OZONO R, WANG ZQ, MOORE AF, INAGAMI T, SIRAGY HM, CAREY RM: Expression of the subtype 2 angiotensin (AT₂) receptor protein in rat kidney. *Kidney Int* 30:1238–1246, 1997
 35. WOLF G, ZIYADEH FN, THAISS F, TOMASZEWSKI J, CARON RJ, WENZEL U, ZAHNER G, HELMCHEN U, STAHL RAK: Angiotensin II stimulates expression of the chemokine RANTES in rat glomerular endothelial cells: Role of the angiotensin type 2 receptor. *J Clin Invest* 100:1047–1058, 1997
 36. ISAKA Y, FUJIWARA Y, UEDA N, KANEDA Y, KAMADA T, IMAI E: Glomerulosclerosis induced by in vivo transfection of transforming growth factor- β or platelet-derived growth factor gene into the rat kidney. *J Clin Invest* 92:2597–2601, 1993
 37. KOPP JB, FACTOR VM, MOZES M, NAGY P, SANDERSON N, BOTTINGER EP, KLOTMAN PE, THORGEIRSSON SS: Transgenic mice with increased plasma levels of TGF- β_1 develop progressive renal disease. *Lab Invest* 74:991–1003, 1996
 38. EGIDO J: Vasoactive hormones and renal sclerosis. *Kidney Int* 49:578–597, 1996
 39. FLOEGE J, ENG E, YOUNG BA, JOHNSON RJ: Factors involved in the regulation of mesangial cell proliferation in vitro and in vivo. *Kidney Int* 43(Suppl):S47–S54, 1993
 40. MUCHANETA-KUBARA EC, SAYED-AHMED N, NAHAS AM: Subtotal nephrectomy: A mosaic of growth factors. *Nephrol Dial Transplant* 10:320–327, 1995
 41. KONTA T, DEGAWA N, KATO S, TOMOIKE H: Role of transforming growth factor- β_1 during glomerulosclerosis in rats with reduced renal mass. *Clin Exp Nephrol* 1:187–194, 1997
 42. GASC JM, MONNOT C, CLAUSER E, CORVOL P: Co-expression of type 1 angiotensin II receptor (AT₁R) and renin mRNAs in juxtaglomerular cells of rat kidney. *Endocrinology* 132:2723–2725, 1993
 43. GRIFFIN KA, PICKEN M, BIDANI AK: Method of renal mass reduction is a critical modulator of subsequent hypertension and glomerular injury. *J Am Soc Nephrol* 4:1023–1031, 1994
 44. TAAL MW, BRENNER BM: ACE-I vs angiotensin II receptor antagonists: Prevention of renal injury in chronic rat models. *J Hum Hypertens* 13(Suppl 1):S51–S56, 1999