PRENATAL DIAGNOSIS, VOL. 6, 265–269 (1986)

ESTIMATION OF THE WEIGHT OF CHORIONIC VILLUS SAMPLES OBTAINED FROM FIRST TRIMESTER PREGNANCIES BY TRANSCERVICAL ASPIRATION

MELANIE NEWPORT AND DULCIE V. COLEMAN
Cytogenetics Unit, St Mary's Hospital Medical School, London W2, U.K.
AND
KLIM McPHERSON
Department of Community Medicine, Gibson Laboratories Building, Radcliffe Infirmary, Oxford, U.K.

SUMMARY

Eight obstetricians experienced in chorionic villus sampling were asked to estimate the weight of samples of villi with and without a reference photograph. Referral to the photograph significantly improved the accuracy of their estimations.

KEY WORDS Chorionic villi Transcervical aspiration Prenatal diagnosis

INTRODUCTION

Chorionic villus sampling is now offered by many obstetric units in the U.K., Europe and North America for the prenatal diagnosis of genetic disease in the first trimester of pregnancy. There is however, a large element of uncertainty about the safety of the procedure and several countries have embarked on randomized controlled trials of the technique in order to obtain information about the risks of the technique.

The MRC trial that is underway in the U.K., is seeking information about sample weight in order to determine whether there is an association between the weight of villus material removed at biopsy and subsequent fetal loss. Information about sample weight will also be of value in determining the optimum amount of villus material required for the accurate laboratory diagnosis of genetic disease.

In order to standardize the recording of sample weight, we have prepared a reference photograph which can be used by centres participating in the trial. We report here, the results of a small study which showed that photographic standards improve the accuracy of estimation of sample weight.

METHOD

Standard samples were prepared from chorionic villi dissected from an eight week gestation sac. One, 5, 10, 15, 20, 25, 30, 50 and 100 mg samples were weighed into

Request for reprints to: Dr D. V. Coleman, St Mary's Hospital Medical School, Cytogenetics Department, Praed St, London W2, U.K.

0197–3851/86/040265–06$05.00
© 1986 by John Wiley & Sons, Ltd.
Received 21 December 1985
Accepted 9 January 1986

petri dishes 10 × 35 mm diameter, suspended in 3 ml formol saline and photographed actual size (Figure 1).

Seven test samples (A–G) were prepared in a similar way, each containing a different weight of villus material (actual weights 3, 5, 8, 10, 13, 17 and 20 mg). Individual actual size photographs of each sample were prepared. The photographs of the test samples were shown one at a time to eight obstetricians experienced in villus sampling who were asked to estimate the weight of the tissue in milligrams. They were then shown the reference photograph (Figure 1) and asked to estimate the weights of the test samples again.

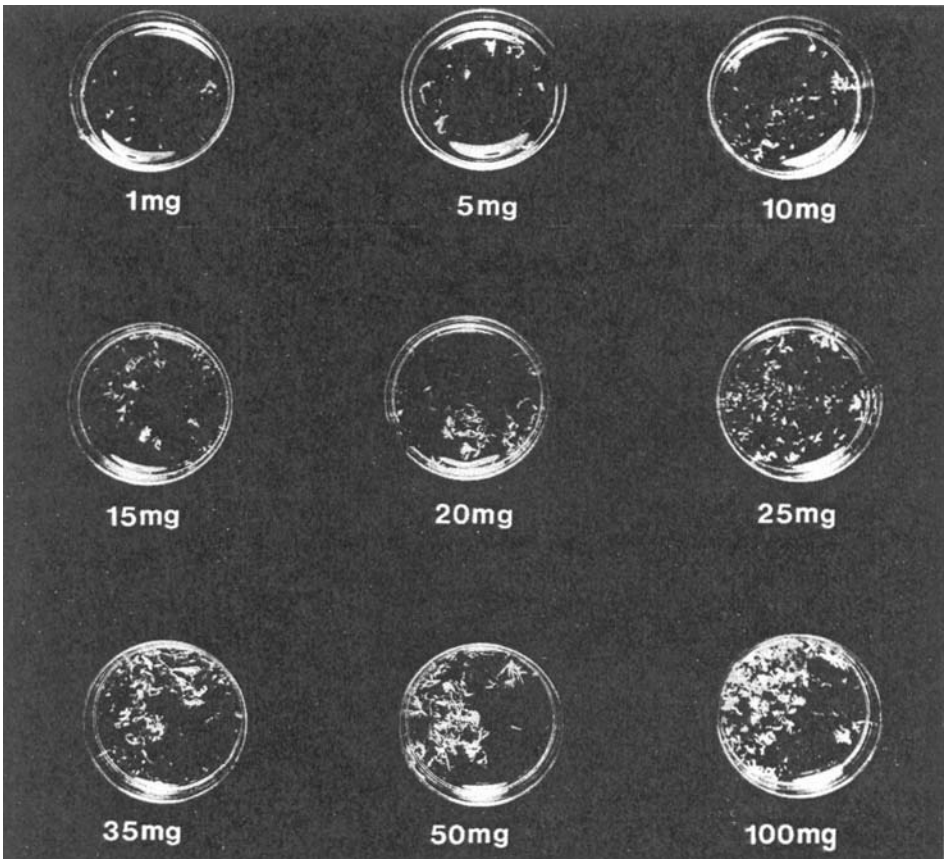

Figure 1. Reference photograph containing standard samples of chorionic villi suspended in 3 ml formol saline (reproduced at 60%)

RESULTS

The estimated weights for the seven samples, with and without reference to the photographic standard are recorded in Table 1 and are shown graphically in Figure 2. They strongly indicate that both precision and accuracy are improved with reference to the standard.

With the standard there was a tendency to overestimate the weights by about

Table 1. Estimated weights (mg) for serum samples (A–G) with and without reference to photographs recorded by eight obstetricians experienced in villus sampling

Actual value	3		5		8		10		13		17		20	
	Without ref	With ref	Without ref	With ref	Without ref	With ref	Without ref	With ref	Without ref	With ref	Without ref	With ref	Without ref	With ref
	10	5	15	7	15	10	20	13	50	22	50	15	100	17
	5	2	10	5	10	10	10	10	15	15	20	18	40	20
	5	3	5	4	10	10	15	17	20	22	20	20	20	30
	8	3	14	8	15	13	15	8	40	13	30	16	33	20
	3	5	5	5	10	10	5	10	10	15	15	20	15	20
	10	5	5	5	10	10	13	10	10	15	20	15	25	20
	1	2	2	5	6	8	7	10	10	10	10	15	15	15
	3	1	3	5	7	8	7	10	10	15	10	15	20	15
Mean	5·6	3·3	6·1	5·5	10·4	9·9	11·5	11·0	20·6	15·9	21·9	16·8	33·5	19·6
Standard deviation	3·4	1·6	3·9	1·3	3·2	1·6	5·1	2·8	15·7	4·2	13·1	2·3	28·2	4·7
Range	1–10	1–5	2–15	4–8	6–15	8–13	5–20	8–17	10–50	10–22	10–50	15–20	15–100	15–30
Code letter	D		F		A		B		E		C		G	

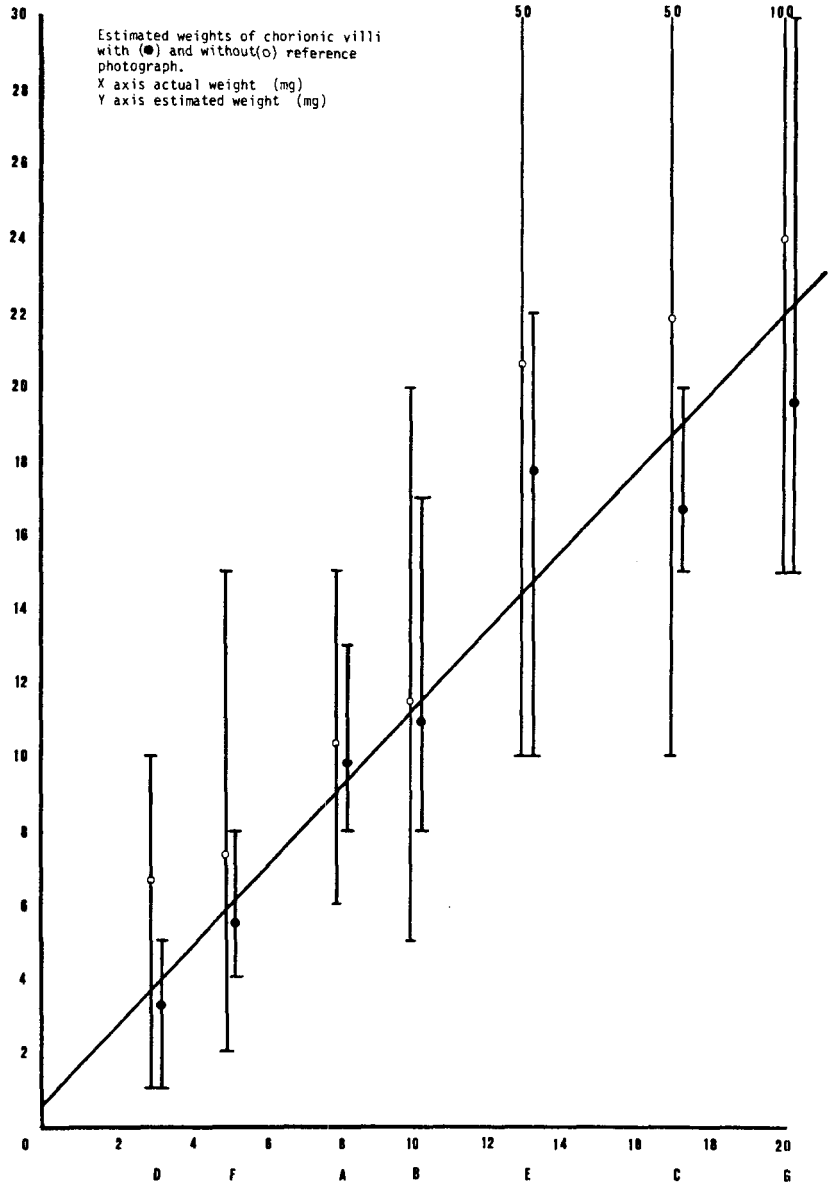

Figure 2. Graph showing estimated weights of chorionic villi with and without reference photographs

10 per cent but this figure was heavily weighted by one sample (sample E) for which the overestimate is severe. This may be partially due to digit preference for 10 and 15 in a sample whose actual weight was 13 mg. Without this result, the average of the observers was within 5 per cent of the real weight. Ranking all observers for each sample indicates that there is a tendency for some observers to be consistently biased. If this were not so, the average rank across samples for each observer would not differ significantly from 4·5 (the average of the numbers 1 to

8). As it is, two observers were significantly lower than 4·5 and one significantly higher—but this gives undue emphasis to particular observers when the overall distribution of average rank is not random but possibly a matter of experience.

DISCUSSION

The weight of villi obtained at a single attempt at chorion biopsy depends on the experience of the operator, the gestational age of the fetus and the site of the developing placenta.

The villi are often intimately mixed with blood and decidua, making estimation of villus weight difficult. Comparison of aspirates with a photographic standard would improve the accuracy of these estimates.

The risks of fetal loss due to villus sampling depends on a number of factors, of which the size of the sample is only one example. Other factors include the amount of bleeding incurred by the sampling procedure and the number of attempts needed to obtain an adequate sample. The amount of blood staining is difficult to quantitate and is usually described as slight, moderate or heavy.

The amount of villus material needed for diagnostic studies varies according to the type of tests performed on the sample. It has been suggested that 10 mg is sufficient for DNA analysis although this amount is inadequate for enzyme assay. By recording the amount of villi available for diagnosis, the U.K. trial will be able to determine whether the diagnostic accuracy of chorionic villus sampling depends on the size of the sample. It will also be able to determine whether the size of the sample affects the risk of fetal loss.

ACKNOWLEDGEMENT

We thank the MRC Working Party on the Safety of Chorionic Villus Sampling for proposing this research. We also thank the obstetricians from the various centres for their cooperation.