J Clin Ultrasound 7:379–380, 1979

Case Report

ULTRASOUND DIAGNOSIS OF QUINTUPLETS FOLLOWING CLOMIPHENE-INDUCED OVULATION

Roger W. Warner, B.S., R.D.M.S., Shashi Sharma, M.D., and Harold E. Fox, M.D.

Clomiphene citrate (Clomid) is a nonsteroidal compound with a structure similar to that of estrogen. The precise method of action of clomiphene is unknown, but it probably acts by competing with estrogen for estrogen receptor sites at the level of the hypothalamus. This competition interferes with the negative-feedback system of the hypothalamus. Sensing that the estrogen level in the circulation is low, the hypothalamus releases luteinizing hormone releasing hormone (LHRH), which stimulates the pituitary gland to secrete gonadotropins.

The surge in LHRH is believed to be the final event inducing ovulation. Clomiphene citrate does not directly induce ovulation by an effect on the ovary; rather, it initiates or enhances the normal series of events leading to ovulation *(1)*.

The patient suffering from anovulatory infertility may be classified into one of two categories: (a) anovulation with an intact pituitary-ovarian axis with estrogen and gonadotropin production; (b) anovulation caused by deficiency in estrogen and/or gonadotropins. Those patients with evidence of estrogen production (group I) are more likely to respond to ovulation induction by clomiphene citrate therapy.

Clomiphene citrate therapy is usually begun on the fifth day of the menstrual cycle with a 50-mg dose given daily for 5 days, although this may vary considerably according to the response of the individual patient. Ovulation usually occurs 5–10 days after the last day of medication.

The incidence of twin pregnancy in the general population is approximately 1 in 90 births. The incidence of multiple gestation in clomiphene-induced pregnancies is approximately 10 in 100 births, almost entirely dizygotic gestations *(2)*.

From the Department of Obstetrics and Gynecology, University of Rochester, School of Medicine and Dentistry, Strong Memorial Hospital, Rochester, NY.

Manuscript received March 23, 1979; accepted May 21, 1979.

For reprints contact Roger W. Warner, B.S., Department of Obstetrics and Gynecology, Box 668, University of Rochester, School of Medicine and Dentistry, 601 Elmwood Avenue, Rochester, NY 14642.

0091-2751/79/050379-02 $01.00

CASE STUDY

A 28-year-old patient (gravida 6, para 1-0-4-1) with documented polycystic ovary disease was referred to the ultrasound laboratory for evaluation of pregnancy. She presented a history of oligomenorrhea since menarche at age 15 years, with normally developed secondary sexual characteristics. All prior pregnancies had been conceived after clomiphene citrate therapy. She had had one live birth and four spontaneous miscarriages, presumably due to corpus luteum deficiency. The patient was referred to the obstetrics-gynecology ultrasound facility because of a clinically large-for-date uterus associated with the pregnancy. Based on her last menstrual period of January 18, 1978, the gestational age at the time of the initial ultrasound examination was 16.5 weeks. The patient began clomiphene therapy on January 23, 1978, with a dosage of 100 mg/day for 5 days. The fundal height was 24 cm from the top of the symphysis. The first ultrasound examination revealed a probable quintuplet pregnancy.

A second ultrasound examination 1 week later confirmed the initial diagnosis of quintuplets. Figure 1 shows four of the five heads. Multiple membranous partitions were seen dividing the amniotic cavity into compartments, with placental tissue visualized on the anterior uterine wall (Fig. 2). By use of a combination of B-mode scanning and real-time imaging, it was possible to delineate each fetus and measure the biparietal diameters. All five fetuses were found to be viable. Examinations at 17.5 and 22 weeks of gestation showed normal fetal growth patterns, but it became increasingly difficult to perform a complete examination because of the patient's discomfort when lying supine and because of the gross activity of the fetuses.

At 22 weeks of menstrual gestation the patient began spontaneous uterine contractions. She was hospitalized and started on therapy to inhibit uterine contractions. The patient began to have vaginal bleeding, which eventually became heavy, requiring transfusion of 3 units of blood.

There was no evidence of placenta previa on

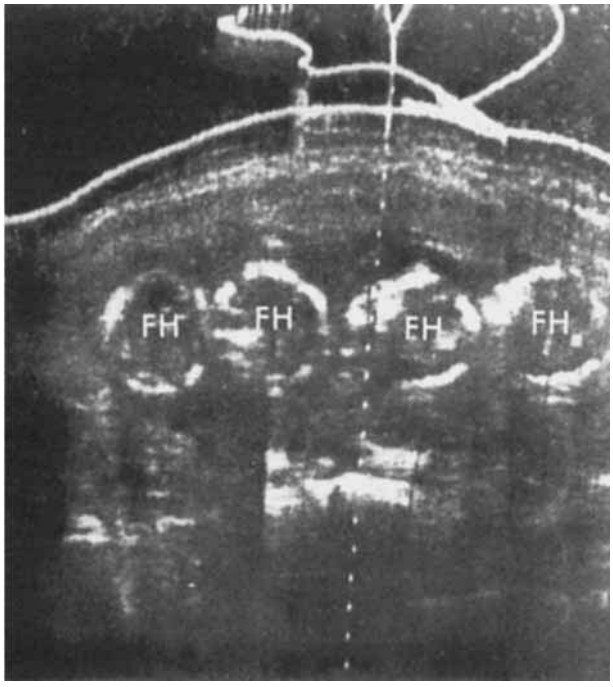

FIGURE 1. Oblique scan of the uterus shows four of the five fetal heads (FH).

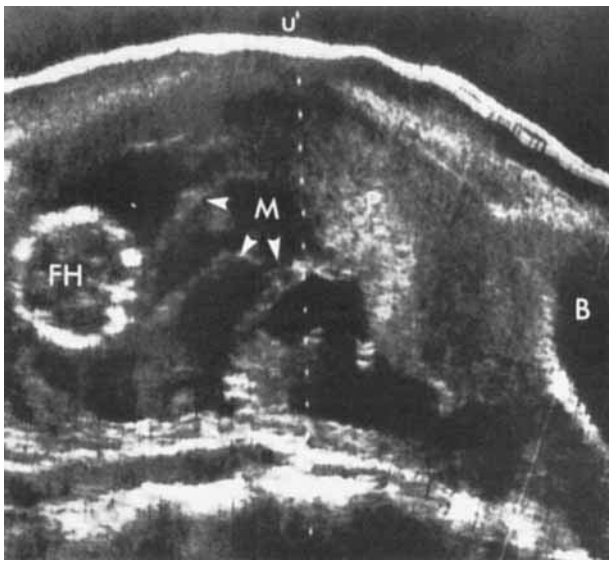

FIGURE 2. Longitudinal scan in the midline demonstrates the multiple membranes (M) and anterior placental tissue (P). Fetal head (FH) and maternal bladder (B) are also seen. U: umbilicus.

the ultrasound examination. Because of heavy vaginal bleeding, the patient underwent an emergency cesarean section delivery on June 26, 1978. All five infants died shortly after birth. Abruption of one placenta was diagnosed at surgery.

COMMENTS

A quintuplet pregnancy following clomiphene citrate induction of ovulation is a rare occurrence *(3)*. This is apparently the first reported diagnosis of quintuplets by ultrasound in a patient following clomiphene induction of ovulation.

Multiple pregnancies involving three or more fetuses present special problems to the sonographer and the physician. As reported by Gottesfeld *(4)*, there is often poor correlation between the numbers of heads and chests. We found it most advantageous to locate the heads and chests independently using a combination of contact scanning and linear-array real-time ultrasound. Following this, sequential scanning of the uterus in longitudinal and transverse planes was carried out. Finally, the linear-array real-time scanner was used to line up the long axis of each fetus and verify viability.

It is important for the physician and the sonographer to be alert to the higher incidence of twinning associated with ovulation induction by this medication. Careful attention to scanning technique is important in verifying the number of fetuses present in multiple pregnancies.

REFERENCES

1. Speroff L, Glass RH, Kase NG: Clinical Gynecology, Endocrinology, and Fertility. Baltimore, Williams & Wilkins, 1978.
2. Johnson JE: Outcome of pregnancies following clomiphene citrate therapy. Presented at the Fifth World Congress of Fertility and Sterility, Stockholm, 1966.
3. Schenker JG, Simha A: Quintuplet pregnancy. Obstet Gynecol 45:590, 1975.
4. Gottesfeld KR, Sundgren C, Chavez F: The diagnosis of sextuplets by ultrasound—a case report. J Clin Ultrasound 2:291, 1974.