

LETTERS AND  
CORRESPONDENCE

Letters and correspondence submitted for possible publication must be identified as such. Text length must not exceed 500 words and five bibliographic references. A single concise figure or table may be included if it is essential to support the communication. Letters not typed double-spaced will not be considered for publication. Letters not meeting these specifications will not be returned to authors. Letters to the Editor are utilized to communicate a single novel observation or finding. Correspondence is to be used to supplement or constructively comment on the contents of a publication in the journal and cannot exceed the restrictions for Letters to the Editor. The Editor reserves the right to shorten text, delete objectional comments, and make other changes to comply with the style of the journal. Permission for publication must be appended as a postscript. Submissions must be sent to Paul Chervenick, M.D., Editor of Brief Reports/Letters to Editors, American Journal of Hematology, H. Lee Moffitt Cancer Center, University of South Florida, 12902 Magnolia Drive, Tampa, FL 33612 to permit rapid consideration for publication.

### Feasibility of Restriction Enzyme Protocols for the Molecular Diagnosis of Abnormal Hemoglobins in Turkish Population

To the Editor: Hb S ( $\beta 6$  Glu-Val), Hb D Los Angeles ( $\beta 121$  Glu-Gln) and Hb O Arab ( $\beta 121$  Glu-Lys) are the most common variants in Turkish population including Turkish Cypriots [1,2]. Either during screening of the population or to enlighten the reason of anemia; several abnormal hemoglobin variants can be detected by screening techniques and further molecular identification of these variants is needed. There are several identification methods such as protein chemical structural analysis, restriction enzyme digestion, sequencing, and oligonucleotide hybridization [3,4]. Previously, we and others reported restriction enzyme digestion protocols for direct detection of common hemoglobin variants found in general population [5–9]. These methods were convenient, rapid, cheap, and non-radioactive. In this report, we aim to determine the feasibility of these restriction enzyme protocols in our population.

During the last 4 years, 65 hemoglobin variants were referred to our laboratory for molecular analysis, excluding hemoglobin S. These were analysed according to previously reported restriction enzyme analysis protocols [5–9] (Table I). Fifty-four of them were identified. Of these 21 were Hb D Los Angeles ( $\beta 121$  Glu-Gln); 23 were Hb O Arab ( $\beta 121$  Glu→Lys); five were Hb C ( $\beta 6$  Glu-Lys); one was Hb D Los Angeles in combination with Hb S; two were Hb E Saskatoon ( $\beta 22$  Glu-Lys); and two were ( $\beta 26$  Glu-Lys).

Further analysis was needed in only 11 (16.9%) samples. These variants were moved as Hb D (7 case); Hb E (2 case) and Hb J (2 cases) at cellulose acetate electrophoresis.

Our data revealed that our previously reported restriction enzyme digestion protocols are convenient, rapid and feasible, especially in populations where these mutations are prevalent.

N. AKAR  
E. AKAR  
H. TAŞTAN

Department of Pediatric Molecular Pathology, Ankara University,  
Turkey

© 1999 Wiley-Liss, Inc.

**TABLE I. Restriction Endonucleases Used for the Molecular Analysis of Abnormal Hemoglobin Variants**

Variant		RE
Hb S	$\beta 6$	Dde I <sup>a</sup>
Hb D Los Angeles	$\beta 121$	EcoR I <sup>a</sup> /Tsp 509 I <sup>b</sup>
Hb O Arab	$\beta 121$	EcoR I <sup>a</sup> /Acs I <sup>c</sup>
Hb E Saskatoon	$\beta 22$	Fok I <sup>a</sup>
Hb E	$\beta 26$	Mnl I <sup>b</sup>
Hb C	$\beta 6$	BseR I <sup>b</sup> /Dde I <sup>a</sup>

<sup>a</sup>Promega, USA.

<sup>b</sup>Biolabs, USA.

<sup>c</sup>Boehringer Mannheim, Germany.

### REFERENCES

- Arcasoy A. Hemoglobinopathies in Turkey. *Hematology Reviews Com* 1992;6:61.
- Cin Ş, Akar N, Arcasoy A, Çavdar AO. Abnormal hemoglobins in Turkish Cypriots. *Hemoglobin* 1988;12:423–425.
- Huisman THJ, Jonxis THP. The Hemoglobinopathies: techniques of identification. *Clinical and Biochemical Analysis*, Vol. 6. New York: Marcel Dekker, Inc.; 1997.
- Trent JR, Davis B, Wilkinson T, Kronenberg A. Identification of beta variant hemoglobins by DNA restriction endonuclease mapping. *Hemoglobin* 1984;8:443.
- Baysal E. Novel and Current Molecular Diagnostic in Hemoglobinopathies. In: Ulutin ON, editor. *Lectures, XIIIth Meeting of the International Society of Haematology*, pp. 66–70. Istanbul; 1995.
- Akar N, Özden A, Akar E, Cin Ş, Arcasoy A. Discrimination of Hb D Los Angeles ( $\beta 121$  Glu-Val) and Hb Beograd ( $\beta 121$  Glu-Val) by dual Restriction enzyme analysis. *Am J Hematol* 1995;48:280.
- Akar N, Akar E, Taştan H, Cin Ş. Verification of Hb O-Arab ( $\beta 121$  (GH4) Glu-Lys) by dual restriction enzyme analysis. *Hemoglobin* 1996;20:161.
- Akar N, Akar E, Taştan H, Cin Ş. Direct detection of Hb C ( $\beta 6$  Glu-Lys) by BseRI Analysis. *Am J Hematol* 1996;52:325.
- Akar N, Akar E. Further note for the discrimination of Hb C. *Am J Hematol* 1998;57:181.

### Fatal Pulmonary Fibrosis After a Low Cumulated Dose of Bleomycin: Role of Alpha1-Antitrypsin Deficiency?

To the Editor: Bleomycin is a well-known pneumotoxic drug and can be the cause of severe and life-threatening complications. These complications are not predictable despite some risk factors. We report on the case of a patient who developed a severe and fatal pulmonary fibrosis after a low cumulated dose of this drug.

A 63-year-old male patient was admitted to the hospital for a stage IIIAB Hodgkin's disease of the nodular sclerosing subtype. The thoracic computer tomography scan found a moderate mediastinal extension (mediothoracic ratio below 0.33) with images of bullous emphysema and paraseptal and subpleural lesions without interstitial syndrome. Smoking history found a cumulated consumption of 30 pack-years without major infection. Pulmonary function tests showed a moderate airflow obstruction with a forced vital capacity of 95%, and a Tiffeneau's index of 82%. The CO diffusion tests were abnormal with a CO lung transport of 40% and a

CO lung transport:VA ratio of 29%. These values were attributed to the emphysema. After three courses of the ABVD-MP regimen, associating adriamycin, intravenous bolus of bleomycin, vincristine, dacarbazine and methylprednisolone, so a cumulative dose of 60 mg of bleomycin and before any radiation therapy, the patient presented with cough, fever, and dyspnea with infiltrates of the right superior pulmonary lobe. The alveolar washing eliminated an opportunistic infection and showed a cellularity of 163/mm<sup>3</sup> with 93% alveolar cells and macrophages with a Golde's score of 100. The fourth course was administered without bleomycin, but dyspnea worsened with a hypoxemia of 45 mmHg, a hypocapnia of 33 mmHg and a CO lung transport markedly decreased to 18%. A heterozygous deficit of SZ alpha1-antitrypsin was then revealed with a level of 1.42 g/l (N: 1.7 to 3.5). Despite corticosteroid and mechanical ventilation with low concentration of oxygen, the patient died 9 months later in the intensive care unit without evidence of lymphoma. This observation seems to us instructive on several aspects. It recalls the risk of fatal pulmonary fibrosis even for a total cumulative dose of bleomycin below 100 mg and without pejorative factors: age over 70 years, association with another pneumotoxic drug, radiation therapy, or general anesthesia. It emphasizes the difficulties of interpretation of CO<sub>2</sub> diffusion tests in a case of concurrent pulmonary illness. Thus, in our case, anomalies have been attributed to the increase of the alveolar volume. The question of the pathogenicity of the fibrosis is posed [1]. Thus, the  $\alpha$ 1-antitrypsin deficit could play a role via the induction of a vasculitis [2,3]. Finally, we address the question of the evaluation of this deficit especially when the treatment should combine bleomycin and chest irradiation.

CAROL ALLIOT  
STEPHANIE TABUTEAU  
BERNARD DESABLENS

*Division of Blood Diseases, University Hospital of Amiens, Amiens  
Cedex, France*

PIERRE AUBRY

*Division of Pulmonary Diseases, University Hospital of Amiens, Amiens  
Cedex, France*

MAURICE ANDREJAK

*Laboratory of Pharmacology, University Hospital of Amiens, Amiens  
Cedex, France*

#### REFERENCES

1. Absher M, Hildebran J, Trombley L, Woodcock-Mitchell J, Marsh J. Characteristics of cultured lung fibroblasts from bleomycin-treated rats. Comparisons with in vitro exposed normal fibroblasts. *Am Rev Resp Dis* 1984;129:125-129.
2. Mazodier P. Association entre déficit en alpha-1-antitrypsine et maladie rénale (revue de 48 cas dont 17 personnels). *Pediatric* 1977;13:205-219.
3. Roge C, Szapiro N. Déficit en alpha-1-antitrypsine et vascularites systémiques: données complémentaires. *Presse Med* 1994;23:1096.

### Mesenteric Vein Thrombosis Secondary to Combined Protein C Deficiency and Double Heterozygosity for Factor V Leiden and Prothrombin G20210A

*To the Editor:* We describe a previously well 64-year-old man who presented with progressive abdominal pain over a 3-day period. At laparotomy he was found to have a severely ischaemic length of small bowel involving both his jejunum and ileum. A total of 125 cm of small bowel was resected which histologically, was found to show full thickness haemorrhagic infarction. Sections taken from the mesenteric vessels showed extensive intravenous thrombus. A diagnosis of small bowel infarction secondary to

mesenteric vein thrombosis was confirmed. Following recovery from surgery the patient was fully anticoagulated and currently remains on long-term oral warfarin.

Results of thrombophilic investigations demonstrated that the patient was deficient in protein C with levels of 28% and 10%, measured on two separate occasions, respectively. Furthermore, he was found by PCR and restriction enzyme digestion to be heterozygous for both factor V Leiden and the prothrombin (PT) G20210A variant. Levels of antithrombin III and protein S were normal, whereas antiphospholipid antibodies were absent. The propositus had four children, only one of whom had experienced a spontaneous venous thromboembolism at the age of 40. All four children had normal levels of protein C, whereas factor V Leiden and PT G20210A mutations were not tested.

A number of individuals and families have been described in whom thromboembolic episodes have occurred in the presence of protein C or protein S deficiency in association with factor V Leiden [1-4]. In each case the prevalence of factor V Leiden was high among symptomatic individuals with either protein C or protein S deficiency [1,2]. Furthermore, when thrombosis does occur in these double heterozygotes it does so at a younger age. These observations strongly support the evidence of an increased thrombotic risk conferred by the co-existence of heterozygous protein C and protein S deficiency and factor V Leiden.

The frequency of double heterozygotes for the PT G20210A mutation and factor V Leiden has been reported at a prevalence of 2.7% [5] and 0.6% [6], respectively. Additionally, Veyradier et al. found a prevalence for the association of both risk alleles of 1% (two patients) among a series of 200 unselected patients with pulmonary embolism, a value expected from the frequency of both alleles [7]. Accordingly, simultaneous inheritance of protein C deficiency, factor V Leiden, and the PT 20210G/A allele is likely to be a rare occurrence.

Mesenteric vein thrombosis has been described in patients with deficiencies of antithrombin, protein C, protein S, as well as factor V Leiden, and, more recently, the PT G20120A mutation [8,9]. Recently, Darnige et al. reported two patients heterozygous for the PT 20210A allele who exhibited a mesenteric vein thrombosis as their first presentation of thromboembolic disease [10]. In the current case, the patient had a combination of protein C deficiency, and double heterozygosity for factor V Leiden and the prothrombin 20210A allele, presenting with mesenteric vein thrombosis as his first thromboembolic event at the age of 64. This rare association of three independent thrombophilic risk factors confirms the paradigm of a multigenic process in the pathogenesis of thromboembolic disease.

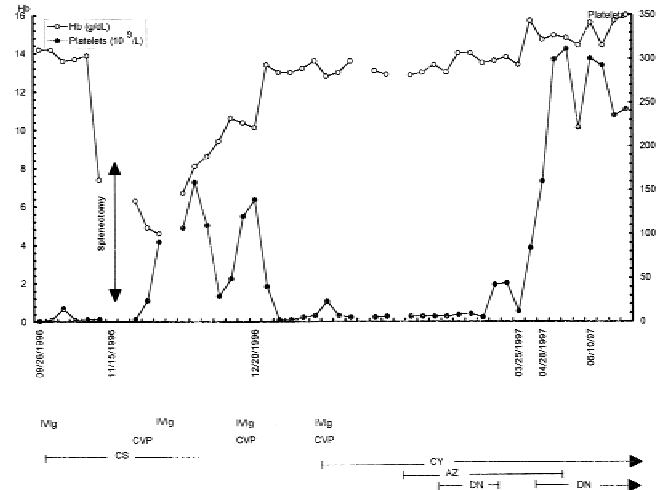
M.S. HERTZBERG  
T. UNDERWOOD  
E.J. FAVALORO

*Department of Haematology, Westmead Hospital, Westmead, Australia*

#### REFERENCES

1. Koeleman BPC, Reitsma PH, Allaart CR, and Bertina RM. Activated protein C resistance as an additional risk factor for thrombosis in protein C-deficient families. *Blood* 1994;84:1031-1035.
2. Zollar B, Berntsdotter A, de Frutos PG, and Dahlback B. Resistance to activated protein C as an additional genetic risk factor in hereditary deficiency of protein S. *Blood* 1995;85:3518-3523.
3. Grandille SG, Greengard JS, Alhenc-Geleas M, Juhan-Vargue I, Abgrall JF, Jude B, Griffin JH, and Aiach M. Incidence of activated protein C resistance caused by the ARG506 GLN mutation in factor V in 113 unrelated symptomatic protein C-deficient patients. *Blood* 1995;86:219-224.
4. Grandille S, Borgel D, Aiach M. The French Network INSERM on molecular abnormalities responsible for protein C and protein S deficiencies. Incidence of activated protein C resistance due to ARG 506 GLN mutation in factor V in 116 unrelated propositus from families with protein S deficiency. *Thromb Haemost* 1995;73:1372.
5. Poort SR, Rosendall FR, Reitsma PH and Bertina RM. A common genetic variation in the 3' untranslated region of the prothrombin gene is associated with elevated plasma prothrombin levels and an increase in venous thrombosis. *Blood* 1996;88:3698-3703.

- Brown K, Luddington R, Williamson D, Baker P, and Baglin T. Risk of venous thromboembolism associated with a G to A transition at position 20210 in the 3' untranslated region of the prothrombin gene. *Br J Haematol* 1997;98:907-909.
- Veyradier V, Wolf M, Boyer-Neumann, Parent F, Simonneau G, and Meyer D. Recurrent thromboembolism in two unrelated patients with double heterozygosity for factor V R506Q and factor II 20210G/A mutations. *Thromb Haemost* 1998; 80:201-202.
- Imagaki H, Sakakibara O, Miyaike H, Eimoto T, and Yura J. Mesenteric venous thrombosis in familial protein S deficiency. *Am J Gastroenterol* 1993;88:2143.
- Heresbach D, Pagenault M, Gueret P, Crenn P, Heresbach-Le Berre N, Malledant Y, Fauchet R, Horellou MH, Silver J, Messing B, and Bretagne JF. Leiden factor V mutation in four patients with small bowel infarctions. *Gastroenterol* 1997; 113:322-325.
- Darnige L, Jezequel P, Amoura Z, Horellou M-H, Dorval I, and Piette J-C. Mesenteric venous thrombosis in two patients heterozygous for the 20210A allele of the prothrombin gene. *Thromb Haemost* 1998;80:703.



**Fig. 1. Evolution of platelet count during different treatments.**

### Salvage Therapy and Long-Term Remission With Danazol and Cyclosporine in Refractory Evan's Syndrome

*To the Editor:* Evan's syndrome is a rare hematological disease. Initial therapeutic failure, relapses after initial response and refractoriness to many treatments are typical [including corticosteroids (CS), chemotherapy, intravenous immunoglobulins (IV Ig), danazol (DZ), and/or cyclosporine (CY)] [1]. We report long-term remission of Evan's syndrome obtained with CY and DZ.

A 32-year-old previously healthy man was admitted in September 1996 for severe thrombocytopenic purpura (platelets  $2 \times 10^9/l$ ). Examination of bone marrow smears showed numerous megacaryocytes. There were no evidence of secondary immune thrombocytopenic purpura. He received IV immunoglobulin (Ig) (Sandoglobuline® 1 g/kg/day for 2 days) and high-dose pulse dexamethasone (15 mg/kg/day for 3 days), followed by prednisone (1 mg/kg/day) and dapsone (100 mg/day for 15 days). The platelet count remained below  $10 \times 10^9/l$ . On November 10, severe autoimmune hemolytic anemia developed [Hb: 5.6 g/dl; reticulocytes:  $200 \times 10^9/l$ ; positive direct antiglobulin test (IgG + C); undetectable haptoglobin] without clinical or biological evidence of systemic lupus erythematosus; platelet count was  $2 \times 10^9/l$ ; no schistocytes were observed. Despite several treatments including IV Ig, CS, cyclosporine/vincristine/prednisone and splenectomy, life-threatening thrombocytopenia persisted (Fig. 1). CY (the dose was adjusted to 200-400 ng/ml in whole blood) was initiated in January 1997. Azathioprin (AZ; 100 mg/day) and DZ (400 mg/day) were added in February 1997. The platelet count began to rise ( $42 \times 10^9/l$ ) 21 days after the introduction of DZ and 2 months after starting CY. DZ was then stopped, but had to be reintroduced in March because of relapsing thrombocytopenia. The platelet count returned to normal 1 month later. AZ was stopped in June 1997 and CS in January 1998. Between August 1997 and January 1999, no relapse occurred under DZ and low-dose CY.

To the best of our knowledge, long-term treatment of Evan's syndrome with a combination of DZ and CY in Evan's syndrome has not been reported previously. CY is a powerful immunosuppressant agent that acts

on proliferating T lymphocytes. Several reports have suggested that it could be beneficial in patients with refractory autoimmune hematological disorders, including refractory immune thrombocytopenic purpura, aplastic anemia, AHA and Evans syndrome [2,3]. DZ has been proposed as a less toxic alternative to long-term CS therapy in autoimmune hematological disorders. Although reports on DZ therapy for autoimmune haemolytic anemia are scarce, its efficacy has been suggested in refractory or relapsing patients. For Evan's syndrome, good results had been obtained by using DZ combined with vincristine [4] or prednisone [5]. Our patient's relapse of thrombocytopenia after the withdrawal of DZ and its remission after DZ resumption suggest its therapeutic benefit.

**KADOUJA CHEMLAL  
BENJAMIN WYPLOSZ**

*Department of Internal Medicine, Hôpital Bichat, Paris Cedex, France*

**MARIE-JOSÉ GRANGE**

*Department of Hematology, Hôpital Bichat, Paris Cedex, France*

**KAISS LASSOUED**

**JEAN-PIERRE CLAUVEL**

*Department of Immuno-Hematology, Hôpital Saint-Louis, Paris Cedex, France*

#### REFERENCES

- Wang WC. Evans syndrome in childhood: pathophysiology, clinical course and treatment. *Am J Pediatr Hematol* 1988;10:330-338.
- Emilia G, Messora C, Longo G, Bertesi M. Long-term salvage treatment by cyclosporin in refractory autoimmune haematological disorders. *Br J Haematol* 1996;93:341-344.
- Rackoff WR, Manno CS. Treatment of refractory Evans syndrome with alternate-day cyclosporine and prednisone. *Am J Pediatr Hematol* 1994;16:156-159.
- Scaravadou A, Bussel J. Evans syndrome. Results of a pilot study utilizing a multiagent treatment protocol. *J Pediatr Hematol Oncol* 1995;17:290-295.
- Ng SC. Evans syndrome: a report on 12 patients. *Clin Lab Haematol* 1992;14: 189-193.