

## LETTERS AND CORRESPONDENCE

Letters and correspondence submitted for possible publication must be identified as such. Text length must not exceed 500 words and five bibliographic references. A single concise figure or table may be included if it is essential to support the communication. Letters not typed double-spaced will not be considered for publication. Letters not meeting these specifications will not be returned to authors. Letters to the Editor are utilized to communicate a single novel observation or finding. Correspondence is to be used to supplement or constructively comment on the contents of a publication in the journal and cannot exceed the restrictions for Letters to the Editor. The Editor reserves the right to shorten text, delete objectionable comments, and make other changes to comply with the style of the journal. Permission for publication must be appended as a postscript. Submissions must be sent to Jay Umbreit, MD, PhD, Editor of Brief Reports/Letters to Editors, American Journal of Hematology, Winship Cancer Institute, Emory University, 1365-B Clifton Road, Suite B4100, Atlanta, GA 30322 to permit rapid consideration for publication.

immaturity of the fetal immune system. Anamnestic response may be induced by infection, malignancy, or pregnancy later in life. Significantly, the mothers of two female patients (including our patient) whose blood group was known were Rh-positive. However, the development of anti-D alloantibodies (albeit detected by autoanalyzer) in individuals whose mothers are also Rh-negative argues against this method as the sole mechanism [1]. Either mechanism is applicable to our patient. Despite the pill and regular periods, she may have become pregnant and spontaneously miscarried without being aware of either event since about a fifth of all pregnancies end this way [4]. Alloimmunization resulting from this has not been previously reported. Also, her partner is statistically likely to be Rh-positive. Although fetal red cells may express the D antigen by day 36 [5], evidence for alloimmunization following first-trimester miscarriage is weak. Lastly, exposure to an unidentified antigen similar to the Rh(D) antigen may result in alloimmunization.

GANESH C. KUDVA<sup>1</sup>  
KENT D. BRANSON<sup>2</sup>  
BRENDA J. GROSSMAN<sup>3</sup>

<sup>1</sup> Department of Internal Medicine, Saint Louis University School of Medicine, St. Louis, Missouri

<sup>2</sup> Obstetrician and Gynecologist, St. Louis, Missouri

<sup>3</sup> Department of Pathology, Saint Louis University School of Medicine, St. Louis, Missouri

Published online in Wiley InterScience (www.interscience.wiley.com).  
DOI: 10.1002/ajh.20484

### Rh(D) Alloimmunization Without Apparent Exposure to Rh(D) Antigen

*To the Editor:* Naturally occurring alloantibodies to Rh(D) antigen detected only by autoanalyzer are present in 3% of the Rh-negative population [1]. Their significance is unclear as their presence neither predicts nor precludes the development of manually detectable anti-D [1]. Alloantibodies to Rh(D) antigen detected by manual techniques are not generally known to occur without exposure to red cells carrying the D antigen. Only five cases have been described in the literature [2,3]. We report a sixth instance.

A healthy 26-year-old Caucasian woman with O-negative blood group (weak D negative) was found to have anti-D (IgG) by manual techniques during blood donation and confirmed at evaluation 2 months later. The antibody was absent at a previous donation 10 months ago. She was on birth control pills and menstruating regularly. Although sexually active, she was never known to be pregnant. She received no blood transfusions and denied intravenous drug use. There was no history of intravenous immunoglobulin or anti-D injections.

The occurrence of anti-D detected by manual methods in Rh-negative individuals who have never been pregnant or transfused Rh-positive red cells is rare. Alloimmunization following intravenous drug use with shared needles is infrequent. Administration of intravenous immunoglobulin or anti-D may result in the transient presence of anti-D in the serum. Of 6 patients (including our patient) in whom none of the above causes were present, 4 were women. In one woman, anti-D appeared in the third trimester of a pregnancy with an Rh(D) negative baby [2]. She also developed weak anti-E. Another was a 24-year-old woman pregnant with an Rh-negative baby [2]. The husband and two children of a third woman with anti-D were Rh-negative [2]. One of the two male patients was a 6-year-old boy with nephrotic syndrome [2]; the other, a 54-year-old man with bronchopneumonia and metastatic mucinous adenocarcinoma (primary unknown) of the thigh, with anti-D, anti-K, anti-Fy<sup>a</sup>, and anti-Le<sup>ab</sup> and no history of blood transfusion [3].

Anti-D in men excludes occult pregnancy followed by undetected abortion as the only explanation for this phenomenon. Another hypothesis is the transfer of Rh-positive red cells from the mother to an Rh-negative fetus resulting in alloimmunization (the grandmother theory) [2] despite the

### REFERENCES

- Contreras M, de Silva M, Teesdale P, Mollison PL. The effect of naturally occurring Rh antibodies on the survival of serologically incompatible red cells. *Br J Haematol* 1987;65:475–478.
- Biggins KR, Bowman JM. Rh(D) alloimmunization in the absence of exposure to Rh(D) antigen. *Vox Sang* 1986;51:228–230.
- Algora M, Barbolla L, Contreras M. Naturally occurring anti-D, anti-K, anti-Fy<sup>a</sup>, and anti-Le<sup>ab</sup>. *Vox Sang* 1991;61:141.
- Wilcox AJ, Weinberg CR, O'Connor JF, et al. Incidence of early loss of pregnancy. *N Engl J Med* 1988;319:189–194.
- Avent ND, Reid ME. The Rh blood group system: a review. *Blood* 2000;95:375–387.

### Combination Therapy With rFVIIa and Platelets for Hemorrhage in Patients With Severe Thrombocytopenia and Alloimmunization

*To the Editor:* Recombinant factor VIIa (rFVIIa) is approved in the U.S. for treatment of bleeding in hemophiliacs with inhibitors. It has also been used in a small number of patients with severe thrombocytopenia who were refractory to platelets [1], but its efficacy has not been well established in this setting. We cared for 2 patients with life-threatening bleeding, thrombocytopenia, and platelet refractoriness who had dramatic clinical responses to the combination of platelet transfusions and a single dose of rFVIIa.

Patient 1 is 61-year-old male with severe aplastic anemia (SAA) who was refractory to platelet transfusions due to severe alloimmunization. He developed sudden, acute, severe gastrointestinal bleeding and hypotension, losing more than 500 mL of bright red blood per rectum (BRBPR). His platelet count was 2000/μL. He received 7 units of PRBC, 36 units of

platelets, and aminocaproic acid intravenously for the first 32 hr without response. He was given rFVIIa (70 µg/kg) IV push over 5 min immediately following 4 units of platelets. The active BRBPR stopped within minutes, and melena subsided over 3 days despite continued platelet counts of 1–3000/µL.

Patient 2 is 22-year-old male with SAA who presented with severe GI bleeding (loss of more than 1 L in 24 hr). His platelet counts were 1–5000/µL despite aggressive platelet support, and he also had severe platelet alloimmunization. He received 8 units of PRBC, 28 units of platelets, and aminocaproic acid for over 24 hr without response. The patient then received 6 units of platelets immediately followed by rFVIIa, 80 µg/kg IV. The bleeding stopped within minutes despite continued thrombocytopenia.

These cases of successful treatment with single-infusion rFVII given immediately following platelet transfusion for bleeding in patients with severe thrombocytopenia suggest that rFVIIa may be more effective when combined temporally with platelet transfusion. Prior case reports describe the use of high-dose rFVIIa in patients with severe thrombocytopenia but do not discuss the timing of platelet transfusions [2,3]. In one study [4], single infusions of rFVIIa (50 or 100 µg/kg) were administered to 8 patients with thrombocytopenia (3 with platelets ≤10/µL; 3 with 11–20/µL; and 2 with >20,000/µL) during 10 episodes of mild-to-moderate bleeding. Bleeding stopped in 7 episodes and slowed in 3 instances. These authors also demonstrated shortening of the bleeding time. The optimal dose of rFVIIa in the context of thrombocytopenia is unknown [2,3,5].

In cell-based models of thrombocytopenia, it has been shown that thrombin generation is dependent on platelets and that, with severe thrombocytopenia, rFVIIa does not maximize peak thrombin generation [5]. It is possible that giving platelet transfusions with rFVIIa may optimize thrombin generation to control bleeding. Smaller doses of rFVIIa may be effective in thrombocytopenic patients when used in combination with platelet transfusion, and rFVIIa may reduce the need for HLA-matched platelets in thrombocytopenic patients with life-threatening bleeding.

BIPIN N. SAVANI<sup>1</sup>  
 CYNTHIA E. DUNBAR<sup>1</sup>  
 MARGARET E. RICK<sup>2</sup>

<sup>1</sup>Hematology Branch, National Heart, Lung and Blood Institute, National Institutes of Health, Bethesda, Maryland

<sup>2</sup>Hematology Service, Clinical Center, National Institutes of Health, Bethesda, Maryland

Published online in Wiley InterScience (www.interscience.wiley.com). DOI: 10.1002/ajh.20506

REFERENCES

- Goodnough LT. Experiences with recombinant human factor VIIa in patients with thrombocytopenia. *Semin Hematol* 2004;41:25–29.
- Culligan DJ, Salamat A, Tait J, Westland G, Watson HG. Use of recombinant factor VIIa in life-threatening bleeding following autologous peripheral blood stem cell transplantation complicated by platelet refractoriness. *Bone Marrow Transplant* 2003;31:1183–1184.
- Gerotziapas GT, Zervas C, Gavriellidis G, et al. Effective hemostasis with rFVIIa treatment in two patients with severe thrombocytopenia and life-threatening hemorrhage. *Am J Hematol* 2002;69:219–222.
- Kristensen J, Killander A, Hippe E, et al. Clinical experience with recombinant factor VIIa in patients with thrombocytopenia. *Haemostasis* 1996;26(Suppl 1):159–164.
- Kjalke M, Ezban M, Monroe DM, Hoffman M, Roberts HR, Hedner U. High-dose factor VIIa increases initial thrombin generation and mediates faster platelet activation in thrombocytopenia-like conditions in a cell-based model system. *Br J Haematol* 2001;114:114–120.

Is the Group of Older Sickle Cell Disease Patients From Trinidad and Tobago Different?

To the Editor: I read with interest the article on older sickle cell disease (SCD) patients [1], as their numbers are increasing in our outpatient department. Clinical and laboratory assessments from 32 of the patients in our clinic with SS phenotype and who were over 40 years of age were analyzed. The mean age was 48.87 (40–66) years; 21 (62.62%) patients were female and 11 (34.37%) were male. The mean age at diagnosis was 11.33 (0–34) years; in 15 (46.87%) patients, it was made at 10 years of age or younger, in 8 (25%) from 11 to 20 years, and in 4 (12.5%) when the patients were older than 20 years of age. The most frequent initial presentation was acute painful crisis (APC) in 15 (46.87%) patients, followed by screening of the family in 3 (9.37%) cases, pregnancy in 2 (6.25%) cases, stroke in 2 (6.25%) cases, and jaundice and leg ulceration in 1 (3.12%) patient each one. Data on age at diagnosis and initial presentation were not available in 5 (15.62%) and 9 (28.12%) patients respectively.

The clinical picture was not severe in any of the patients; 23 (71.87%) of them have not suffered APC in the last 2 years, and the others have experienced 3 or fewer episodes over the same period. Regarding acute events, acute chest syndrome in 9 (28.12%) patients, hepatic crisis in 6 (18.75%), and central nervous system crisis in 4 (12.5%) were the most common. The most frequent chronic complications were leg ulceration in 19 patients (59.37%), chronic renal failure in 6 (18.75%), and avascular necrosis in 6 (18.75%). No patients required blood transfusions and only 5 (15.62%) needed treatment with hydroxyurea.

The data of McKerrell in the Bronx of New York (Group I) are compared to ours (Group II) in Table I. Clinical determinants show differences between both groups. Weight and blood pressure (BP) were lower in Group II. BP in older SCD patients did not demonstrate the expected rise with advancing age. This was more evident in Group II. It is not yet known whether this factor is associated with long survival in SCD [2].

The number of crises during the last 2 years was significantly lower in the Trinidadian group. Many patients in the group from Trinidad and Tobago had zero crises in that time frame [3].

The hematological determinants, except the mean cell hemoglobin concentration (MCHC) with minimal difference, were lower in Group II. There was no significant difference but the decreased hematopoietic poten-

TABLE I. Clinical and laboratory Determinants of Older SCD Patients: Bronx, NY, Versus Trinidad and Tobago\*

Determinant	Group I	n	Group II	n	p
Weight (kg)	68.7 ± 9.9	23	60.7 ± 8.8	32	0.002 <sup>a</sup>
SBP (mmHg)	124.7 ± 20.6	35	108.4 ± 13.6	32	0.000 <sup>a</sup>
DBP (mmHg)	69.9 ± 12.1	35	60.8 ± 8.3	32	0.000 <sup>a</sup>
Crisis (2 years, n)	10.6 ± 21.3	40	1.13 ± 1.6	32	0.014 <sup>a</sup>
Hgb (g/dL)	7.8 ± 1.4	40	7.3 ± 1.6	32	0.16
MCV (fL)	86.9 ± 9.3	40	82.7 ± 9.7	32	0.06
MCHC (g/dL)	34.6 ± 1.7	40	35.1 ± 2.9	32	0.36
WBC (×10 <sup>9</sup> /L)	11.0 ± 3.2	40	10.0 ± 2.8	32	0.16
ANC (×10 <sup>9</sup> /L)	6.1 ± 3.0	39	5.4 ± 2.2	32	0.27
ALC (×10 <sup>9</sup> /L)	3.6 ± 1.8	39	3.3 ± 1.1	32	0.41
Plt (×10 <sup>9</sup> /L)	342.4 ± 106.7	40	333.1 ± 154.4	32	0.76
BUN (mg/dL)	15.4 ± 12.7	38	14.9 ± 11.5	32	0.86
Cre (mg/dL)	1.3 ± 1.5	39	1.05 ± 0.7	32	0.39
ALP (IU/L)	169.9 ± 259	38	203 ± 78.2	31	0.48
ALT (IU/L)	22.4 ± 8.9	38	20.9 ± 11.3	23	0.56
IB (mg/dL)	2.4 ± 1.8	39	2.7 ± 1.8	32	0.48
DB (mg/dL)	0.6 ± 0.4	37	0.64 ± 0.41	32	0.68

\*Group I, Patients from Bronx, NY; Group II, Patients from Trinidad and Tobago.  
<sup>a</sup>P < 0.05.

tial was more evident in this group. It may represent a secondary survival benefit effect, and it should be elucidated [4].

There was no significant difference between the hepatorenal characteristics, although alkaline phosphatase (ALP) values were higher in the Trinidadian group and above normal in the New York group. This may be secondary to bone complications that usually occur at this age [1,5].

Slaves were transported to Trinidad and Tobago from various locations in Africa. The genetic characteristics in our patient group may determine a mild clinical picture, but other factors may play a role in the prolonged survival of these patients that are different from the New York group.

**RAFAEL LOSADA**<sup>1,2,3</sup>  
**IDANIA BRAVO**<sup>4,5</sup>  
**KAVI CAPILDEO**<sup>1</sup>  
**KENNETH CHARLES**<sup>1</sup>

<sup>1</sup> Department of Pathology, Port of Spain General Hospital, Trinidad and Tobago

<sup>2</sup> Institute of Hematology and Immunology, Havana City, Cuba

<sup>3</sup> Superior Institute of Medical Sciences, Havana City, Cuba

<sup>4</sup> National Radiotherapy Centre, St. James, Port of Spain, Trinidad and Tobago

<sup>5</sup> Provincial Oncology Hospital, Pinar del Rio, Cuba

Published online in Wiley InterScience (www.interscience.wiley.com).

DOI: 10.1002/ajh.20505

## REFERENCES

1. McKerrill TD, Cohen HW, Billet HH. The older sickle cell patient. *Am J Hematol* 2004;76:101–106.
2. Johnson CS, Giorgio AJ. Arterial blood pressure in adults with sickle cell disease. *Arch Intern Med* 1981;141:891–893.
3. Serveant GR. Sickle cell disease. *Lancet* 1997;350:725–730.
4. Morris J, Dunn D, Beckford M, et al. The haematology of homozygous SCD after the age of 40 years. *Br J Haematol* 1991;77:382–385.
5. Richard S, Billett HH. Liver function tests in sickle cell disease. *Clin Lab Haematol* 2002;24:21–27.

## 23-bp Endothelial Protein C Receptor (EPCR) Gene Insertion Mutation in Cancer Patients With and Without Thrombosis

*To the Editor:* Protein C binding to endothelial protein C receptor (EPCR) promotes protein C activation by increasing the catalytic efficiency of the thrombin–thrombomodulin complex [1]. Any defect within the EPCR gene that leads to reduced receptor expression or impaired receptor function may stimulate the development of thrombosis. The human EPCR gene is composed of four exons and three introns. A 23-bp insertion at position 4031 of the EPCR gene results in an early stop codon six codons downstream from the insertion point [2]. This mutation may lead to the development of venous thrombosis and arterial occlusive diseases [3]. However, the EPCR 23-bp insertion was not found to be a risk factor for thrombosis in some studies [4,5]. We determined the prevalence of the 23-bp insertion mutation in adult cancer patients with and without thromboembolism (TE).

The study group (group I) consisted of 26 cancer patients who developed TE during cancer treatment, e.g., surgery, radiotherapy, or chemotherapy. The control group (group II) was composed of 59 cancer patients who had not experienced known thrombotic complications during the therapy. All patients were evaluated for the presence of symptoms and signs of deep venous thrombosis (DVT). Diagnosis of DVT was based on color Doppler ultrasonography in addition to clinical signs and physical examination. All

patients had neither family history for hypercoagulability nor previous individual history of TE.

DNA was extracted by conventional methods and polymerase chain reaction of the exon III of the EPCR gene was performed according to previously described methods using primers 5'-ACACCTGGCACCCTCTCT-3' and 5'-CATCCTCAGGTCCATCC-3' [2,9]. Amplification was performed for 30 cycles with an annealing temperature of 58°C (Biometra, Göttingen, Germany). Amplified DNA was subjected to 2.5% agarose gel electrophoresis.

The insertion was not detected among the 26 cancer patients with thrombosis. Among the 59 control patients, only one patient (1.7%) was identified who was heterozygous for the 23-bp insertion. All patients were also evaluated for factor V Leiden (FVL) and prothrombin (PT) G20210A mutations. The patient heterozygous for the 23-bp insertion did not carry the FVL or the PT G20210A mutation. However, the FVL mutation was present in seven (26.9%) out of 26 patients in study group.

Wermes et al. investigated the role of the 23-bp insertion in pediatric cancer patients with thrombosis [5]. In this German study, the insertion mutation was not found among the children with cancer who had thrombosis. Although the number of patients studied was small, it is difficult to suggest a role on the pathogenesis of cancer patients with TE, and screening for the EPCR insertion allele in cancer patients with TE may not be warranted.

**AYDAN EROĞLU**<sup>1</sup>  
**ARZU ULU**<sup>2</sup>  
**CENGİZ KURTMAN**<sup>3</sup>  
**RAGİP ÇAM**<sup>4</sup>  
**NEJAT AKAR**<sup>2</sup>

<sup>1</sup> Department of Surgery, Numune State Hospital, Selçuklu, Konya, Turkey

<sup>2</sup> Department of Pediatric Molecular Genetic, Ankara University Medical School, Cebeci, Ankara, Turkey

<sup>3</sup> Department of Radiation Oncology, Ankara University Medical School, Cebeci, Ankara, Turkey

<sup>4</sup> Department of Surgery, Ankara University Medical School, Cebeci, Ankara, Turkey

Published online in Wiley InterScience (www.interscience.wiley.com).

DOI: 10.1002/ajh.20519

## REFERENCES

1. Esmon CT. The endothelial cell protein C receptor. *Thromb Haemost* 2000; 83: 639–643.
2. Simmonds RE, Lane DA. Structural and functional implications of the intron/exon organisation of the human endothelial cell protein C/activated protein C receptor (EPCR) gene: comparison with the structure of CD1/major histocompatibility complex  $\alpha 1$  and  $\alpha 2$  domains. *Blood* 1999;94:632–641.
3. Merati G, Biguzzi E, Oganeyson N, et al. A 23bp insertion in the endothelial protein C (EPCR) gene in patients with myocardial infarction and deep venous thrombosis. *Thromb Haemost Suppl* 1999;507.
4. Galligan L, Livingstone WJ, Mynett-Johnson L, Smith OP. Prevalence of a 23bp endothelial protein C receptor gene insertion in the Irish population. *Thromb Haemost Suppl* 2001;2220.
5. Wermes C, Czwalinna A, Sykora KW, et al. Role of a 23 bp insertion in the endothelial protein C receptor (EPCR) gene in thrombogenesis in children with cancer. *Haemostasis* 2000;30:17.

## Acute Tumor Lysis Syndrome Secondary to Hydroxycarbamide in Chronic Myelomonocytic Leukemia

*To the Editor:* Acute tumor lysis syndrome (ATLS) is a catastrophic complication that usually follows chemotherapy treatment of myelolymphoproliferative diseases. It results from massive tumor cell destruction

that occurs secondary to chemotherapy, and it manifests from few hours to a few days after initiation of treatment [1]. We report a case of ATLS complicating hydroxycarbamide (hydroxyurea) therapy for chronic myelomonocytic leukemia (CMML).

Our patient is a 61-year-old man who presented to an outside hospital with a 5-month history of headache, fatigue, and episodic nose bleeding. He reported weight loss of 16 kg over the same period. Physical examination revealed mild generalized abdominal tenderness with hepatosplenomegaly. His laboratories showed a WBC count of 62,900/mm<sup>3</sup>, hemoglobin 7.7 g/dL, hematocrit 23%, platelets 74,000/mm<sup>3</sup>, differential: neutrophils, 31%; lymphocytes, 12%; monocytes, 46%; promyelocytes, 7%; metamyelocytes, 1%; myelocytes, 3%. The patient received a transfusion of red blood cells. Molecular testing for t(9,11), inv(16), t(15,17), t(8,21), and t(9,22) was negative. Flow cytometry revealed a mixture of maturing granulocytic elements as well as lymphocytes and a large population of monocytes. The monocytic cells were positive for CD13, CD33, CD14, and HLA-DR. He had 46XY karyotype with del(12)(p11.2; p12.1). The patient was diagnosed with CMML.

The patient was given iv hydration, allopurinol (300 mg po daily), and was started on hydroxycarbamide 1,500 mg daily. His baseline creatinine was 0.7 mg/dL (reference range: 0.6–1.2 mg/dL). The patient remained asymptomatic. Repeated studies done on the 2<sup>nd</sup> day of treatment showed elevation in creatinine, phosphorous, and lactate dehydrogenase (LDH) (Fig. 1). Review of systems was negative, and the physical examination was unremarkable. He was given aggressive intravenous hydration with an alkaline solution. Over the next few days, his biochemistry improved. The hydroxycarbamide was continued, and he was discharged 10 days later in stable condition with a creatinine of 0.9 mg/dL.

Chronic myelomonocytic leukemia (CMML) is a hematologic malignancy characterized by wide heterogeneity of clinical presentation and course. CMML shares myelodysplastic characteristics with features of myeloproliferative disorders [2]. ATLS is most commonly associated with Burkitt and other high-grade non-Hodgkin lymphomas and acute leukemias [3,4]. Patients who are at risk for ATLS should, when possible, be well hydrated and be given sodium bicarbonate to alkalize the urine and allopurinol prior to initiation of chemotherapy. If ATLS occurs, treatment consists of hydration and management of electrolytes and metabolic abnormalities with dextrose, insulin, Kayexalate (sodium polystyrene sulfonate), and, sometimes, hemodialysis [5].

In our patient, there was no evidence of ATLS prior to the start of hydroxycarbamide therapy and it would be appropriate to assume that it was the cause. His biochemical parameters were normal before hydroxycarbamide, but within 24 hr, he developed ATLS. Our review of the medical literature revealed no previously reported cases of ATLS induced by hydroxycarbamide in CMML. This case demonstrates that ATLS can

occasionally occur in the setting of minimally cytotoxic therapy in CMML patients and highlights the importance of close monitoring for the biochemical parameters in such patients.

ZAHER K. OTROCK<sup>1</sup>  
 ALI T. TAHER<sup>1</sup>  
 RAMI A.R. MAHFOUZ<sup>2</sup>  
 JAWAD A. MAKAREM<sup>1</sup>  
 ALI I. SHAMSEDDINE<sup>1</sup>

<sup>1</sup> Department of Internal Medicine, American University of Beirut Medical Center, Beirut, Lebanon

<sup>2</sup> Department of Pathology and Laboratory Medicine, American University of Beirut Medical Center, Beirut, Lebanon  
 Published online in Wiley InterScience (www.interscience.wiley.com).  
 DOI: 10.1002/ajh.20497

REFERENCES

- Chasty RC, Liu-Yin JA. Acute tumour lysis syndrome. *Br J Hosp Med* 1993;49:488–492.
- Onida F, Kantarjian HM, Smith TL, et al. Prognostic factors and scoring systems in chronic myelomonocytic leukemia: a retrospective analysis of 213 patients. *Blood* 2002;99:840–849.
- Hande KR, Garrow GC. Acute tumor lysis syndrome in patients with high-grade non-Hodgkin's lymphoma. *Am J Med* 1993;94:133–139.
- Razis E, Arlin ZA, Ahmed T, et al. Incidence and treatment of tumor lysis syndrome in patients with acute leukemia. *Acta Haematol* 1994;91:171–174.
- Sullan S. Management of acute tumor lysis syndrome. *Semin Oncol* 2001;28(2 Suppl 5):9–12.

GVHD and Prognostic Factors

*To the Editor:* In their recent paper, Pavletic et al. [1] report on prognostic factors of chronic graft-versus-host disease (cGVHD) after allogeneic peripheral-blood stem-cell transplantation (PBSCT). The incidences of overall and extensive types of cGVHD were 76% and 64%, respectively. They found that different prognostic factors could be identified for the development of cGVHD after PBSCT and bone marrow stem-cell transplantation (BMSCT). They also describe a negative impact of cGVHD on survival, except for oral and skin localizations, which were found to be associated with a better outcome, but they were unable to find a satisfactory explanation for this finding, also in view of the fact that extensive cGVHD did not predict for poor survival. Based on our experience, we suggest these results could be due to the high proportion of severe-extensive cGVHD observed in the study, which affected more transplant related mortality (TRM) than did relapse and obscured the protective effect of limited GVHD. In fact, between 1995 and 2002, we consecutively transplanted 104 patients with hematological malignancies from a fully HLA-identical sibling after myeloablative conditioning (TBI based, 34 patients; busulfan based, 70 patients) with PBSC; the GVHD prophylaxis was homogeneous with cyclosporin A (CsA) and 4 doses of methotrexate (MTX). The median age was 41 years (range, 18–56 years), 43 had acute leukemia or MDS, 32 had myeloma, 20 had CML, 8 had lymphoma, and 1 had idiopathic myelofibrosis; 40/104 (38.5%) had advanced disease. The overall incidence of cGVHD was 62%; it was mainly extensive, and in 78% it had worsened or remained stable over the years. We used the usual classification of limited and extensive type [2], but we also subgrouped the latter into moderate or severe according to clinical severity (>4 organs involved and/or Karnofsky index <70%).

Considering all patients together, a survival advantage was observed only with the limited form of cGVHD compared to no GVHD or exten-

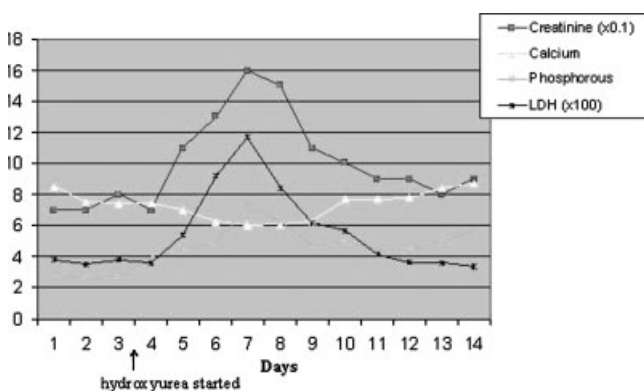
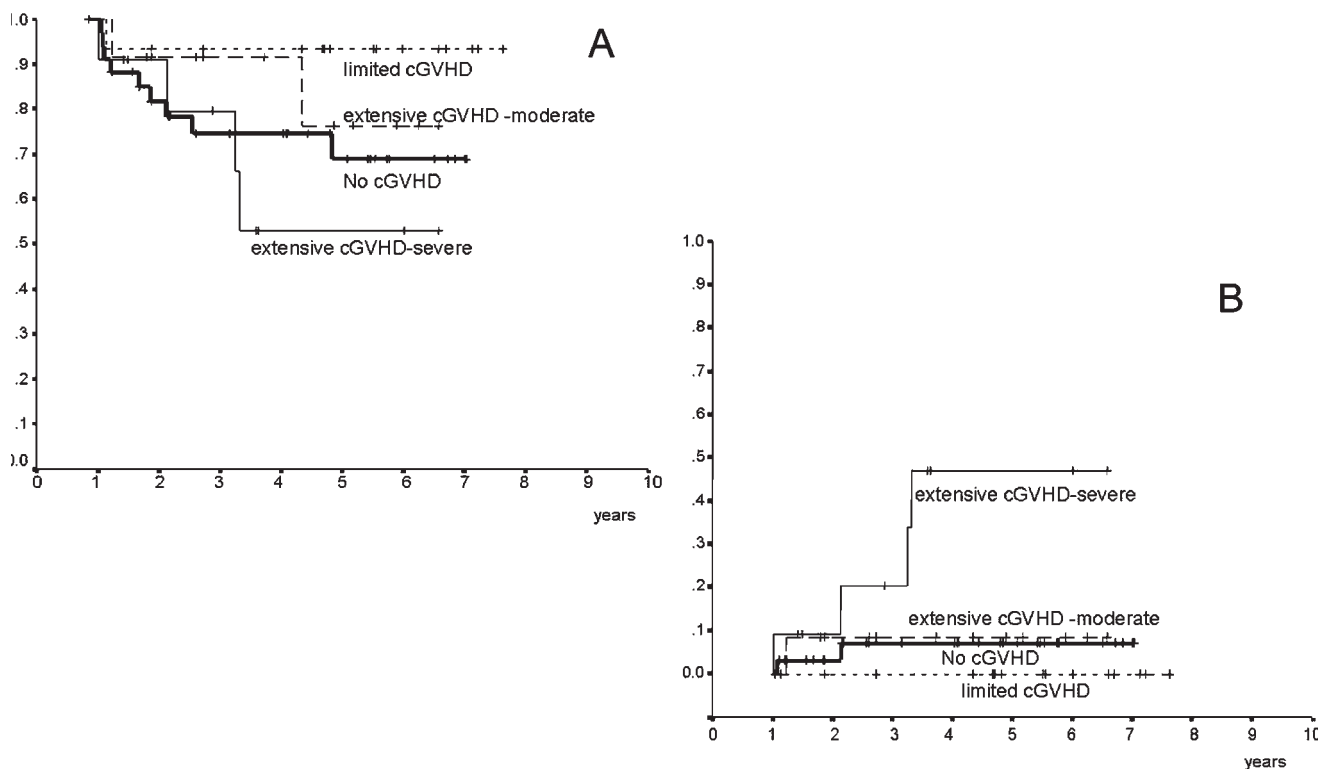


Fig. 1. Simultaneous and sequential changes in serum chemistries reflecting tumor lysis syndrome after hydroxyurea administration. [Color figure can be viewed in the online issue, which is available at www.interscience.wiley.com.]





**Fig. 1. (A) Overall survival according to cGVHD (landmark analysis). cGVHD has been classified as limited and extensive. This has been further subdivided into moderate or severe (>4 organs involved and/or a Karnofsky index <70%). (B) Transplant-related mortality (TRM). The overall probability of TRM is 25.7% for the entire population. Extensive-severe cGVHD significantly increased the risk of TRM ( $P = 0.01$ ), compared to limited, extensive-moderate, or no GVHD.**

sive-moderate cGVHD. On the contrary, the extensive-severe form was associated with the poorest survival (Fig. 1). cGVHD affected TRM (Fig. 1) but not the relapse probability, which was influenced only by the stage of disease at transplant (data not shown).

Our hypothesis is that, because the beneficial effect of cGVHD is probably restricted to the limited form only [3,4], the positive effect of skin and oral cGVHD could be that such manifestations very likely contributed to the limited form or at least a moderate form of extensive cGVHD not requiring systemic immunosuppression and thus not affecting TRM. Even if neither current cGVHD classifications nor prognostic models are satisfactory [5], and detailed data on clinical cGVHD manifestations are often lacking in most studies, as correctly underlined by Pavletic et al., the high rates of extensive cGVHD after PBSTs are detrimental on transplant outcome.

FRANCESCA BONIFAZI  
GIUSEPPE BANDINI  
MADDALENA GIOVANNINI  
SADIA FALCIONI  
MICHELE BACCARANI

<sup>1</sup> Institute of Hematology and Clinical Oncology "L. and A. Seragnoli," S. Orsola-Malpighi Hospital, University of Bologna, Bologna, Italy  
Published online in Wiley InterScience (www.interscience.wiley.com).  
DOI: 10.1002/ajh.20491

#### REFERENCES

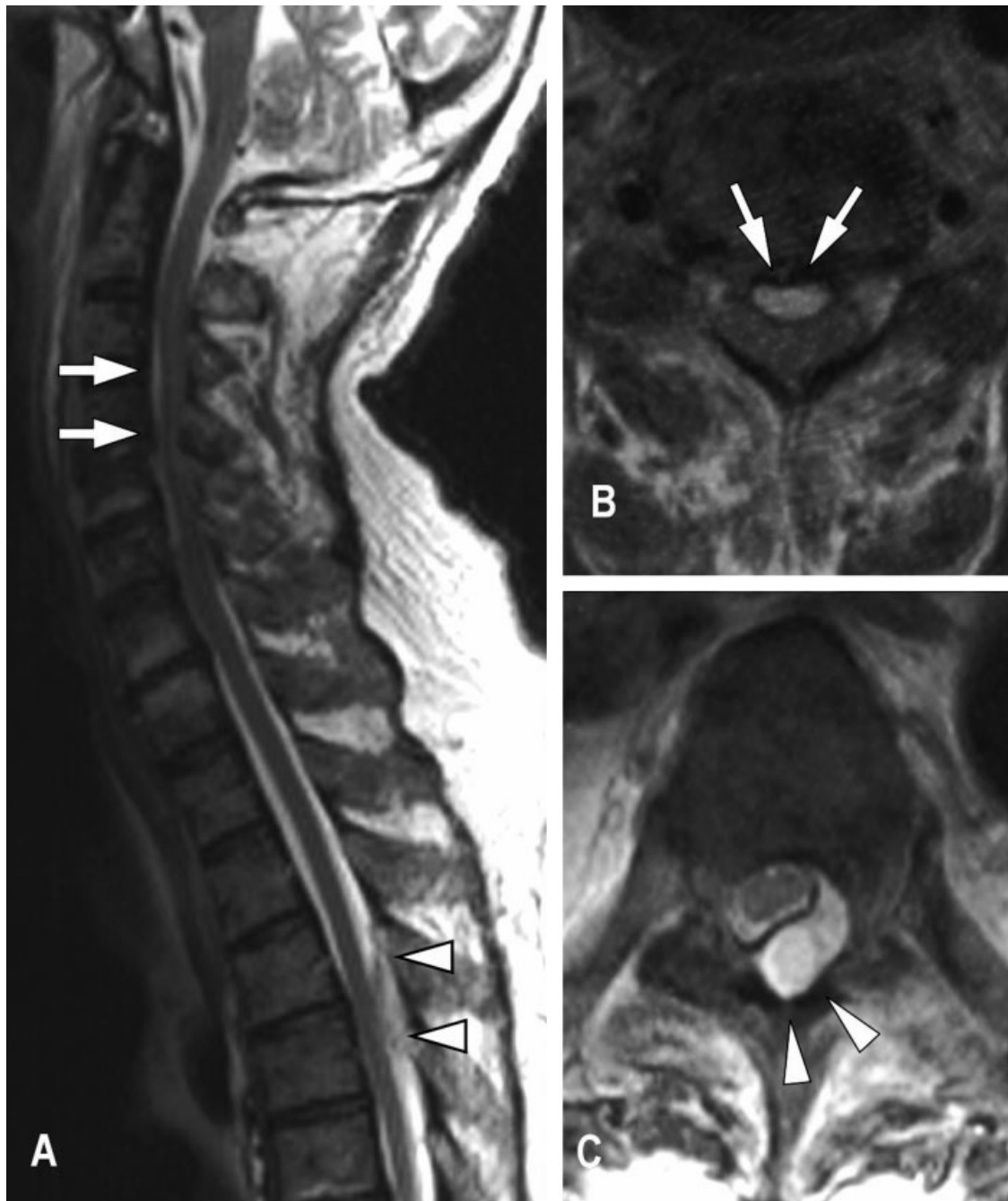- Pavletic SZ, Smith LM, Bishop MR, et al. Prognostic factors of chronic graft-versus-host disease after allogeneic blood stem-cell transplantation. *Am J Hematol* 2005;78:265-274.

- Shulman HM, Sullivan KM, Weiden PM, et al. Chronic graft-versus-host syndrome in man: a long-term clinicopathologic study of 20 Seattle patients. *Am J Med* 1980;69:204-217.
- Lee SJ, Klein JP, Barnett AJ, et al. Severity of chronic graft-versus-host disease: association with treatment-related mortality and relapse. *Blood* 2002;100:406-414.
- Gratwohl A, Brand R, Apperley J, et al. Graft-versus-host disease and outcome in HLA-identical sibling transplantations for chronic myeloid leukemia. *Blood* 2002;100:3877-3886.
- Lee SJ, Vogelsang G, Flowers MED. Chronic graft-versus-host disease. *Biol Blood Marrow Transplant* 2003;9:215-233.

#### Exacerbation of Chronic Epidural Abscess Following a Fludarabine-Based Preparative Regimen

*To the Editor:* A spinal epidural abscess (SEA) is an infection in the epidural space. *Staphylococcus aureus* is the causative pathogen in 57-73% of the cases [1]. The prognosis is good with appropriate treatment; 70% of the patients recover without neurological sequelae while some survive with neurological deficits, and 15% of the patients die. Without risk factors, such as diabetes mellitus and chronic renal failure, an epidural abscess developed in association with epidural catheters and trauma [1].

A 57-year-old man with transfusion-dependent aplastic anemia who had not responded to immunosuppressive therapy was transferred to Toranomon Hospital in May 2004. Physical examination was normal except for several months of mild posterior neck pain without tenderness, which had been diagnosed as spondylosis. Routine surveillance culture detected colonization of methicillin-resistant *S. aureus* (MRSA) in the nasal cavity. He underwent reduced-intensity stem-cell transplantation (RIST) from a one-allele-mismatched unrelated donor. The preparative regimen comprised fludarabine



**Fig. 1.** Magnetic resonance imaging (MRI) of the spine. (A) T2-weighted MRI of the sagittal cervical and thoracic spine showing an anterior epidural abscess at C 3–5 (arrows) and a posterior epidural abscess at Th 4–5 (arrow heads). (B) T2-weighted axial view showing a high-intensity occupying lesion in the anterior subdural space at C 3–5 (arrow). (C) T2-weighted axial view showing a high-intensity occupying posterior lesion at Th 4–5 (arrow heads).

30 mg/m<sup>2</sup> for 6 days, busulfan 4 mg/kg for 2 days, and total body irradiation (TBI) of 4 Gy. Graft-versus-host disease prophylaxis was tacrolimus 0.03 mg/kg and methotrexate. On the third day of fludarabine administration (day –6), the neck pain became continuous and spread to the lower back. On day –1, a high-grade fever developed. We initiated treatment with ceftazidime and added vancomycin on day 1 based on blood culture showing MRSA. The posterior neck pain worsened, with the patient developing neck stiffness and tenderness on day 4. The fever persisted despite engraftment on day 12. He complained of urinary incontinence and muscle weakness of the extremities in

the morning on day 14, and 11 hr later, the weakness progressed to tetraplegia and acute respiratory failure requiring intubation. Magnetic resonance imaging (MRI) of the cervical and thoracic spine showed the spinal canal to be compressed by an SEA (Fig. 1). He underwent emergent laminectomy, and pus was shown in both lesions, for which local drainages were placed. On pathological examination, the cervical lesion consisted mostly of fibrous tissues, while fibrous changes were not detected in the thoracic lesion. Cultures of the pus revealed MRSA. His neurological symptoms did not improve after laminectomy. MRI of the cervical spine on day 20 showed expansion of

an epidural abscess. Linezolid was started on day 20. The fever gradually resolved by day 40. As of August 2004, he is alive with mild motor and sensory deficits.

The risk of bacterial infection remains to be elucidated in RIST [2]; however, this case suggests that the fludarabine-based regimen might have exacerbated chronic SEA. The mild neck pain had been stable for several months, but it worsened 2 days after infusion of fludarabine, before administration of busulfan and TBI. The fact that the cervical lesion was more fibrous than the thoracic one indicates that the former was older than latter. The chronic cervical SEA was likely to be the primary infectious site, which spread hematogenously to the thoracic area. Considering that neutrophils primarily defend against *S. aureus* [3] and that fludarabine has a considerable myelosuppressive property [4], we should recognize the risk of exacerbation of SEA when treating patients with chronic back pain using fludarabine-containing regimens.

YUJI MIURA<sup>1</sup>  
MASAHIRO KAMI<sup>2</sup>  
EJI KUSUMI<sup>1</sup>  
NAOKO MURASHIGE<sup>2</sup>  
KAZUHIRO MASUOKA<sup>1</sup>  
MADOKA YOSHIMURA<sup>3</sup>  
SHINTARO TACHIBANA<sup>4</sup>  
SHUICHI TANIGUCHI<sup>1</sup>

<sup>1</sup> Department of Hematology, Toranomon Hospital, Tokyo, Japan

<sup>2</sup> Hematopoietic Stem Cell Transplantation Unit, National Cancer Center Hospital, Tokyo, Japan

<sup>3</sup> Department of Neurology, Toranomon Hospital, Tokyo, Japan

<sup>4</sup> Department of Orthopedics, Toranomon Hospital, Tokyo, Japan

Published online in Wiley InterScience (www.interscience.wiley.com).

DOI: 10.1002/ajh.20527

## REFERENCES

1. Baker AS, Ojemann RG, Swartz MN, Richardson EP Jr. Spinal epidural abscess. *N Engl J Med* 1975;293(10):463–468.
2. Hori A, Kami M, Kim SW, et al. Development of early neutropenic fever, with or without bacterial infection, is still a significant complication after reduced-intensity stem cell transplantation. *Biol Blood Marrow Transplant* 2004;10(1):65–72.
3. Lowy FD. *Staphylococcus aureus* infections. *N Engl J Med* 1998;339(8):520–532.
4. Wright SJ, Robertson LE, O'Brien S, Plunkett W, Keating MJ. The role of fludarabine in hematological malignancies. *Blood Rev* 1994;8(3):125–134.

## Severe Thrombotic Thrombocytopenic Purpura (TTP) Induced or Exacerbated by the Immunostimulatory Herb *Echinacea*

*To the Editor:* Thrombotic thrombocytopenic purpura (TTP) is a fulminant, often lethal, disorder that may be initiated by endothelial injury or overactivation and subsequent release of von Willebrand factor and other procoagulant materials from endothelial cells.

We present a case of severe TTP in an otherwise healthy 32-year-old Caucasian man. The patient reported that almost 20 days before, he had symptoms of upper respiratory tract infection and used an oral water-alcoholic extract of the herb *Echinacea pallida* for about a week, in order to shorten the duration and the severity of his symptoms. No other medication, except paracetamol, had been used.

Examination revealed hypotension, sinus tachycardia, mild elevation in temperature (37.2°C), and few diffused petechiae, anemia (Hb = 6.0 g/dL), severe thrombocytopenia (platelets = 20,000/μL), and microangiopathic-type hemolytic anemia with fragmented red blood cells (schistocytes, + + +), increased indirect bilirubin, and markedly elevated LDH levels.

Both direct and indirect Coombs tests were negative. Renal function was slightly impaired, as was liver function. Coagulation tests were within normal range, and cryoglobulin and autoantibodies were not detected. Bacterial and viral antibodies were negative.

The patient was transfused with red blood cells and fresh frozen plasmas (FFPs) but had a syncopal episode followed by tonic-clonic seizures and finally entered status epilepticus which was controlled with general anesthesia and ventilatory assistance. He was treated with large-volume plasmapheresis twice daily and administration of FFPs. Plasmapheresis was continued once or twice daily for over a month until the disease remission. Prednisone, acetylsalicylic acid, intravenous immunoglobulin, and vincristine infusion were also used. He finally had an uneventful outcome.

*Echinacea* plant preparations are widely used in the prevention and treatment of upper respiratory tract infections [1,2]. Several studies have been carried out to investigate the immunomodulatory mechanisms of the plant's extracts. *Echinacea*-activated macrophages stimulate IFN-gamma production in association with the secondary activation and proliferation of cytotoxic and suppressor T lymphocytes, reflecting cell-mediated immune responses [3]. An in vitro study, in *Echinacea*-exposed THP-1 cell cultures, revealed an induction of the expression of various interleukin and TNF-α genes [4]. *Echinacea* induces de novo synthesis of TNF-α mRNA, in primary monocytes/macrophages cultures, increasing cAMP, p38/MAPK, and JNK signaling, as well as activating NF-kappa B and ATF-2/CREB-1 receptors, highlighting the role of the plant's alkyl amides as potent immunomodulators [1].

Some reports associate autoimmune disorders with the use of *Echinacea* extracts and underline its risk of hepatotoxicity, exacerbation of allergies and asthma, as well as anaphylactic reactions [2]. One study implicates its use with flares of pemphigus vulgaris, suggesting that immunostimulatory herbal supplements may exacerbate existing autoimmune diseases or precipitate autoimmune diseases in genetically predisposed persons [5]. To our knowledge, our report is the first to associate a possible induction or exacerbation of a severe TTP incident with use of the herb *Echinacea*.

LIATSOS GEORGE  
ELEFSINIOTIS IOANNIS  
TODOROVA RADOSTINA  
MOULAKAKIS ANTONIOS

Department of Internal Medicine, Hippokraton Hospital, Athens, Greece

Published online in Wiley InterScience (www.interscience.wiley.com).

DOI: 10.1002/ajh.20531

## REFERENCES

1. Gertsch J, Schoop R, Kuenzle U, Suter A. *Echinacea* alkylamides modulate TNF-α gene expression via cannabinoid receptor CB2 and multiple signal transduction pathways. *FEBS Lett* 2004;577(3):563–569.
2. Bielory L. Complementary and alternative interventions in asthma, allergy and immunology. *Ann Allergy Asthma Immunol* 2004;93(2 Suppl 1):S45–S54.
3. Mishima S, Saito K, Maruyama H, et al. Antioxidant and immuno-enhancing effects of *Echinacea purpurea*. *Biol Pharm Bull* 2004;27(7):1004–1009.
4. Randolph RK, Gellenbeck K, Stonebrook K, et al. Regulation of human immune gene expression as influenced by a commercial blended *Echinacea* product: preliminary studies. *Exp Biol Med* (Maywood) 2003;228(9):1051–1056.
5. Lee AN, Werth VP. Activation of autoimmunity following use of immunostimulatory herbal supplements. *Arch Dermatol* 2004;140(6):724–727.

## Monolateral Renal Infarction and Erythromelalgia in a Case of Chronic Myelogenous Leukemia

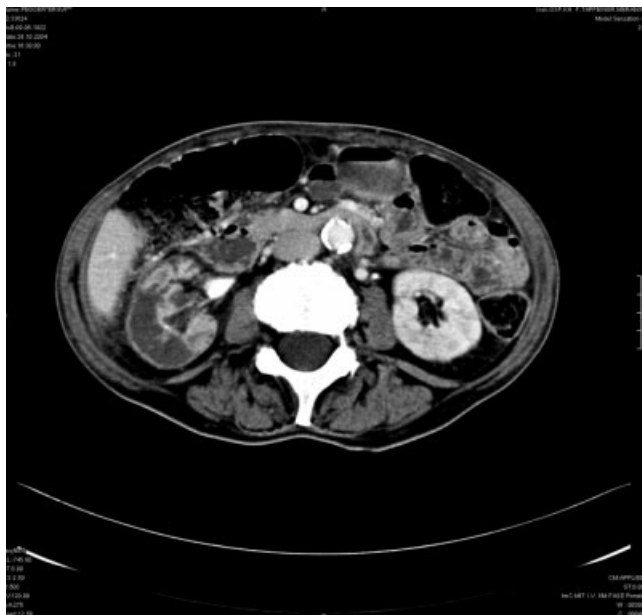
*To the Editor:* Thrombocytosis-related erythromelalgia is a rare event in chronic myelogenous leukemia (CML), and the symptoms can precede

the onset of the myeloproliferative disease by a median of 2 years [1]. Erythromelalgia is characterized by attacks of severe burning pain, erythema, and warmth of the extremities, primarily the feet and, to a lesser extent, the hands. The major hemostatic problem underlying hyperleukocytosis and thrombocytosis appears to be hemorrhage rather than thrombosis. Acute thromboembolism, which causes occlusion of blood supply and organ infarction, has rarely been observed in patients with CML.

An 82-year-old female with a 5-year history of CML (treated with different substances such as hydroxyurea, interferon alfa, and imatinib mesylate, all of which were discontinued because of severe side effects) presented with abdominal pain. At the time of hospital admission, the patient was treated with hydroxyurea but with deterioration. Laboratory findings showed severe normochromic anemia (Hgb 7.4 g/dL), high platelet counts ( $3.5 \times 10^9/L$ ), and elevated creatinine (2.13 mg/dL) and BUN (104 mg/dL) levels. Clinical examination revealed an enlarged spleen (14 cm) and typical symptoms of erythromelalgia. The bone marrow aspiration showed an accelerated phase of CML. Anti-aggregation therapy was started with low-dose Acetylsalicylic acid (ASS) (100 mg/day), but anti-aggregation had to be stopped due to mucocutaneous bleeding, epistaxis, and gingival bleeding.

Multiple small infarction areas in the right kidney were found by computer tomography (Fig. 1). Etoposide at 100 mg/day for 3 days was started, and the platelet count decreased from  $3.5 \times 10^9/L$  to  $0.6 \times 10^9/L$ . The patient received erythrocyte transfusions to compensate anemia and anti-coagulation therapy with low molecular weight heparin. Renal insufficiency improved, and the creatinine level returned to normal values. Because the platelets began to increase, therapy with anagrelide was started and the platelet count remained stable within  $0.6\text{--}1.2 \times 10^9/L$ . Erythromelalgia symptoms disappeared within a few weeks. No further bleeding or thrombotic complications were seen.

As opposed to other myeloproliferative disorders, symptomatic thrombocytosis is rare in chronic myeloid leukemia and thrombohemorrhagic complications of CML-associated thrombocytosis are infrequent. The therapy of choice of extreme thrombocytosis-associated CML has not yet been established. Thrombocytosis can be decreased quickly by plasmapheresis, but the effect is transient and this is why this kind of treatment should begin as soon as possible [2].



**Fig. 1. Multiple infarction areas in the right kidney as shown by computer tomography.**

Anagrelide is an effective and well-tolerated treatment modality for the prevention of thromboembolic complications, even in patients in whom imatinib mesylate is the primary therapy. Erythromelalgia is a rare—sometimes microscopic—thrombotic complication in myeloproliferative disorders [3], and it may be accompanied by vascular stenosis [4].

Reduction of excessive platelet counts by anagrelide may lead to the prevention of thrombohemorrhagic complications. After reduction of the platelet count using anagrelide thrombohemorrhagic complications disappeared or did not recur in all symptomatic patients [5]. Although the platelet count remained always elevated [ $(0.8\text{--}1.2) \times 10^9/L$ ], in our patient treated with anagrelide no thrombohemorrhagic complication recurred.

**KARIN BERNARDINI  
ANDREA JUDITH LANTHALER  
THOMAS BURATTI  
MANFRED MITTERER**

*Department of Laboratory and Internal Medicine, Franz Tappeiner Hospital Merano, Italy  
Published online in Wiley InterScience (www.interscience.wiley.com).  
DOI: 10.1002/ajh.20545*

#### REFERENCES

1. Kurzrock R, Cohen PR. Erythromelalgia and myeloproliferative disorders. *Arch Intern Med* 1989;149(1):105–109.
2. Thakral B, Saluja K, Malhotra P, Sharma RR, Marwaha N, Varma S. Therapeutic plateletpheresis in a case of symptomatic thrombocytosis in chronic myeloid leukaemia. *Ther Apher Dial* 2004;8(6):497–499.
3. Tarach JS, Nowicka-Tarach BM, Matuszek B, Nowakowski A. Erythromelalgia—a thrombotic complication in chronic myeloproliferative disorders. *Med Sci Monit* 2000;6(1):204–208.
4. Hur JW, Lee YY, Lee WS, Jun JB. Erythromelalgia as a presenting manifestation in a patient with essential thrombocythemia complicating renovascular hypertension due to unilateral renal artery stenosis. *Rheumatol Int* 2005;26(1):83–85.
5. Trapp OM, Beykirch MK, Petrides PE. Anagrelide for treatment of patients with chronic myelogenous leukemia and a high platelet count. *Blood Cells Mol Dis* 1998;24(1):9–13.

#### Intramuscular Deferoxamine in Hereditary Hemochromatosis

*To the Editor:* Management of iron overload is still complex, and several strategies can be effective for different diseases and situations. Regarding this, we read with interest the letter by Barton et al. about the management of hemochromatosis in a Jehovah's Witness [1], and the article by Franchini et al. about the treatment of iron overload with a twice-daily subcutaneous bolus injection of deferoxamine (DFO), where this management resulted in results similar to those with continuous subcutaneous infusion [2]. Recently, we treated a patient with hereditary hemochromatosis (HH) and iron overload, with intramuscular DFO improving the transferrin saturation index (TSI) up to normalization.

The patient was a 39-year-old woman without any medical antecedents, submitted because of an asymptomatic abnormal TSI of 91.9%. A complementary study also revealed increased serum iron and ferritin levels (iron, 181 mcg/dl; normal values, 50–150 mcg/dl; ferritin, 434 ng/ml; normal values, 15–140 ng/ml), without any other findings. A 6-month control again showed an increased TSI level (104%). A genetic test of the HFE gene was then made. The patient was homozygotic for the C282Y mutation, and so was diagnosed with HH. Phlebotomy was begun, with poor



tolerance from the patient. A new control was performed with a poor response (TSI, 92.8%), so we decided to initiate treatment with intramuscular DFO along with phlebotomy. DFO was administered at a dose of 1 g intramuscularly 5 days a week for 3 months. Afterwards, we found a dramatic improvement in all parameters (TSI, 23.5%; iron, 58 mcg/dl; ferritin, 47.7 ng/ml), so DFO treatment was discontinued, and phlebotomy was continued. The patient did not experience any adverse effect and is actually asymptomatic, with a TSI level of 29.4%.

Hereditary hemochromatosis is an autosomal-recessive disorder associated with a mutation of the HFE gene [3]. HH is a well-defined cause of iron overload and phlebotomy is the standard treatment, and is strongly recommended early after diagnosis [3]. DFO is not recommended in HH, being used only in case of anemia, intolerance toward phlebotomy, or other conditions that contraindicate phlebotomy [4]. Chelation therapy with DFO is the first choice in secondary hemochromatosis [2], usually administered by daily subcutaneous continuous infusion over 8–12 hr with a portable pump, or as recently described, by twice-daily subcutaneous bolus injection [2]. Intramuscular DFO was used previously, showing a worse effect compared with subcutaneous administration by a lesser iron excretion [5]. Nonetheless, we used DFO in adjuvant therapy to phlebotomy because of the patient's failure with TSI normalization and bad tolerance to classic treatment. The rapid and great improvement observed in our patient's TSI level may have been due to DFO therapy, since the previous phlebotomy did not get such good results. Although our experience is limited and controlled studies must be done to assess the efficacy of this combined therapy, we think that the concomitant use of DFO along with phlebotomy in early

treatment could be a safe and useful method to shorten duration of treatment in patients intolerant of, or with contraindications for, phlebotomy.

**FRANCISCO JAVIER POLO-ROMERO**

*Department of Internal Medicine, Hospital of Hellín, Hellín, Albacete, Spain*

*Published online in Wiley InterScience (www.interscience.wiley.com).*

*DOI: 10.1002/ajh.20450*

## REFERENCES

1. Barton JC, Sublett S, Boyd GL. Management of hemochromatosis in a Jehovah's Witness. *Am J Hematol* 2005;78:83.
2. Franchini M, Gandini G, Gironcoli M, Vassanelli A, Borgna-Pignati C, Aprili G. Safety and efficacy of subcutaneous bolus injection of deferoxamine in adult patients with iron overload. *Blood* 2000;95:2776–2779.
3. Pietrangelo A. Hereditary hemochromatosis—a new look at an old disease. *N Engl J Med* 2004;350:2383–2397.
4. Barton JC, McDonnell SM, Adams PC, Brissot P, Powell LW, Edwards CQ, Cook JD, Kowdley KV, Hemochromatosis Management Working Group. Management of hemochromatosis. *Ann Intern Med* 1998;129:932–939.
5. Hussain MA, Green N, Flynn DM, Hussein S, Hoffbrand AV. Subcutaneous infusion and intramuscular injection of desferrioxamine in patients with transfusional overload. *Lancet* 1976;2:1278–1280