

LETTERS AND  
CORRESPONDENCE

Letters and correspondence submitted for possible publication must be identified as such. Text length must not exceed 500 words and five bibliographic references. A single concise figure or table may be included if it is essential to support the communication. Letters not typed double-spaced will not be considered for publication. Letters not meeting these specifications will not be returned to authors. Letters to the Editor are utilized to communicate a single novel observation or finding. Correspondence is to be used to supplement or constructively comment on the contents of a publication in the journal and cannot exceed the restrictions for Letters to the Editor. The Editor reserves the right to shorten text, delete objectional comments, and make other changes to comply with the style of the journal. Permission for publication must be appended as a postscript. Submissions must be sent to Paul Chervenick, M.D., Editor of Brief Reports/Letters to Editors, American Journal of Hematology, H. Lee Moffitt Cancer Center, University of South Florida, 12902 Magnolia Drive, Tampa, FL 33612 to permit rapid consideration for publication.

solution can deplete circulating plasma arginine to undetectable levels rapidly [3]. Low plasma arginine values were recently described in thrombotic microangiopathy, in subjects with hemolytic anemia, thrombocytopenia, and many with renal azotemia [4]. In the consumptive thrombocytopenia of TTP, reduced availability of L-arginine in circulating plasma may be rate-limiting for nitric oxide production by platelets and/or endothelial cells for the normal function of nitric oxide in increasing platelet stability and increasing vasoprotection [5]. We have been granted approval by the FDA for a phase I clinical trial of oral use of L-citrulline as body precursor of L-arginine as replacement nutrient in adult TTP.

WILLIAM H. WAUGH  
CHARLES L. KNUPP  
DARLA K. LILES

Departments of Physiology and Medicine, East Carolina University  
School of Medicine, Greenville, NC

## References

1. George JN, El-Harake M. Thrombocytopenia due to enhanced platelet destruction by nonimmunologic mechanisms. In: Williams Hematology, 5th ed. New York: McGraw-Hill, 1995, pp 1290–1315.
2. Waugh WH, Daeschner CW III, Files BA, Gordon D. Evidence that L-arginine is a key amino acid in sickle cell anemia—a preliminary report. *Nutr Res* 1999; (in press).
3. Prins HA, Houdijk APJ, van Lambalgen AA et al. Paradoxical changes in organ blood flow after arginase infusion in the non-stressed rat. *Shock* 1998;9:422–427.
4. Herlitz H, Petersson A, Sigström L, Wennmalm A, Westberg G. The arginine-nitric oxide pathway in thrombotic microangiopathy. *Scand J Urol Nephrol* 1997; 31:477–479.
5. Moncada S, Higgs A. The L-arginine-nitric oxide pathway. *N Engl J Med* 1993; 329:2002–2012.

### Undetectable Plasma L-Arginine Level before Visible Hemolysis in Thrombotic Thrombocytopenic Purpura

*To the Editor:* The primary treatment for classic thrombotic thrombocytopenic purpura (TTP) is prompt plasmapheresis; many relapses occur within 1 week of stopping repeated plasmapheresis [1]. The reason why plasma exchanges are effective is unknown. It could be removal of a harmful plasma component or replacement of a deficient component [1].

We report a relapse of TTP in a 79-year-old woman, oriented but drowsy, with type II diabetes mellitus. She was rehospitalized a few days after previous repeated plasmapheresis for idiopathic TTP. Upon re-admission, fever, azotemia and ketoacidosis were absent. Initial platelet count was 21 K/ $\mu$ l, serum LDH was 675 U/l, hematocrit was 27.4%, and a few schistocytes were reported. Immediately before re-institution of plasmapheresis, a central venous blood sample, centrifuged, revealed plasma that was not visibly orange, reddish, or dark in hue. The plasma hemoglobin measured 1.6 mg/dl (normal) by the classical Crosby–Furth method, plasma L-arginine concentration was 0.0  $\mu$ mole/l (undetectable), assayed enzymatically, and plasma arginase activity measured 2.0  $\mu$ mol urea formed/ml plasma per 30 min at 37° Celsius (about twice high normal value) [2]. Plasma L-arginine values just before daily plasmapheresis on the 5th and 7th day measured low at 42.4 and 37.0  $\mu$ mol/l, respectively. On the last 4 days of this 11-day rehospitalization period (10 aphereses), blood platelet counts, and serum LDH values were normal, between 204 and 219 K/ $\mu$ l and 189 and 208 U/l, respectively. Blood glucose levels ranged between 200 and 421 mg/dl during the rehospitalization. The patient received glipizide and insulin therapy.

The finding of undetectable plasma L-arginine level with a normal plasma hemoglobin level is unique in TTP [1]. Plasma L-arginine value might be very low early in many instances of TTP, it is speculated. High plasma LDH and arginase activity may arise from damage to various cells besides human erythrocytes [2]. Endothelial, liver, and muscle cells contain arginase. Experimentally, intravenous injection of purified liver arginase

### Parkinson's Syndrome Preceding Clinical Manifestation of Gaucher's Disease

*To the Editor:* Lysosomal storage disorders are rare inborn errors of metabolism. Of these, Gaucher's disease is the most prevalent, it being genetically determined by several mutations of the  $\beta$ -glucosidase (glucocerebrosidase) gene which is located on chromosome 1 [1]. Classically, Gaucher's disease is divided into three types according to the absence or presence of neurological symptoms and the dynamics of developing clinical signs. Type I (or the adult type) Gaucher's disease has a chronically progressive clinical course and has been considered as non-neuronopathic [1,2].

A 51-year-old man with a 12-year history of Parkinson's disease was referred to our department for consultation because of the rapid appearance and development of leuco- and thrombocytopenia. Prior to the diagnosis of Parkinson's disease at the age of thirty-nine, the patient had never suffered from any disease. The course of Parkinson's disease had begun with a predominance of bilateral akinetic-rigid symptoms, with a poor response to conventional anti-Parkinsonian therapy. During the present hematological consultation, the patient, except for Parkinson's disease-related symptoms,

did not report any other complaints, including those typical of Gaucher's disease, such as bone pain. Physical examination revealed no lymphadenopathy or signs of thrombocytopenia. Abdomen examination was not adequate because of increased abdominal muscle tone. Laboratory studies revealed the following: hemoglobin level—13.4 g/dl; MCV—74.2 fl; MCH—26.7 pg; white blood cells—2.7 K/ $\mu$ l (neutrophils—57%; lymphocytes—37%; monocytes—6%); platelets—58 K/ $\mu$ l; slightly increased total calcium concentration (2.74 mmol/l) and pronounced elevation of the acid phosphatase level (4.5-fold). Other laboratory tests were negative. Investigation of the abdomen by ultrasound and computer tomography revealed massive splenomegaly (lower border of spleen to the iliac crest level), with no hepatomegaly or other pathology. Smears of bone marrow aspirate showed the presence of normal proportions of all, correctly maturing, hemopoietic cell lines and a few large cells with nuclei eccentrically placed and cytoplasm with striations and blurred border. The histopathology of the bone marrow, based on trephine biopsy material, showed massive infiltration of the marrow by large cells with typical "crumpled tissue paper" cytoplasm (Gaucher cells). A splenic biopsy specimen revealed infiltration by the same type of cells. Brain computer tomography and magnetic resonance imaging showed no pathology. The definitive diagnosis was established by determining the leukocyte  $\beta$ -glucosidase and serum chitotriosidase activity (0.75 nmol/mg of protein/hr and 5883 nmol/ml/hr, respectively). The presence of two glucocerebrosidase mutations (N370S and IVS2+1) was confirmed by Ellen Sidransky (National Institutes of Health, Bethesda, MD). Both mutations are commonly encountered in Gaucher's patients of Ashkenazi Jewish origin [1].

In the present case, the Parkinson's syndrome preceded the Gaucher's disease manifestation by about 12 years. This patient, to our knowledge, was the youngest one with Gaucher's disease at the moment of Parkinson's syndrome occurrence [2–4]. The present case is unique in combining atypical Parkinson's syndrome with Gaucher's disease. In recent literature we have found only scanty data relating to patients with Gaucher's disease who also presented with Parkinson's syndrome; all of them had developed an atypical Parkinsonism at a young age (41–55) and were resistant to conventional anti-Parkinsonian therapy.

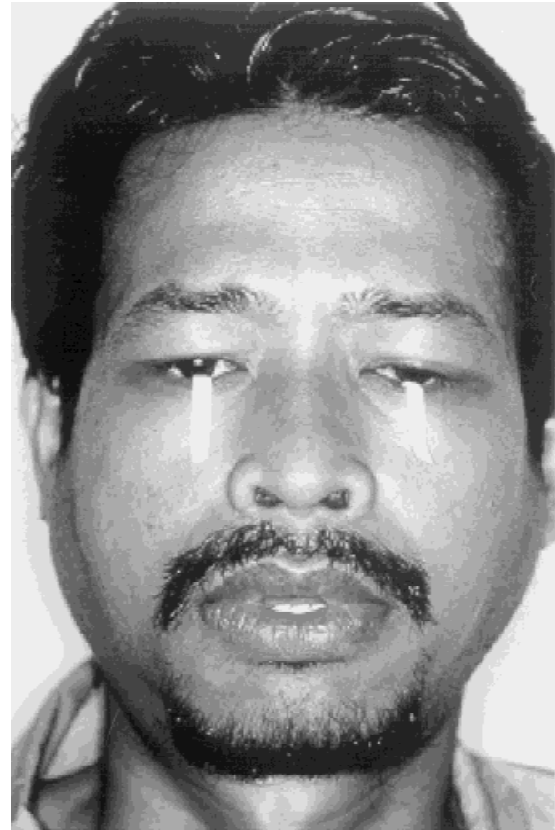
The neurological symptoms typical of neuronopathic types of Gaucher's disease, such as muscle hypertonia, limb rigidity, and seizures are similar to the symptoms required for establishing the diagnosis of Parkinson's syndrome/disease. At present, it is not clear whether Gaucher's disease and the Parkinson syndrome share a cause-and-effect relationship. However, among young patients with Parkinsonian symptoms who do not respond to typical anti-Parkinsonian treatment, Gaucher's disease should be taken into consideration despite the lack of Gaucher's disease symptoms. It should be emphasized that on the contrary to our patient, none of the previously reported patients developed Parkinsonian symptoms before being diagnosed with Gaucher's disease. Now, type I Gaucher's patients with atypical Parkinsonian symptoms cannot be simply classified according to any presently-existing types of Gaucher's disease.

**MACIEJ MACHACZKA  
MALGORZATA RUCINSKA  
ALEKSANDER B. SKOTNICKI  
WOJCIECH JURCZAK**

*Department of Hematology, Collegium Medicum of the Jagiellonian University, Cracow, Poland*

#### References

1. Beutler E, Gelbart T, Kuhl W, Zimran A, West C. Mutations in Jewish patients with Gaucher disease. *Blood* 1992;79:1662–1666.
2. Neudorfer O, Giladi N, Elstein D, Abrahamov A, Turezkite T, Aghai E, Reches A, Bembi B, Zimran A: Occurrence of Parkinson's syndrome in type I Gaucher disease. *Q J Med* 1996;89:691–694.
3. Tylki-Szymańska A, Millat G, Maire I, Czartoryska B. Types I and III Gaucher disease in Poland: incidence of the most common mutations and phenotypic manifestations. *Eur J Hum Genet* 1996;4:334–337.
4. Cormand B, Grinberg D, Gort L, Chabas A, Vilageliu L. Molecular analysis and



**Fig. 1. Prominent enlargement of the lachrymal, parotid, submandibular and sublingual glands was evident. The Schirmer's test at 5 min was abnormal.**

clinical findings in the Spanish Gaucher disease population: putative haplotype of the N370S ancestral chromosome. *Hum Mutat* 1998;11:295–305.

#### Multiple Myeloma Presenting As Sjogren's Syndrome

*To the Editor:* Sjogren's syndrome (SS) is predominantly a disease of middle-aged women, while myeloma is a disease of the elderly with only 2% of cases occur in patients less than 40 years of age. There has been very few reported case of multiple myeloma (MM) which had SS as the first presentation [1]. SS has been recognized to have a high incidence of benign monoclonal gammopathy, although MM is very rare. Most of the monoclonal gammopathies in patients with SS involve the IgM class [3]. We report a male patient with IgA-lambda-type MM presenting as SS who responded to anti-myeloma treatment.

A 41-year-old Malay man presented in February 1998 with a 1-month history of troublesome dryness of his eyes and mouth. This had led to painful red and excessive tearing of the eyes and difficulty in swallowing dry food. Treatment with tears and saliva substitutes were not effective. On examination, prominent enlargement of the lachrymal, parotid, submandibular and sublingual glands was evident (Fig. 1). There were marked xerostomia, bilateral conjunctivitis with mucopurulent discharge and generalized lymphadenopathy. Schirmer's test was abnormal (2 mm wetting in

5 min). Laboratory studies disclosed anemia with a hematocrit of 26.4%, leukopenia with a white cell count of  $2.0 \times 10^9/l$ , positive antinuclear antibody (1:40) with a speckled pattern and an erythrocyte sedimentation rate of 111 mm/hr. The HIV-antibody tests were negative. Labial and parotid gland biopsies showed marked plasmacytic infiltration of the glandular tissues. The plasmacytic type of cells showed lambda light-chain restriction. Similar findings were evident in the lymph node biopsy specimens. The bone marrow contained approximately 15% plasma cells, with atypical aspects. Immunoelectrophoresis showed monoclonal IgA lambda and the level was 3620 mg/dl. The skeletal radiograph was normal. He received induction chemotherapy with vincristine, adriamycin, and dexamethasone (VAD). One month following VAD chemotherapy the patient was asymptomatic. The lachrymal and salivary glands and peripheral lymph nodes were not palpable and the Schirmer's test was normal.

This case is unique in that the patient manifested several unusual features of MM which include his relatively younger age, enlargement of the peripheral lymph nodes and SS. SS is characterized by two main autoimmune phenomena: B-cell hyperactivity and lymphocytic infiltration of the exocrine glands. B-cell lymphoma develops in 5% of patients. Hyperimmune reaction has been assumed to play an important role in the lymphomagenesis in SS. Osserman et al. [4] have observed that chronic inflammation may represent a stimulus in the development of MM. Non-IgM monoclonal gammopathies in patients with SS is extremely unusual. Among the four reported cases of SS associated with MM, the type of M-protein was IgM, Bence Jones-kappa [1], and IgG [5]. None of the patients had lambda light-chain in their serum or urine. Previous reports [1,5] had shown that treatment of the underlying myeloma did not favorably effect the clinical manifestations of SS. Chemotherapy with melphalan and prednisolone was not effective in a patient with SS associated with IgG myeloma and resulted in partial remission in 2 other SS patients, who had IgM-kappa and Bence Jones-kappa myeloma. In this patient, rapid recovery of SS was evident following one cycle of VAD. One wonders whether this feature could be explained by the fact that VAD regimen is more effective than the conventional MP chemotherapy or whether SS associated with IgA paraprotein is more responsive to treatment than those associated with non-IgA monoclonal gammopathies. To our knowledge, this patient represents the first patient with IgA-lambda myeloma presenting with SS in whom anti-myeloma treatment resulted in complete clinical remission of the SS.

S.A.W. FADILAH  
S.K. CHEONG

Division of Hematology, Faculty of Medicine, Universiti Kebangsaan Malaysia (UKM), Kuala Lumpur, Malaysia

#### REFERENCES

1. Akashi Y, Yoshizawa N, Kubota T, Oshikawa Y, Oda T, Ishida A, Nakabayashi I, Nishima J, Tazawa K. Primary biliary cirrhosis complicated with Sjogren's syndrome and multiple myeloma. *Nephron* 1996;73:730-732.
2. Ota T, Wake A, Eti S. Sjogren's syndrome terminating with multiple myeloma. *Scand J Rheumatol* 1995;24:316-318.
3. Osserman EF, Takayushi K. Consideration regarding the pathogenesis of plasmacytic dyscrasias. *Scand J Haematol* 1965;28(suppl):49.
4. Sugai S, Konda S, Shyrasaki Y. Non-IgM monoclonal gammopathy in patients with Sjogren's syndrome. *Am J Med* 1980;68:861-866.
5. Rodriguez-Cuartero A, Salas-Galan A. Sjogren's syndrome with multiple myeloma. *Eur J Cancer* 1997;33:167-168.

#### Lack of Compliance and Late-Onset Warfarin-induced Skin Necrosis

To the Editor: We read with interest the paper by Essex et al. [1] on late-onset warfarin-induced skin necrosis. The authors mention the inad-

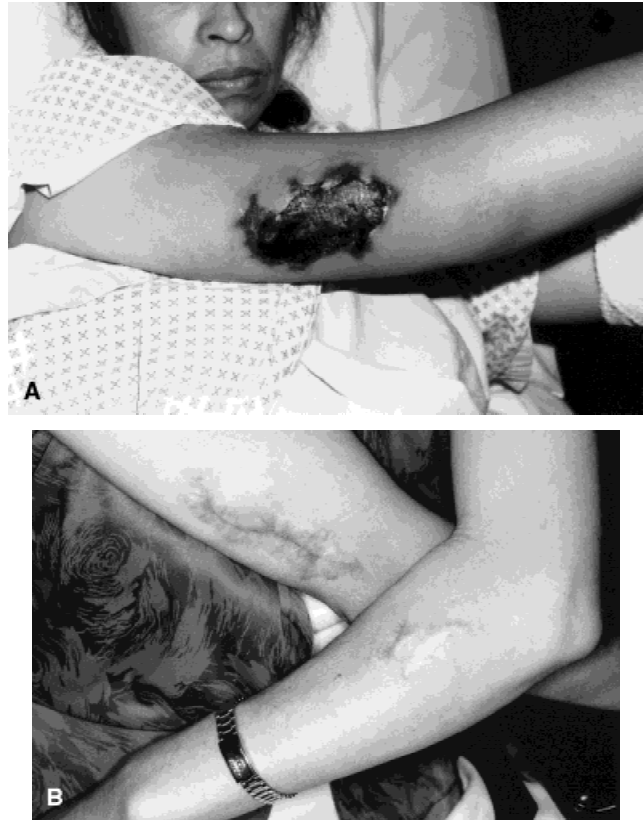

Fig. 1. (A) Area of total thickness skin necrosis covered by thick black eschar over the right arm. (B) Healed areas of skin necrosis showing irregular scarring.

vertent discontinuation of warfarin followed by the resumption of therapy a few days later without heparin coverage as a potential cause of late onset warfarin necrosis, but we are not aware of reports of such occurrence. We report on a patient in whom apparent late-onset warfarin necrosis was a consequence of poor compliance and inappropriate dosing.

The patient was a 34-year-old Hispanic woman who was delivered of twins by Cesarean section and developed deep vein thrombosis of the right leg on the second postpartum day. After treatment with heparin and warfarin, she was discharged on warfarin 5 mg of qAM (INR 2.3) on the 7th hospital day. She presented 4 weeks later with a 1 day history of painful "bruises" over the anterolateral aspect of the left leg, left proximal forearm, and lateral aspect of the right arm, all of which developed within 24 h into painful black areas of skin with blister formation. She had inadvertently stopped taking warfarin about 10 days prior to admission and then resumed taking 15 mg of warfarin daily for about 3 days until she developed the painful "bruises" on the extremities.

The patient had a past history of bilateral deep vein thrombosis of the legs treated with warfarin without incident 14 years previously, and chronic bilateral venous ulcers of the medial malleoli for many years.

She was in moderate pain from the "bruises." There were bilateral chronic ankle ulcers over the medial malleoli with a surrounding areas of skin hyperpigmentation. Painful black necrotic skin lesions surrounded by an erythematous "halo" and small blisters filled with sanguinous fluid were noted on the anterolateral left leg, left proximal forearm, and the lateral aspect of right arm measuring up to  $8.5 \times 6$  cm (Fig. 1). A mid-diastolic murmur was heard over the cardiac apex.

Her prothrombin time was 21.6 s, partial thromboplastin time 42 s, and D-dimer 0.5 mg/ml. She was treated with heparin, fresh frozen plasma, and vitamin K. Warfarin was discontinued. Nine days after discontinuation of

warfarin the plasma functional protein C level (Accuclot Protein C, Sigma, St. Louis, MO) was 80%, protein S (Bioclot Protein S, Biopool Canada Inc., Burlington, Ontario) 85% and antithrombin III (Accucolor Antithrombin III, Sigma, St. Louis, MO) level 132%. An activated protein C resistance clotting assay (PTT ratio of 3.17) and DNA analysis for factor V Leiden mutation (The Blood Center of Southeastern Wisconsin, Milwaukee, WI) were normal or negative. A modified dilute Russell's viper venom test for lupus anticoagulant was negative.

Warfarin therapy was begun on the 15th hospital day under cover of heparin using initial daily doses of 1 mg of warfarin as described by Anderson et al [2]. Heparin therapy was continued until her discharge. No new skin lesions appeared with this regimen. She refused skin grafting and she was discharged home on warfarin 5 mg of qAM on the 28th hospital day. The areas of skin necrosis healed by scarring over a period of 1 year. Subsequently she had a mitral valve xenograft implanted at another hospital and has been on chronic warfarin therapy with no complications.

Apparent "late-onset" warfarin necrosis may be an uncommon complication of poor compliance and inappropriate dosing of the drug by the patient.

**PRASAD RAO KODURI**  
**RABIA PARVEEZ**

*Division of Hematology, Cook County Hospital, Chicago, Illinois*

#### REFERENCES

1. Essex DW, Wynn SS, Jin DK. Late-onset warfarin-induced skin necrosis: Case report and review of the literature. *Am J Hematol* 1998;57:233-237.
2. Anderson DR, Brill-Edwards P, Walker I. Warfarin-induced skin necrosis in 2 patients with protein S deficiency: Successful reinstatement of warfarin therapy. *Haemostasis* 1992;22:124-128.

### **Evan's Syndrome Precipitated by Fludarabine Therapy in a Case of CLL**

*To the Editor:* We have recently treated a 64-year-old Caucasian lady who presented with combined autoimmune hemolytic anemia and immune thrombocytopenia (ITP) shortly after being treated with fludarabine for her chronic lymphocytic leukemia (CLL).

The patient was originally diagnosed with B-cell CLL by morphology and immunophenotyping in 1988 and apparently did well without treatment until August 1998. At that time, she developed increasing fatigue and was treated for pneumonia. The white count was 150,000/ $\mu$ l with 90% lymphocytes, hemoglobin of 11 gm/dl, and a platelet count of 250,000/ $\mu$ l. She was treated with fludarabine 25 mg/m<sup>2</sup> intravenously for 5 days every 4 weeks for 2 cycles. About 10 days after her last dose of chemotherapy, she had to be hospitalized for severe fatigue, shortness of breath, and a purpuric skin rash. Initial evaluation revealed a distressed patient with

severe pallor, no external bleeding, mild scleral icterus, moderate hepatosplenomegaly and classic skin, and mucous membrane purpura. The rest of her physical examination was unremarkable.

Laboratory evaluation showed a hemoglobin of 5.5 g/dl, platelet count of 5000/ $\mu$ l, and white blood cell count of 14,000/ $\mu$ l with 60% neutrophils and 17% lymphocytes. Chemistry panel was significant for a bilirubin of 3 mg/dl, LDH of 960 U/l, a haptoglobin level <6 mg/dl with normal liver enzymes and creatinine. Peripheral smear examination showed thrombocytopenia with polychromasia, microspherocytosis and rare nucleated red blood cells. Bone marrow aspirate and biopsy revealed erythroid and megakaryocytic hyperplasia. The direct Coomb's test was positive for panagglutinin, IgG, and complements. The warm reacting antibody was identified as anti-E (an antigen of the Rh system). A rheumatologic panel including anticardiolipin antibody was negative.

The patient was treated with prednisone 1 mg/kg of body weight on which she gradually improved. Two weeks later, her hemoglobin was 9.5, white blood cell count was 11,000, and platelet count was 87,000. Her Coomb's test remained positive but LDH and haptoglobin levels were normalized.

The patient developed an immediate relapse as soon as her prednisone was tapered down. Eventually, she had a splenectomy after 1 month of the initial diagnosis. Following splenectomy, she entered into a durable remission with successful withdrawal of steroid.

The case described above had all features of Evan's syndrome (combined autoimmune hemolysis and immune thrombocytopenia). In this case, it was clearly precipitated by fludarabine therapy, because her past records showed no evidence of ITP or autoimmune hemolytic anemia.

Immunosuppression and immune dysregulations are common in CLL and are often aggravated by fludarabine [1]. Three autoimmune syndromes associated with CLL are well described, namely autoimmune hemolytic anemia, pure red cell aplasia, and ITP [2]. We are aware of only a single report of Evan's syndrome in the setting of CLL treated with fludarabine [3]. The current case would be the second one reported in the literature so far. Because fludarabine is likely to be used more and more frequently in this disease additional cases may surface. Due to the potentially serious nature of Evan's syndrome, the physicians taking care of such patients should be aware of the possibility of this complication associated with fludarabine therapy.

**KAUSHIK SEN**  
**MATT KALAYCIO**

*Department of Hematology and Medical Oncology  
The Cleveland Clinic Foundation  
9500 Euclid Avenue, Cleveland, OH*

#### REFERENCES

1. Keating MJ, O'Brien S, Lerner S, et al. Long-term follow-up of patients with chronic lymphocytic leukemia (CLL) receiving fludarabine regimens as initial therapy. *Blood* 1998;92:1165-1171.
2. Diehl L, Ketchum L. Autoimmune Disease and Chronic Lymphocytic Leukemia: Autoimmune hemolytic anemia, pure red cell aplasia, and autoimmune thrombocytopenia. *Semin Oncol* 1998;25:80-97.
3. Shvidel L, Shtarlid M, Klepfish A, Sigler E, Berrebi A. Evan's syndrome complicating fludarabine treatment for advanced B-CLL. *Br J Haematol* 1997;99:706.