

ERRATUM

Morland, BJ, Mann, JR, Milford, DV, Raafat, F, and Stevens, MCG: Ifosfamide Nephrotoxicity in Children: Histopathological Features in Two Cases. (*Medical and Pediatric Oncology*) **27**:57–61, 1996.

Figure 1 and its legend as they appeared in the original printing were incorrect. Below are the figure and legend as they should have appeared.

The authors regret the error.

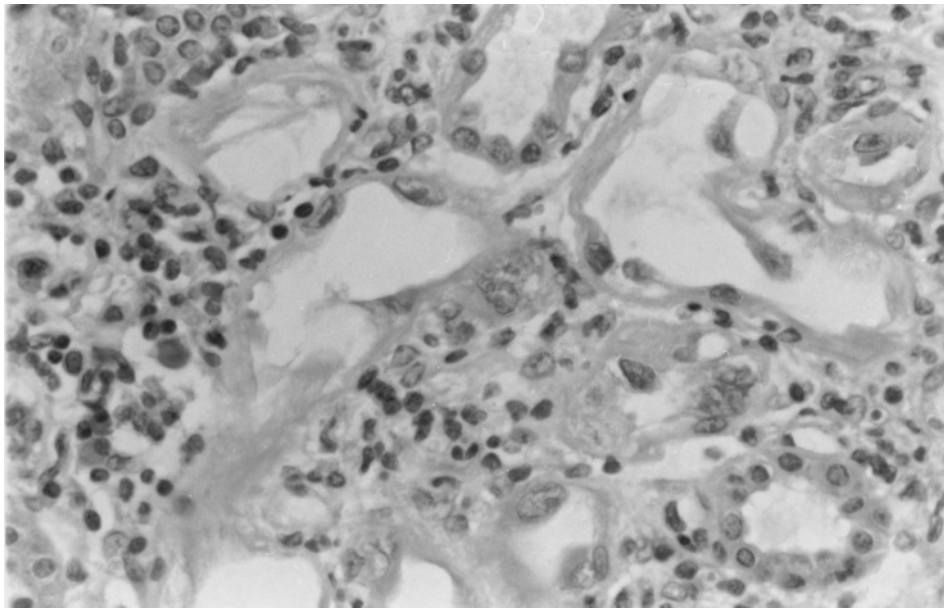


Fig. 1. Case 1. Tubular atrophy, lymphocytic infiltration, and emperipolesis.