

Alpha-methyldopa-induced systemic vasculitis confused with Wegener's granulomatosis

To the Editor:

Alpha-methyldopa was introduced as an antihypertensive drug in 1960. Side effects of its administration have included dry mouth, fever, gastrointestinal upset, positive results on antinuclear antibody (ANA) tests and lupus erythematosus cell preparations, granulocytopenia and thrombocytopenia, positive direct Coombs' test results, hemolytic anemia, and serious hepatic injury (1,2).

We report a case of acute hepatic injury and systemic granulomatous disease mimicking Wegener's granulomatosis (WG) occurring 11 days after initiation of therapy with alpha-methyldopa for essential hypertension.

The patient, a 48-year-old white man, experienced the sudden onset of migratory myalgias, fatigue, nightly fevers (103°F orally), and drenching night sweats. One week later, symptoms of arthritis developed—swelling and stiffness of the wrists, fingers, and knees, as well as bilateral conjunctival injection. These symptoms occurred 11 days after methyldopa (250 mg twice daily orally) was substituted for the previous regimen of hydrochlorothiazide and atenolol to improve blood pressure control; they persisted for 6 weeks after the methyldopa therapy was discontinued. For the preceding 2 years, the patient had also been taking allopurinol (100 mg twice daily orally) for hyperuricemia and presumed gout.

In the subsequent 3 weeks, the patient experienced a 5-lb weight loss, worsening vision, frontal and occasionally bitemporal headache, and an erythematous, macular, non-pruritic rash on the trunk, which faded after 10 days. At the time of hospitalization, the methyldopa was discontinued because "adequate blood pressure control" had been achieved. Physical examination revealed the truncal rash as well as a liver span of 20 cm in the midclavicular line. Bilateral scleral and corneal ulcerations were seen. The pupils were dilated to 6–7 mm and unresponsive to light. There was anesthesia of the cornea, nasal vestibules, and labial folds.

Laboratory evaluation revealed a mild anemia. Liver enzymes were elevated up to 6 times normal levels. Urinalysis and renal function test results were normal. Total hemolytic complement was profoundly decreased. Westergren erythrocyte sedimentation rate was 76 mm/hour. Results of a VDRL test, Monospot test, tests for ANA and rheumatoid factor, as well as bacterial, viral, fungal, and mycobacterial cultures of blood, bone marrow, liver, sputum, and stool were negative. Results of a chest radiograph were normal. Computed tomography of the head revealed only a mucous retention cyst in the right maxillary sinus. A temporal artery biopsy specimen was normal. A random nasal biopsy from the right medial turbinate (which healed well) revealed necrotizing granulomatous inflammation with vasculitis. Liver biopsy showed necrosis and granulomatous inflammation with widespread hepatocyte dropout (Figure 1).

The patient was diagnosed as having WG and was transferred for initiation of immunosuppressive therapy. However, it was decided instead to observe the patient before beginning this treatment, and during the next 3

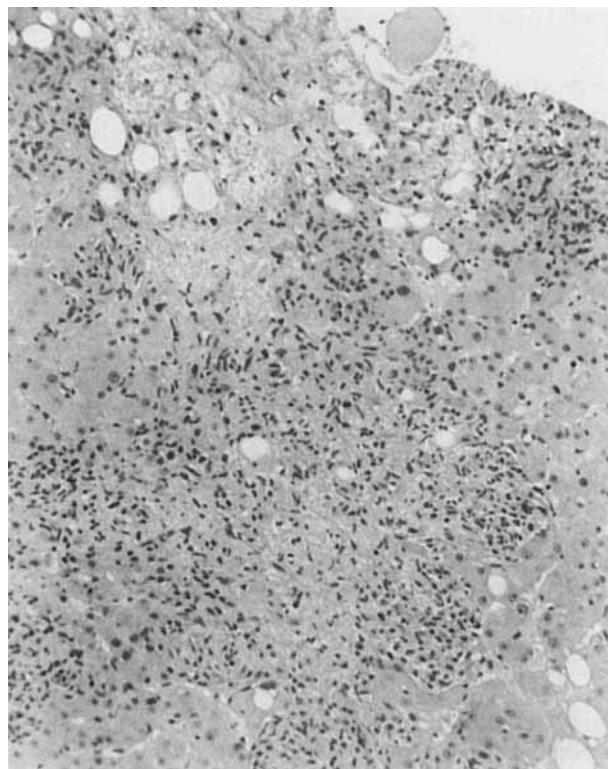


Figure 1. Liver biopsy specimen from a patient with alpha-methyldopa-induced systemic vasculitis. There are wide areas of hepatocyte dropout. Focally, neutrophils are admixed with epithelioid cells (hematoxylin and eosin stained, original magnification $\times 250$).

weeks, the symptoms abated. Results of the physical examination returned to normal, as did the abnormal laboratory parameters. No specific therapy, including cytotoxic drugs, steroids, or nonsteroidal agents, was administered for this condition.

In the recorded cases of hepatic disease resulting from alpha-methyldopa, the onset of the disease was acute in 85% of patients and chronic in the remainder (2). Histologic features of acute methyldopa-induced liver injury range from a mild nonspecific portal and periportal inflammation to an acute, sometimes fulminant hepatocellular injury resembling acute viral hepatitis (3,4). Cellular degeneration, "free" acidophilic bodies, and areas of necrosis are characteristic features. The inflammatory response tends to be concentrated in the portal and periportal zones and consists mainly of lymphocytes and other mononuclear cells with some neutrophils. Tissue eosinophilia is uncommon (2). Bridging necrosis extending between portal areas and from portal to central areas also occurs (3).

Granulomatous hepatitis is not an unusual characteristic of drug-induced hepatotoxicity (5). Granulomatous inflammation is well recognized in the spectrum of vasculitic diseases (6), and in this patient may represent a manifestation of a systemic vasculitis that was initially confused with WG.

Although the patient had symptoms and physical and histologic features of WG, we suggest the illness was caused by methyldopa. Most important, the patient had no evidence of pulmonary or renal involvement, and the disorder resolved without the use of steroids or cytotoxic agents.

Allopurinol can also cause severe hepatic disease, occurring chiefly in patients with renal insufficiency (7). However, the time course of the disease and the normal renal function in this patient provide evidence against allopurinol as the causative agent. Synergy between allopurinol and methyldopa leading to this reaction is a possible, but not previously reported, mechanism of toxicity.

Eric L. Matteson, MD
Thomas D. Palella, MD
*University of Michigan
Ann Arbor, MI*

1. Goodman LS, Gilman A: The Pharmacological Basis of Therapeutics. Sixth edition. New York, Macmillan, 1980
2. Zimmerman H, Maddrey W: Toxic and drug induced hepatitis. Diseases of the Liver. Edited by L Schiff, E Schiff. Philadelphia, JB Lippincott, 1982
3. Maddrey WC, Boitnott JK: Severe hepatitis from methyldopa. *Gastroenterology* 68:351-360, 1975
4. Hoyumpa AM Jr, Connell AM: Methyldopa hepatitis: report of three cases. *Am J Dig Dis* 18:213-222, 1973
5. McMaster KR, Hennig GR: Drug-induced granulomatous hepatitis. *Lab Invest* 44:61-73, 1981
6. Fauci AS, Haynes BI, Katz P: The spectrum of vasculitis: clinical, pathologic, immunologic and therapeutic considerations. *Ann Intern Med* 89:660-676, 1978
7. Hancke KR, Noone RM, Stone WJ: Severe allopurinol toxicity: descriptions and guidelines for prevention in patients with renal insufficiency. *Am J Med* 76:5-47, 1984

Participation of synovial mast cells in intermittent hydrarthrosis

To the Editor:

Recent studies have implicated synovial mast cells in the development and/or perpetuation of synovitis and joint tissue destruction (1). We treated a patient with intermittent hydrarthrosis in whom measurements of plasma and synovial fluid (SF) histamine concentration, together with a complete response to intraarticular steroid injection, provide evidence for the participation of synovial mast cells in this condition.

The patient, a 32-year-old white woman, had an approximately 3-year history of knee arthritis. Her left knee became painful with effusion every 10 days, remained inflamed for about 48 hours, and spontaneously returned to normal. For the next 8 or 9 days, the knee would be completely free of effusion and pain, only to become inflamed again on approximately day 9. The right knee demonstrated an identical periodic pattern of involvement, except for being 3 days "out of phase" with the left knee. History, physical examination, and laboratory studies (serologic studies, erythrocyte sedimentation rate, complete blood count, radiographs, and culture and examination of SF

Table 1. Histamine concentrations in plasma and synovial fluid from a patient with intermittent hydrarthrosis*

Date	Plasma histamine (pg/ml)	Synovial fluid histamine (pg/ml)
8/5/86	ND	640 ± 45
9/16/86	120 ± 10	490 ± 93
10/19/86	500 ± 16	1,270 ± 57
10/28/86	390 ± 17	0 ± 17
11/8/86	110 ± 1	0 ± 39
11/18/86	0 ± 32	0 ± 7
2/8/87	90 ± 16	0 ± 7
2/15/87	0 ± 17	0 ± 6
2/19/87	130 ± 20	0 ± 5
3/12/87	0 ± 5	520 ± 30

* Measurements were taken during the course of the arthritis attacks. Values are the mean ± SEM. ND = not done.

for crystals) failed to reveal a cause of the arthritis. The SF typically contained <5,000 white blood cells (WBC)/mm³. Differential cell counts revealed that up to 90% of the WBC in the fluid were "histiocytes" (actually predominantly synovial lining cells), the balance being lymphocytes and polymorphonuclear cells. Noting these findings, and the undeviating regularity of the attacks, we made a clinical diagnosis of intermittent hydrarthrosis (2).

The paroxysmal and transient nature of these attacks suggested to us that mast cell degranulation might be involved in the pathogenesis of the symptoms. The patient agreed to come to the clinic during her attacks of arthritis for simultaneous arthrocentesis and venous blood sampling for measurement of histamine. The results of these measurements are shown in Table 1.

In each instance in which the SF histamine concentration was measurable, it was higher than the concentration in simultaneously drawn plasma, indicating local release of histamine. Since virtually nothing is known about histamine kinetics in SF, and the patient came to the clinic at varying times after the onset of symptoms, it is difficult to interpret the measurements in which SF histamine was not detectable. In such instances, it is possible that the histamine had been completely metabolized before the samples were taken.

Therapy with oral administration of several nonsteroidal antiinflammatory agents failed to alleviate her symptoms. Data on the use of antihistamine drugs for arthritis are scant and anecdotal, so such therapy was not attempted. There is evidence, however, that intraarticular steroid injection markedly decreases the number of stainable synovial mast cells (1), so we elected to treat one knee with 40 mg of intraarticular triamcinolone acetonide. Injection of the left knee immediately suppressed attacks of arthritis in that joint, while the periodic attacks in the right knee continued without alteration. One month after the injection of the left knee, the right knee was similarly treated, and attacks in that joint abruptly ceased. The patient remained asymptomatic for approximately 10 months before knee swelling began anew. Several years previously, the patient had received an intraarticular steroid injection to her symptomatic knee, and had experienced a symptom-free period of about 1 year.