Movement Disorders
Vol. 14, No. 3, 1999, pp. 512–533

Clinical/Scientific Notes

A Posttraumatic Thalamic Lesion Associated With Contralateral Action Myoclonus

A variety of movement disorders have been described in association with thalamic lesions; they include dystonia, ballism—chorea, asterixis, and repetitive clonic or slow movements (myorhythmia).[1] Myoclonus related to thalamic lesions has been rarely documented.[2,3] We report a patient with a posttraumatic right thalamic lesion which resulted in action myoclonus affecting the contralateral limbs. The myoclonus responded well to sodium valproate. The clinical details and possible mechanisms of myoclonus resulting from a thalamic lesion are discussed.

Case Report

A 16-year-old girl presented with an 8-year history of involuntary movements of the left limbs following a motor vehicle accident in which she was hit by a bus. She was unconscious for 15 days after the accident. As she recovered, she was found to have weakness and involuntary movements on the left side. The weakness gradually improved but the involuntary movements persisted. These were jerky movements mostly involving the lower limbs. The movements were enhanced by volition and were present during sleep. She was unable to suppress the movements.

On examination she had normal higher mental functions and normal cranial nerves. She had MRC grade 4/5 power in the left upper and lower limbs with mild spasticity and hyperreflexia. The left plantar was extensor. There were jerky, repetitive, semirhythmic movements involving the left lower limb consisting of dorsiflexion at the ankle joint and side to side movements. At times there was flexion of the knee and hip joints. These movements were aggravated by posture holding, action, and stress but not by touch or painful stimuli. The left upper limb was also affected by similar involuntary movements but these were less severe than the lower limb. Coordination, gait, and sensation were normal. There were no sustained dystonic movements.

Surface electromyogram (EMG) from the left tibialis anterior showed bursts of muscle activity which became more frequent and rhythmic on posture holding. Most of these EMG bursts lasted 100–200 msec (Fig. 1). Electroencephalogram (EEG) was normal. SSEP to left posterior tibial nerve stimulation showed reduced amplitude compared with the right. SSEP from left median nerve stimulation showed normal N20 but absent N35 and P45 components. BAEPs were normal on both sides. Computed tomography scan of the brain showed a hypodensity in the right posterolateral thalamic region and adjoining internal capsule (Fig. 2). She was treated with 500 mg sodium valproate daily, and the myoclonic jerks subsided completely.

Discussion

Our patient has a right posterolateral thalamic lesion resulting from a head injury. The clinical and EMG features of the involuntary movements indicate myoclonus, and there was no focal epileptiform activity in the EEG. The SSEP abnormalities are compatible with a lesion of the right thalamus and its cortical projections.

Myoclonus is defined as a sudden, brief, shock-like involuntary movement produced by muscle contraction.[4] A pathophysiological classification of myoclonus mentions four varieties—cortical, subcortical, cortical–subcortical, and spinal—that can result in myoclonus. Studies on the neurochemistry of myoclonus have implicated abnormalities in a number of neurotransmitters, such as serotonin, GABA, acetylcholine, and glycine, in different types of myoclonic disorders.[6–9]

Myoclonus is rarely described in thalamic lesions. Avanzini and Broggi[2] described a case report of intention and action myoclonus from a thalamic angioma. More recently Ghika and Bogousslavsky reported[3] three cases of posterior thalamic infarcts with delayed hyperkinetic motor syndromes involving ataxia, tremor, dystonia, myoclonus, and chorea which they called "the jerky, dystonic, unsteady hand."

Dystonia is the most common movement disorder after thalamic lesions.[1] In 10 cases in which the exact location of thalamic lesions causing dystonia was mentioned, the posterior or posterolateral thalamus was involved in six and the paramedian thalamus in four. The occurrence of myoclonic jerks in patients with features of torsion dystonia has been called "myoclonic dystonia."[10] In such cases there is clinical and EMG evidence of underlying sustained dystonic movements and co-contraction with superimposed myoclonic jerks. In our patient there was no evidence of sustained dystonia. Lesions in the ventrolateral nucleus of the thalamus cause asterixis and are used to alleviate dystonic symptoms. Lesions of the subthalamic region produce ballism–chorea.

The functions of the dorsolateral and posterior nuclear groups in the thalamus are not clear. They seem to modulate cortical attention needed for the accurate production of language-related tasks in the left hemisphere and visuospatial tasks in muscle groups. Lack of this suppression could lead to action myoclonus, dystonia, or chorea. Based on our case report and similar case reports of movement disorders, resulting from lesions of the dorsolateral and posterior nuclear groups of the thalamus, we postulate that these nuclei, like the subthalamic nuclei, may be responsible for suppressing unwanted movements during the execution of voluntary movements.

A videotape accompanies this article.

Received January 12, 1996; revision received July 16, 1996. Accepted August 2, 1996.

Address correspondence and reprint requests to P. C. Jacob, MD, DM, College of Medicine, Sultan Qaboos University, P.O. Box 35, Al Khod, Muscat 123, Oman.

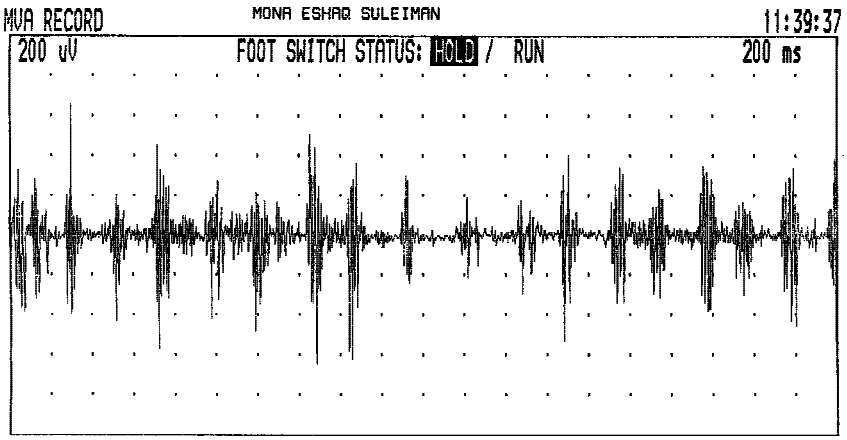

FIG. 1. Surface EMG from left tibialis anterior muscle showing bursts of muscle activity on posture holding.

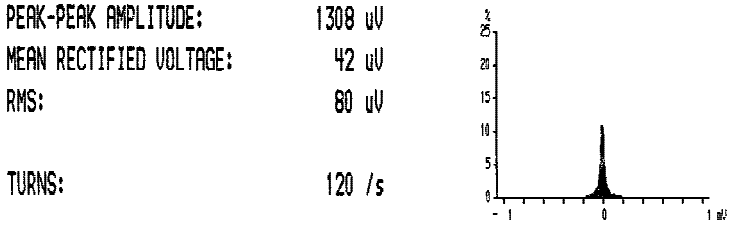

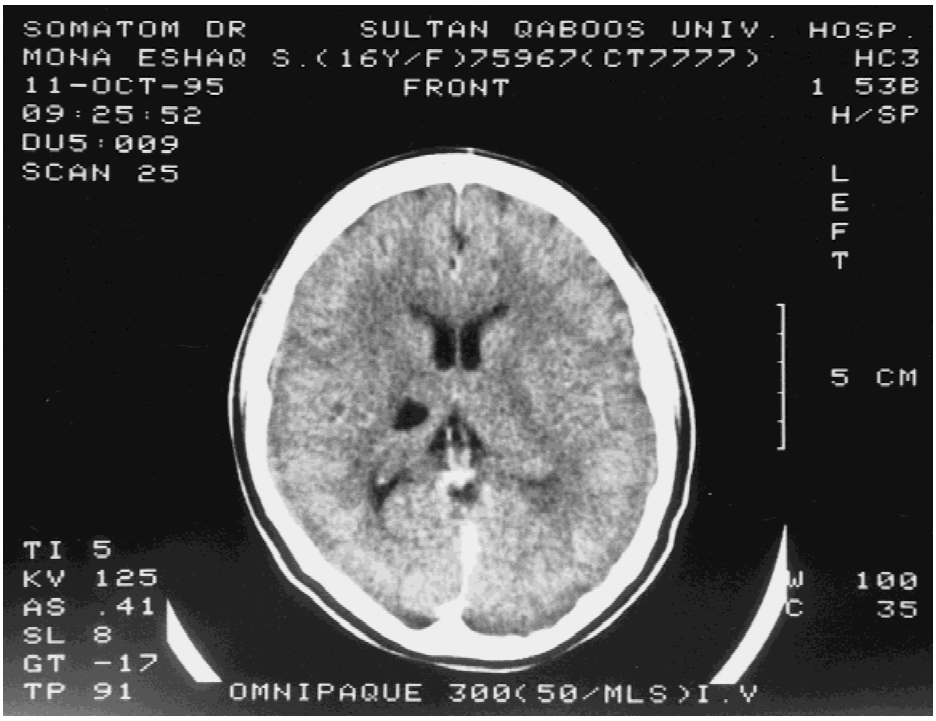

FIG. 2. CT scan of the brain showing a hypodense lesion in the right posterolateral thalamic region and adjoining internal capsule.

Legend to the Videotape

The videotape shows the patient with the limbs initially at rest and later in posture holding. Involuntary rapid, irregular myoclonic jerks are seen mostly affecting the left lower limb. These are enhanced by lifting the leg and holding it extended. The jerks are also present, but to a lesser extent, in the left upper limb.

P. C. Jacob, MD, DM
R. Pratap Chand, DM, FRCP
Department of Neurology (*Medicine*)
Sultan Qaboos University Hospital
Muscat, Oman

References

1. Lee MS, Marsden CD. Movement disorders following lesions of the thalamus or subthalamic region. *Mov Disord* 1994;9:493–507.
2. Avanzini G, Broggi G, Caraceni T. Intention and action myoclonus from thalamic angioma. *Eur Neurol* 1977;15:194–202.
3. Ghika J, Bogousslavsky J, Henderson J, Maeder P, Regli F. The 'jerky dystonic unsteady hand': a delayed motor syndrome in posterior thalamic infarctions. *J Neurol* 1994;241:537–542.
4. Fahn S, Marsden CD, Van Woert MA. Definition and classification of myoclonus. In: Fahn S, Marsden CD, Van Woert MA, eds. *Advances in Neurology, Myoclonus*, vol 43. New York, NY: Raven Press, 1986:1–5.
5. Obeso JA, Artieda J, Martinez-Lage JM. The physiology of myoclonus in man. In: Quinn NP, Jenner PG, eds. *Disorders of Movement.* London: Academic Press Ltd, 1989:437–444.
6. Pranzatelli MR. Serotonin and human myoclonus. *Arch Neurol* 1994;51:605–614.
7. Artieda J, Obeso JA. The pathophysiology and pharmacology of photic cortical myoclonus. *Ann Neurol* 1993;34:175–184.
8. Rektor I, Svejdova M, Silva-Barrat C, Menini C. The cholinergic system-dependent myoclonus of the baboon Papio-papio is a reticular reflex myoclonus. *Mov Disord* 1993;8:28–32.
9. Simon ES. Involvement of glycine and GABA A receptors in the pathogenesis of spinal myoclonus: in vitro studies in the isolated neonatal rodent spinal cord. *Neurology* 1995;45:1883–1892.
10. Obeso JA, Rothwell JC, Lang AE, Marsden CD. Myoclonic dystonia. *Neurology* 1983;33:825–830.
11. Ojemann GA. Common cortical and thalamic mechanisms for language and motor functions. *Am J Physiol* 1984;246:R901–903.

No Increase of Synthesis of (R)Salsolinol in Parkinson's Disease

Only the (R)-enantiomer of salsolinol (SAL) and N-methylsalsolinol (NMSAL) has been detected in human cerebrospinal fluid (CSF), indicating an enantio-selective enzymatic synthesis in the brain.[1] This finding has been addressed as a putative pathophysiological mechanism in Parkinson's disease (PD) and discussed recently.[2,3] The objective of this study was to evaluate differences of stereospecific synthesis of SAL in parkinsonian subjects and control subjects and a possible relationship between plasma and CSF levels of (R)SAL, (S)SAL, and dopamine. We compared 18 previously untreated, so-called "de-novo" parkinsonian patients (age: 62.1 ± 8.4 yrs, range: 44–75 yrs; 8 men, 10 women; duration of PD [physician's estimation according to the patients' complaints]: 17.2 ± 11.2 months [mean ± standard deviation], range: 5–42 months; Hoehn & Yahr stage: 1.6 ± 0.7, range: I–III; Unified Parkinson's Disease Rating Scale: 31.6 ± 14.1, range: 11–63) with age- and sex-matched control subjects (age: 62.1 ± 8.6 yrs, range: 45–75 yrs; 8 men, 10 women). Subjects gave informed consent. We performed lumbar puncture for diagnostic reasons. The local ethical committee approved the study. Plasma and CSF concentrations of (R)SAL, (S)SAL, and dopamine were estimated by high-performance liquid chromatography and calculated from area integrations using a working standard solution of (R)SAL, (S)SAL, and dopamine as a reference. We collected fractions of R-SAL, S-SAL, and dopamine and additionally analyzed them by gas chromatography and mass spectroscopy to confirm the correct identity of the high-performance liquid chromatography found peaks. We calculated CSF/plasma ratios of (R)SAL, (S)SAL, and dopamine. We used the two-tailed Mann-Whitney U test for comparisons and Spearman rank correlation for correlation analysis because of the missing normal distribution of all data. Plasma and CSF levels of (R)SAL, (S)SAL, and dopamine did not differ be-

Received August 4, 1998; revision received December 2, 1998. Accepted January 28, 1999.

Address correspondence and reprint requests to Thomas Müller, MD, Department of Neurology, Ruhr-University of Bochum, St. Josef-Hospital, Gudrunstr. 56, 44791 Bochum, Germany.

TABLE 1. *Comparison of dopamine, (R)SAL, (S)SAL in parkinsonian subjects (PD) and control subjects (CO)**

		PD				CO				
		Mean	SD	Minimum	Maximum	Mean	SD	Minimum	Maximum	p
Dopamine	Plasma	5978.67	2587.60	2520.50	10933.88	6694.13	3948.73	2734.21	19919.97	0.53
Dopamine	CSF	1415.86	1352.06	297.44	5312.43	1512.55	1028.39	397.65	3436.56	0.81
Dopamine	CSF/plasma	0.26	0.27	0.04	1.23	0.27	0.23	0.06	0.88	0.86
(R)SAL	Plasma	441.46	309.06	60.29	988.72	1300.19	2653.99	149.34	10161.62	0.19
(R)SAL	CSF	178.95	192.51	56.82	881.52	426.66	1057.86	47.16	4636.52	0.34
(R)SAL	CSF/plasma	0.78	0.93	0.08	2.96	0.40	0.21	0.08	0.83	0.11
(S)SAL	Plasma	418.09	326.50	96.32	1097.90	851.00	1219.76	89.43	4229.60	0.16
(S)SAL	CSF	158.97	120.22	60.67	525.02	244.85	246.03	69.22	1175.56	0.20
(S)SAL	CSF/plasma	0.70	0.80	0.06	3.47	0.44	0.22	0.07	0.85	0.20

* Levels of dopamine, (R)SAL, (S)SAL are given in pg/mL.
PD, Parkinson's disease; CO, control subjects; SD, standard deviation; CSF, cerebrospinal fluid; (R)SAL, (R)-enantiomer of salsolinol; (S)SAL, (S)-enantiomer of salsolinol.

TABLE 2. *Correlation analysis dopamine, (R)SAL, (S)SAL in parkinsonian subjects (PD) and control subjects (CO)*

Subjects	Variable 1	Variable 2	Spearman r	p
PD	Dopamine plasma	(R)SAL plasma	0.34	0.16
PD	Dopamine plasma	(S)SAL plasma	0.38	0.12
PD	Dopamine CSF	(R)SAL CSF	0.16	0.53
PD	Dopamine CSF	(S)SAL CSF	0.08	0.75
CO	Dopamine plasma	(R)SAL plasma	0.04	0.86
CO	Dopamine plasma	(S)SAL plasma	−0.24	0.33
CO	Dopamine CSF	(R)SAL CSF	0.05	0.84
CO	Dopamine CSF	(S)SAL CSF	−0.13	0.60

PD, Parkinson's disease; CO, control subjects; (R)SAL, (R)-enantiomer of salsolinol; (S)SAL, (S)-enantiomer of salsolinol; CSF, cerebrospinal fluid.

tween parkinsonian subjects and control subjects (Table 1). Dopamine levels in plasma and CSF were not associated with (R)SAL, respectively, (S)SAL, levels in plasma, and CSF in parkinsonian subjects or control subjects (Table 2). No influence of parkinsonian subjects' and control subjects' characteristics, such as sex and age, appeared.

Our results of normal (R)SAL and (S)SAL levels in plasma[4] and CSF in previously untreated parkinsonian subjects do not support the hypothesis of an enantio-selective synthesis of (R)SAL by a putative salsolinol synthase in blood and human brain.[5] Moreover, the missing correlations between levels of (R)SAL, (S)SAL, and dopamine in plasma and CSF do not further strengthen the concept of an enzymatic synthesis of (R)SAL by condensation of dopamine and acetaldehyde through salsolinol synthase. We conclude that described increased CSF levels of NM(R)SAL may be caused by upregulation of N-methylation of (R)SAL, for example, through neutral N-methyl-transferase specific for (R)SAL, and not by an augmented activity of salsolinol synthase.[5,6]

Thomas Müller, MD
Horst Przuntek, MD
Wilfried Kuhn, MD
Department of Neurology
University of Bochum
St. Josef-Hospital
Bochum, Germany

Siedy Sällström Baum, MD
Hans Rommelspacher, MD
Department of Clinical Neurobiology
Benjamin Franklin Hospital of the Free University of Berlin
Berlin, Germany

References

1. Maruyama W, Narabayashi H, Dostert P, Naoi M. Stereospecific occurrence of a parkinsonism-inducing catechol isoquinoline, N-methyl (R)salsolinol, in the human intraventricular fluid. *J Neural Transm* 1996;103:1069–1076.
2. Maruyama W, Abe T, Tohgi H, Dostert P, Naoi M. A dopaminergic neurotoxin, N-methyl (R)salsolinol, increases in parkinsonian cerebrospinal fluid. *Ann Neurol* 1996;40:119–122.
3. Gerlach M, Koutsilieri E, Riederer P. N-methlyl (R)salsolinol and its relevance to Parkinson's disease. *Lancet* 1998;351:850–851.
4. Müller T, Sällsträm Baum S, Häussermann P, et al. Plasma levels of R- and S-salsolinol are not increased in 'de-novo' parkinsonian patients. *J Neural Transm* 1998;105:239–246.
5. Naoi M, Maruyama W, Dostert P, Kohda K, Kaiya T. A novel enzyme enantio-selectively synthesizes (R)salsolinol, a precursor of a dopaminergic neurotoxin, N-methyl (R)salsolinol. *Neurosci Lett* 1996;212:183–186.
6. Naoi M, Maruyama W, Nakao N, et al. (R)Salsolinol N-methyltransferase activity increases in parkinsonian lymphocytes. *Ann Neurol* 1998;43:212–216.

Transient Benefit of Amantadine in Parkinson's Disease: The Facts About the Myth

Amantadine (AM) is an antiviral agent used in the treatment of the Asian flu and is widely prescribed for the treatment of Parkinson's disease (PD). The discovery of its effectiveness in improving the symptoms of PD was first published in 1969 by Schwab et al.[1] They indicated that in 1968 a woman with severe PD was treated with AM to prevent the flu. She experienced a remarkable remission of symptoms which lasted for 6 weeks until the drug was discontinued. To corroborate this report, they then treated 10 patients with PD with this drug and found that seven improved. That result led to a much larger open-label study which spanned over 2 years and was published in two separate reports.[1,2] Since that time, a substantial number of studies were performed which basically were in agreement with those original findings. Over the years, with the approval of a number of other drugs including dopamine agonists, the use became more limited because of its purported modest effect and short duration of action. In more recent times, AM has been resurrected because of its apparent efficacy in the treatment of dyskinesias and fluctuations,[3] its apparent association with increased survival in PD,[4] and the recent finding that it has a pharmacologic effect that inhibits N-methyl-D-aspartic acid (NMDA) receptors.[5] It is this resurgence of AM which has led us to ponder an old issue related to its benefit.

It is generally taught that AM has a transient benefit when used to treat PD. By "transient benefit," it is meant that there is loss of efficacy in 6–12 months. This phenomenon is thought to be related to tachyphylaxis, the rapid appearance of a progressive decrease in response following repetitive administration. This notion is emphasized in general neurology and movement disorder textbooks. In *Merritt's Textbook on Neurology,*[6] it is stated that "the effects of amantadine are short-lived, tending to diminish after a few months." In the movement disorder text by Weiner and Lang,[7] while reviewing the results of the initial paper by Schwab et al., they indicate that "they also noted that the improvement achieved by amantadine administration was transient in many patients lasting only 3–8 months." Weiner and Lang later indicate that "patients can often be managed in this manner for 6–12 months." In the first edition of the textbook edited by Jankovic and Tolosa in 1988 on Parkinson's disease and movement disorders, Jankovic and Marsden state

Received August 18, 1998; revision received December 11, 1998. Accepted December 14, 1998.

Address correspondence and reprint requests to Stewart A. Factor, DO, Parkinson's Disease and Movement Disorders Center of Albany Medical Center, 215 Washington Avenue Extension, Albany, NY 12203, U.S.A.

"while most patients fail to respond after several months . . ."[8] Such comments were deleted in later editions. Not only is this dogma taught by physicians to physicians, but a discussion with a sales representative from the pharmaceutical company that markets Symmetrel (Dupont Pharmaceuticals, Wilmington, DE, U.S.A.) indicated that this was standard teaching for them as well. Our own experience with this drug has led us to question the validity of this "transient benefit" because many of our patients have been maintained for long periods of time without loss of effect. This experience has been shared by others as pointed out by Marsden[9]: "Much has been written about the development of tolerance, or loss of benefit from amantadine. Undoubtedly this occurs, possibly as a result of progression of the disease, but a significant proportion of patients with early disease may be successfully managed on amantadine for years." We have also noted from our experience that in trying to discontinue the drug for one reason or another, patients frequently worsen. This phenomenon has also been reported by Berger and Weiner.[10] We therefore questioned this notion and sought to uncover, through literature review, the origins of the belief that the effect of AM for the treatment of PD is transient.

Methods

After a literature search, we reviewed 22 studies of AM for the treatment of parkinsonism.[1,2,11–30] One study was published in the 1960s, 16 in the 1970s, two in the 1980s, and three in the 1990s. In these studies, 1093 patients with parkinsonism were treated; the majority had PD but some patients also had postencephalitic parkinsonism. One study evaluated AM specifically in multiple system atrophy and progressive supranuclear palsy.[29] Patients studied included those in various stages who were treated or untreated with levodopa. Four of the studies examined the effect of this drug on dyskinesias or motor fluctuations. The duration of therapy ranged from 4 days to 2.5 years. Doses of AM used most commonly were 200 mg per day but ranged from 100–500 mg per day. The methodology in these studies included double-blind, placebo-controlled, crossover or parallel-group studies, open-label, noncontrolled studies, and some trials that had a double-blind portion and an open-label portion.

Results and Discussion

Modest to significant improvement was reported in 12–79% of patients with AM therapy. In 13 studies, decline in efficacy was not mentioned or was not an issue. The range of duration of therapy in these studies was 4 days to 12 months. Schwab et al.,[1,2] in their reports, discussed the occurrence of a decline in efficacy. In their first paper, they mention that there was sustained benefit for 3–8 months. Weiner and Lang,[7] in their quote, mistook this comment as an indication of loss of benefit at that time. However, it actually was the duration that patients were followed and so there was not a loss of benefit at 3–8 months. What Schwab et al.[1] did note was that, between 4 and 8 weeks, a slow but steady reduction in benefit was seen and then it leveled off. They indicated that patients were still improved compared with baseline, and that there was a recurrence of symptoms when the drug was withdrawn which usually would occur within 24 hours. When patients were rechallenged, they again improved to their previous status. They corroborated this finding in their second paper[2] and indicated that a large proportion of the patients continued to have useful responses to the drug after 60 days. When treatment was stopped, there was a loss of benefit within 24 hours even in those who had a decline in benefit. In some patients, an increase in the dose from 200 mg per day to 300 or even 400 mg achieved further benefit. Dallos et al.[11] indicated from their study that by the fourth week, benefit was less significant and a decline of benefit was evident. They pointed out that the greatest benefit was in the first 2 weeks. Hunter et al.[12] reported that a few of their patients thought they had some loss of benefit in 4–8 weeks but this was not seen in their objective assessments. Zeldowicz et al.[13] performed a clinical trial on 77 patients in varying stages of PD to evaluate whether there is a decline in efficacy. Nineteen patients with good to excellent improvement with AM monotherapy maintained that improvement for an average of 21 months with the longest duration being 30 months. In addition, a marked deterioration took place when AM was switched, in a random fashion, to placebo. In patients treated with a combined therapy of AM and levodopa, there also was no decline in responsiveness and there was a worsening of their symptoms with a blinded switch from AM to placebo. Fahn and Isgreen[14] also performed a long-term trial to examine the decline in efficacy of AM. This was a complicated 13-month trial with three double-blind, crossover phases for AM and placebo. On initiation of the study, untreated patients were initiated with either AM or placebo and treated for 1 month. Levodopa was then added and on two occasions (at month 6 and at month 12), randomized, double-blind, crossover studies of AM and placebo were performed leaving levodopa doses stable. Initially 70% of patients responded to AM. By the end of a year, 50% of patients maintained responsiveness. However, response to AM was not consistent throughout the entire year. Some initial nonresponders later responded to AM when they were concomitantly receiving levodopa, and some initial responders were no longer responding to AM once levodopa was added. Therefore, many patients maintained benefit while some did not. There certainly was no obvious trend that patients lost efficacy after a number of months of therapy with AM.

With regard to the treatment of motor fluctuations, literature is scant. Shannon et al.[27] treated 20 patients with motor fluctuations with AM in an open-label fashion. Sixty-five percent of patients improved at 3 months but the improvement lasted an average of 5.7 months. This suggested a transient benefit for motor fluctuations. However, Adler et al.[28] demonstrated, in a small number of patients, that response of fluctuations could last up to 2 years. Verhagen-Metman et al.[30] also examined the effect of AM on dyskinesia and fluctuations and, while they discovered a 60% improvement in dyskinesias, the treatment duration was only 3 weeks, and it was not possible to make any conclusions about the duration of benefit. This requires further study.

From this review, we conclude that there is no consistent transient period of benefit in patients with PD when treated with AM. Certainly, there has been no literature to suggest that there is a period of benefit that lasts between 6 and 12 months. There was, however, in two studies, an indication that some patients will lose some of their benefit in the first 4–8 weeks but this decline is partial and most patients maintain some long-term benefit. We think neurologists should not decide to withdraw AM based on the misconception that there is a transient period of responsiveness. It could result in worsening of PD or the development of acute delirium.[10,31] Treatment

should be individualized, as is true with all other antiparkinsonian medications. The notion of "transient benefit" of AM should be eliminated from standard teaching practices about this drug.

Acknowledgments: This paper was supported by the Albany Medical Center Parkinson's Research Fund and the Riley Family Chair in Parkinson's Disease (S.A.F.).

Stewart A. Factor, DO
Eric S. Molho, MD
Department of Neurology
Albany Medical College
Albany, New York, U.S.A.

References

1. Schwab RS, England AC, Poskanzer DC, Young RR. Amantadine in the treatment of Parkinson's disease. *JAMA* 1969;208:1168–1170.
2. Schwab RS, Poskanzer DC, England AC, Young RR. Amantadine in Parkinson's disease: review of more than two years' experience. *JAMA* 1972;222:792–795.
3. Rajput AH, Uitti RJ, Lang AE, Rajput AH, Kumar R, Galvez-Jimenez N. Amantadine ameliorates levodopa induced dyskinesia [Abstract]. *Neurology* 1997;48:A328.
4. Uitti RJ, Rajput AH, Ahlskog JE, et al. Amantadine treatment is an independent predictor of improved survival in Parkinson's disease. *Neurology* 1996;46:1551–1556.
5. Stoof JC, Booij J, Durkarch B, Wolters EC. The anti-parkinsonian drug amantadine inhibits the N-methyl-D-aspartic acid-evoked release of acetylcholine from rat striatum in a noncompetitive way. *Eur J Pharmacol* 1992;213:439–443.
6. Rowland L. *Merritt's Textbook on Neurology*, 8th ed. Philadelphia, PA: Lea and Febiger, 1989.
7. Weiner WJ, Lang AE. *Movement Disorders: a Comprehensive Survey.* Mount Kisco, NY: Futura Publishing Co, 1989.
8. Jankovic J, Marsden CD. Therapeutic strategies in Parkinson's disease. In: Jankovic J, Tolosa E, eds. *Parkinson's Disease and Movement Disorders.* Baltimore, MD: Urban & Schwarzenberg, 1988:95–120.
9. Marsden CD. The drug therapy of early Parkinson's disease. In: Stern MB, Hurtig HH, eds. *The Comprehensive Management of Parkinson's Disease.* New York, NY: PMA Publishing Corp, 1988:79–88.
10. Berger JR, Weiner WJ. Exacerbation of Parkinson's disease following the withdrawal of amantadine. *Neurology* 1985;35(suppl 1):200.
11. Dallos V, Heathfield K, Stone P, Allen FAD. Use of amantadine in Parkinson's disease. Results of a double-blind trial. *BMJ* 1970;4:24–26.
12. Hunter KR, Stern GM, Laurence DR, Armitage P. Amantadine in parkinsonism. *Lancet* 1970;i:1127–1129.
13. Zeldowicz LR, Huberman J. Long-term therapy of Parkinson's disease with amantadine, alone and combined with levodopa. *Can Med Assoc J* 1973;109:588–593.
14. Fahn S, Isgreen WP. Long-term evaluation of amantadine and levodopa combination in parkinsonism by double-blind crossover analyses. *Neurology* 1975;25:695–700.
15. MacFadyen DJ, Picton TW, Zeldowicz L, McGeer PL. Amantadine-HCL in the treatment of Parkinson's disease: a controlled trial. *J Clin Pharmacol* 1972;12:274–279.
16. Fehling C. The effect of adding amantadine to optimum L-dopa dosage in Parkinson's syndrome. *Acta Neurol Scand* 1973;49:245–251.
17. Merrick EM, Schmitt PP. A controlled study of the clinical effects of amantadine hydrochloride (Symmetrel). *Current Therapeutic Research* 1973;15:552–558.
18. Butzer JF, Silver DE, Sahs AL. Amantadine in Parkinson's disease: a double-blind, placebo-controlled, crossover study with long-term follow-up. *Neurology* 1975;25:603–606.
19. Parkes JD, Baxter RC, Marsden CD, Rees JE. Comparative trial of benzhexol, amantadine, and levodopa in the treatment of Parkinson's disease. *J Neurol Neurosurg Psychiatry* 1974;37:422–426.
20. Pearce J, Rao NS. Amantadine in parkinsonism. *Lancet* 1970;ii:1091–1092.
21. Fieschi C, Nardini M, Casacchia M, Tedone ME, Robotti E. Amantadine for Parkinson's disease. *Lancet* 1970;i:945–946.
22. Mann DC, Pearce LA, Waterbury LD. Amantadine for Parkinson's disease. *Neurology* 1971;21:958–962.
23. Parkes JD, Zilkha KJ, Calver DM, Knill-Jones RP. Controlled trial of amantadine hydrochloride in Parkinson's disease. *Lancet* 1970;i:259–262.
24. Parkes JD, Zilkha KJ, Marsden P, Baxter RCH, Knill-Jones RP. Amantadine dosage in treatment of Parkinson's disease. *Lancet* 1970;i:1130–1133.
25. Bauer RB, McHenry JT. Comparison of amantadine, placebo, and levodopa in Parkinson's disease. *Neurology* 1974;24:715–720.
26. Webster DD, Sawyer GT. The combined use of amantadine HCL and levodopa/carbidopa in Parkinson's disease. *Current Therapeutic Research* 1984;35:1010–1013.
27. Shannon KM, Goetz CG, Carroll VS, Tanner CM, Klawans HL. Amantadine and motor fluctuations in chronic Parkinson's disease. *Clin Neuropharmacol* 1987;10:522–526.
28. Adler CH, Stern MB, Vernon G, Hurtig HI. Amantadine in advanced Parkinson's disease: good use of an old drug. *J Neurol* 1997;244:326–327.
29. Rajput AH, Uitti RJ, Fenton ME, George D. Amantadine effectiveness in multiple system atrophy and progressive supranuclear palsy. *Parkinsonism & Related Disorders* 1998;4:211–214.
30. Verhagen-Metman L, Del Dotto P, van den Munckhof P, Fang J, Mouradian MM, Chase TN. Amantadine as treatment for dyskinesias and motor fluctuations in Parkinson's disease. *Neurology* 1998;50:1323–1326.
31. Factor SA, Molho ES, Brown DL. Acute delirium after withdrawal of amantadine in Parkinson's disease. *Neurology* 1998;50:1456–1458.

The NMDA Antagonist Budipine Can Alleviate Levodopa-Induced Motor Fluctuations

Although levodopa therapy is the most effective treatment in Parkinson's disease (PD), prolonged administration of this drug is associated with the development of motor complications (fluctuations, dyskinesia), which constitute a major source of disability. The treatment of fluctuations remains one of the most unsatisfying issues in the therapy of PD. The exact mechanism underlying fluctuating responses and dyskinesias is unknown. Recent experimental studies[1,2] suggest that postsyn-

Received October 10, 1997; revisions received January 28 and July 21, 1998. Accepted January 26, 1999.

Address correspondence and reprint requests to Sybille Spieker, MD, Department of Neurology, University of Tübingen, Hoppe-Seyler-Str. 3, D-72074 Tübingen, Germany.

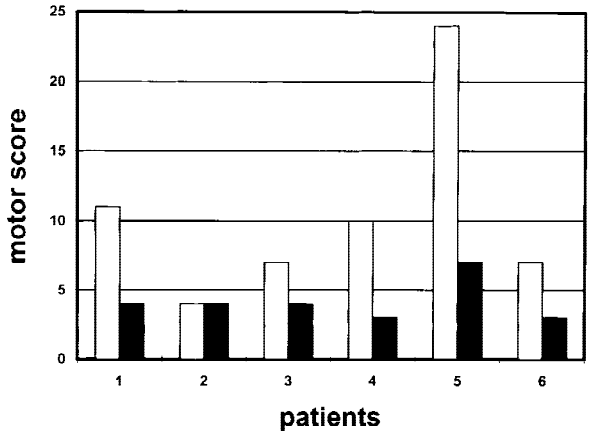

FIG. 1. Improvement of UPDRS motor score during "on." Open bars: baseline; filled bars: with treatment.

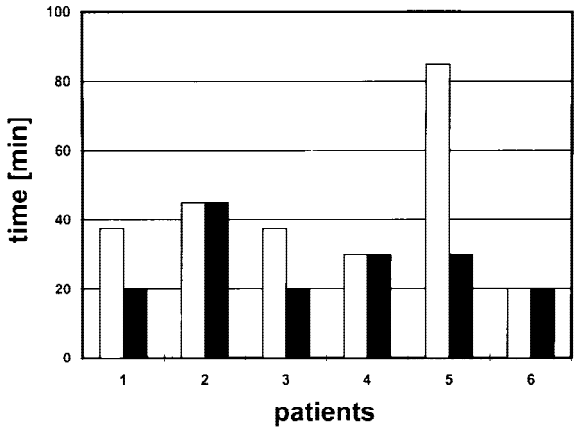

FIG. 3. Time to onset of levodopa response. Open bars: baseline; filled bars: with treatment.

aptic mechanisms mediated by striatal N-methyl-D-aspartate (NMDA) receptors may contribute to the long-term changes of motor response in levodopa-treated patients. In addition, memantine, an aminoadamantine derivative with NMDA-antagonistic properties, decreased motor complications in 10 patients with advanced PD.[3] We have recently shown that budipine (1-*t*-butyl-4,4-diphenylpiperidine), which was recently approved as an antiparkinsonian drug in Germany,[4] has NMDA antagonistic properties.[5] In the present study, we assessed the capacity of budipine to alleviate response fluctuations in six patients with wearing-off in an open study design.

Methods

Patients

Seven patients (five men, two women) entered the study. Mean age was 55.6 years (range, 36–70 yrs). Disease duration was 7.5 years (range, 6–11 yrs). Six patients were Hoehn and Yahr (H & Y) stage II; one was H & Y III. Patients had fluctuations for 26 months on average (range, 13–60 months).

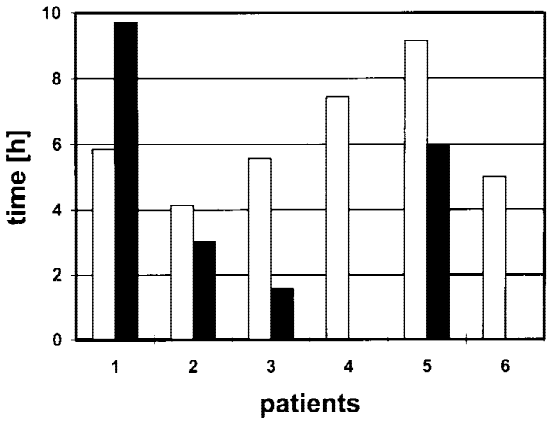

FIG. 2. Decrease in daily "off" time. Open bars: baseline; filled bars: with treatment.

All patients had wearing-off; none had random fluctuations or peak-dose dyskinesias. One had off-dystonia. Levodopa medication varied from 250–700 mg per day given in four to seven single doses. All patients were on 10 mg selegiline and 15–30 mg bromocriptine. These medications were kept constant throughout the study. All patients gave informed consent.

Study Medication

Budipine was given as an add-on therapy. Starting dose was 10 mg per day. Budipine was increased by 10 mg per day each week up to a stable dose of 40 mg given orally (10 mg four times a day). Patients were treated with this stable dose for another 4 weeks.

Assessment

Assessment was done before initiation of treatment with budipine and 4 weeks after reaching the stable dose, that is, 8 weeks after starting budipine. The motor section of the Unified Parkinson's Disease Rating Scale (UPDRS) was performed during "on" by one of the authors (S.S.). Patients kept a diary marking full hours of "on/off" phases and of dyskinesias/dystonia during 7 days preceding the office visit. They were asked to specify the average time from medication intake to onset of levodopa response. Schwab & England scores in "on" and "off" were taken. Because of the small number of patients, no significance tests were performed.

Results

Four patients experienced a slight dryness of the mouth. No other anticholinergic symptoms developed. One patient did not tolerate the drug because of dizziness (not related to postural hypotension) at a dose of 20 mg per day and discontinued the study. In the remaining six, motor scores during "on" improved in five patients (average improvement in all patients: 6.3 ± 5.9 hrs; Fig. 1). Time "off" decreased in five patients (average decrease in all patients: 2.8 ± 3.9 hrs; Fig. 2). Improvement in "off" time was not observed in the patient with dystonia. However, off-dystonia completely disappeared in this patient. Peak-dose dyskinesia did not occur in any of the patients. Time to

onset of levodopa response decreased in three patients (average decrease in all patients: 15.0 ± 21.4 min; Fig. 3). Schwab & England scores in "off" were increased in four patients (average increase in all patients: 6.7 ± 5.2%). Schwab & England scores in "on" were unchanged. All six patients opted to remain on budipine after completion of the study.

Discussion

The main result of this pilot study is that budipine improved levodopa-induced motor complications in all patients who completed the study.

Budipine is an effective antiparkinsonian drug but its precise mechanism of action is poorly understood. It remains effective in patients with advanced Parkinson's disease who have a poor response to levodopa.[6] Budipine has effects on a variety of neurotransmitter systems.[7–10] However, none of these effects can entirely explain its clinical efficacy. It has previously been shown that, in addition to weak antimuscarinergic effects, budipine displays low affinity to the channel binding site of NMDA receptors and possesses NMDA antagonistic activity in animal models and in in vitro preparations of striatal slices.[5,11,12]

There is a convergence of cortical glutaminergic and nigral dopaminergic inputs on medial spiny neurons of the striatum.[13] Chronic levodopa therapy is thought to cause upregulation of postsynaptic striatal NMDA receptors which may then mediate motor response complications. Accordingly, in animal models of Parkinson's disease, NMDA antagonists not only potentiate the motor effects of levodopa,[14] but also reverse the effects of chronic levodopa administration on D1 and D2 agonist-induced rotational behavior[15] and reverse levodopa-induced motor complications.[1,2] Because intrastriatal injection of MK-801 in hemiparkinsonian rats prolonged levodopa response in rats chronically treated with levodopa,[1] it seems likely that the striatum is indeed a site of action of NMDA antagonists when improving motor complications. However, there may be further sites, such as the subthalamic nucleus and the internal pallidum,[14] that are involved in the beneficial action of NMDA antagonists in PD.

We therefore propose that the beneficial effect on motor fluctuations observed in the present study may be the result of NMDA antagonistic properties of budipine. Human studies on the efficacy of NMDA antagonists in Parkinson's disease[3,17–19] have so far given contradictory results or have demonstrated a high rate of intolerable side effects. It will therefore be necessary to confirm our findings with a larger patient group in a controlled study, and it will be of further interest to investigate whether budipine can also improve random fluctuations and dyskinesia.

Acknowledgment: The authors thank Promonta Lundbeck GmbH, Hamburg, for supplying budipine.

Sybille Spieker, MD
Peter-Andreas Löschmann, MD
Thomas Klockgether, MD
Department of Neurology
University of Tübingen
Tübingen, Germany

References

1. Papa SM, Boldry RC, Engber TM, Kask AM, Chase TN. Reversal of levodopa-induced motor fluctuations in experimental parkinsonism by NMDA receptor blockade. *Brain Res* 1995;701:13–18.
2. Papa SM, Chase TN. Levodopa-induced dyskinesias improved by a glutamate antagonist in parkinsonian monkeys. *Ann Neurol* 1996; 39:574–578.
3. Rabey JM, Nissipeanu P, Korczyn AD. Efficacy of memantine, an NMDA receptor antagonist, in the treatment of Parkinson's disease. *J Neural Transm Park Dis Dement Sect* 1992;4:277–282.
4. Jellinger K, Bliesath H. Adjuvant treatment of Parkinson's disease with budipine: a double-blind trial versus placebo. *J Neurol* 1987; 234:280–282.
5. Klockgether T, Jacobsen P, Loschmann PA, Turski L. The antiparkinsonian agent budipine is an N-methyl-D-aspartate antagonist. *J Neural Transm Park Dis Dement Sect* 1993;5:101–106.
6. Siegfried J, Fischer R. Budipine: a new chemical substance in the treatment of Parkinson's disease. In: Gerstenbrand F, Poewe W, Stern G, eds. *Clinical Experiences With Budipine in Parkinson Therapy.* Berlin Heidelberg: Springer, 1985:152–157.
7. Przuntek H, Stasch J-P. Biochemical and pharmacological aspects of the mechanism of action of budipine. In: Gerstenbrand F, Poewe W, Stern G, eds. *Clinical Experiences With Budipine in Parkinson Therapy.* Berlin Heidelberg: Springer, 1985:107–112.
8. Jackisch R, Huang HY, Reimann W, Limberger N. Effects of the antiparkinsonian drug budipine on neurotransmitter release in central nervous system tissue in vitro. *J Pharmacol Exp Ther* 1993; 264:889–898.
9. Menge HG, Brand U. Pharmacologic bases of antiparkinsonian therapy. In: Gerstenbrand F, Poewe W, Stern G, eds. *Clinical Experiences With Budipine in Parkinson Therapy.* Berlin Heidelberg: Springer, 1985:82–92.
10. Offermeier J, van Rooyen JM. The pharmacodynamics of budipine on central neurotransmitter systems. In: Gerstenbrand F, Poewe W, Stern G, eds. *Clinical Experiences With Budipine in Parkinson Therapy.* Berlin Heidelberg: Springer, 1985:93–106.
11. Klockgether T, Wüllner U, Steinbach JP, Petersen V, Turski L, Löschmann PA. Effects of antiparkinsonian drugs on central neurotransmitter systems. *Eur J Pharmacol* 1996;301:67–73.
12. Jackisch R, Kruchen A, Sauermann W, Hertting G, Feuerstein TJ. The antiparkinsonian drugs budipine and biperiden are use-dependent (uncompetitive) NMDA receptor antagonists. *Eur J Pharmacol* 1994;264:207–211.
13. Kotter R. Postsynaptic integration of glutamatergic and dopaminergic signals in the striatum. *Prog Neurobiol* 1994;44:163–196.
14. Klockgether T, Turski L. NMDA antagonists potentiate antiparkinsonian actions of L-dopa in monoamine-depleted rats. *Ann Neurol* 1990;28:539–546.
15. Boldry RC, Papa SM, Kask AM, Chase TN. MK-801 reverses effects of chronic levodopa on D1 and D2 dopamine agonist-induced rotational behavior. *Brain Res* 1995;692:259–264.
16. Bonuccelli U, Del Dotto P, Piccini P, Behge F, Corsini GU, Muratorio A. Dextromethorphan and parkinsonism [Letter]. *Lancet* 1992;340:53.
17. Montastruc JL, Rascol O, Senard JM, Rascol A. A pilot study of N-methyl-D-aspartate (NMDA) antagonist in Parkinson's disease [Letter]. *J Neurol Neurosurg Psychiatry* 1992;55:630–631.
18. Montastruc JL, Fabre N, Rascol O, Senard JM, Blin O. N-methyl-D-aspartate (NMDA) antagonist and Parkinson's disease: a pilot study with dextromethorphan [Letter]. *Mov Disord* 1994;9:242–243.

Parkinsonism From Methanol Poisoning: Benefit From Treatment With Anti-Parkinson Drugs

Methanol or methyl alcohol has been recognized as a potent central nervous system toxin since around the turn of the century when large amounts of the alcohol became commercially available. In countries without sophisticated hospitals, large outbreaks of methanol intoxication usually result in mortality rates up to 12%.[1,2] Current treatment regimens, including rapid correction of the acidosis with intravenous bicarbonate, preventing conversion of methanol to its toxic metabolite (formic acid) using ethanol, and efficient elimination of methanol from blood by hemodialysis, result in the survival of most patients.[3] However, survivors may be left with devastating neurologic or visual sequelae. In this report, we present a patient who developed bilateral hemorrhagic necrotic putaminal lesions and moderately severe parkinsonism following methanol poisoning. The patient benefited from treatment with moderately large doses of anti-Parkinson medications.

Case History

A 30-year-old, previously healthy man consumed an estimated 150 mL of windshield wiper fluid containing 40% methanol in an apparent suicide attempt. Three hours later he developed nausea, vomiting, and the presence of "big white spots" in his eyes. Eight hours after ingestion, he became comatose and was admitted to the intensive care unit with a Glasgow coma score of 3. His respiratory rate soon fell to below 10/min, necessitating endotracheal intubation and mechanical ventilation.

Blood tests on admission were remarkable for depression of bicarbonate (<5 meq/L) and an increased anion gap of 35. Serum lactate was normal. Arterial blood gas showed metabolic acidosis with a pH of 6.93, CO_2 of 14.4 mm Hg, and bicarbonate of 6.7 mMol/L. The following toxicology blood and urine screens were normal: general toxicology screen for recreational drugs, carboxyhemaglobulin and methhemaglobulin levels, and serum salicylate level. The serum ethanol and isopropanol levels were 0 mg/dL but serum methanol level was 176 mg/dL (toxic >20 mg/dL). Computed tomography (CT) of the head on admission demonstrated decreased attenuation in the putamina bilaterally with decreased grey-white differentiation in the cortex consistent with brain edema (Fig. 1A).

The patient received 2 L normal saline as a bolus, intravenous ethanol and bicarbonate, and emergency hemodialysis that continued for several hours until the blood methanol level was not detectable. Over the next 7 days, the patient remained comatose. CT on day 7 showed bilateral necrosis and hemorrhage of the basal ganglia and diffuse cerebral edema (Fig. 1B). On awakening the patient had a moderate right hemiparesis. Near visual acuity was estimated to be 20/30 by Snellen chart.

Received November 24, 1998; revision received January 28, 1999. Accepted February 15, 1999.

Address correspondence and reprint requests to Larry E. Davis, MD, FACP, Chief, Neurology Service, VA Medical Center, 1501 San Pedro Ave. SE, Albuquerque, NM 87108, U.S.A.

Over the next 3 weeks the patient steadily improved. Full voluntary movements returned in his limbs, he followed commands, and fed himself. Six weeks after intoxication, global mental function was mildly impaired as measured by the Mini Mental Status score (21 of 30). Speech was produced sparingly in a nearly inaudible whisper. Distant visual acuity was estimated to be 20/200 bilaterally with no improvement through a pin hole. Funduscopic examination revealed bilateral pallor of the optic nerve heads. Motor examination demonstrated a profoundly bradykinetic subject with masked facies and sialorrhea. Strength was normal in all limbs but fine motor coordination was impaired in both hands. Moderate cogwheel rigidity was present in all limbs. He had painful dystonic posture of his right foot characterized by plantar flexion and inversion at the ankle with extension of the great toe. The patient walked with a shuffling gait and had substantial impairment of postural reflexes.

Flash visual evoked potential testing was severely attenuated and prolonged in both eyes. Magnetic resonance imaging (MRI) scans on hospital days 57 and 106 demonstrated necrotic lesions in both putamina with extension into the heads of the caudate (Fig. 1C).

Methods and Results

With the agreement of the patient, he was given, in a blinded fashion, varying regimens of either vitamins (as placebo) or varying doses of carbidopa/levodopa, bromocriptine, or both. Each dose of medication was given for at least 1 day before examination. On higher doses, the drug was administered for 1–2 weeks before testing. Testing lasted 12 weeks with similar doses of medication being given on different weeks. Examination was performed 2 hours after the last dose of medication under similar conditions by a neurologist who was blinded to the medication. Scoring was done using the Unified Parkinson's Disease Rating Scale (UPDRS) motor subscale.[4]

The UPDRS score improved 28% when the patient was on carbidopa/levodopa, 34% on bromocriptine, and 72% on both medicines at the maximum dosage (Fig. 2). UPDRS scores were one point higher on the left side. After 1 month on 75/750 mg carbidopa/levodopa per day and 22.5 mg bromocriptine per day, the carbidopa/levodopa was reduced to 50/500 mg per day with definite worsening of Parkinson signs. The patient experienced no side effects of either medication until the carbidopa/levodopa was above 75/750 mg when the patient developed confusion and hallucinations requiring the dosage to be lowered. Motor fluctuations and dyskinesias have not developed. On medication, the dystonic foot improved to where he could wear shoes without discomfort. However, his distant visual acuity remained at 9/200 bilaterally and optic atrophy developed.

Discussion

Methanol is a common industrial solvent. It is a clear, colorless, volatile liquid with a weak odor and is slightly sweeter than ethanol.[5] Worldwide, outbreaks of methanol poisoning most commonly occur from the illegal adulteration of ethanol with methanol or substitution of ethanol with methanol.[1,6] Solitary or small numbers of cases usually occur from ingestion of industrial or household products that contain methanol.[7,8] Windshield wiper fluid is the most common home product containing methanol that is consumed in accidental or suicidal

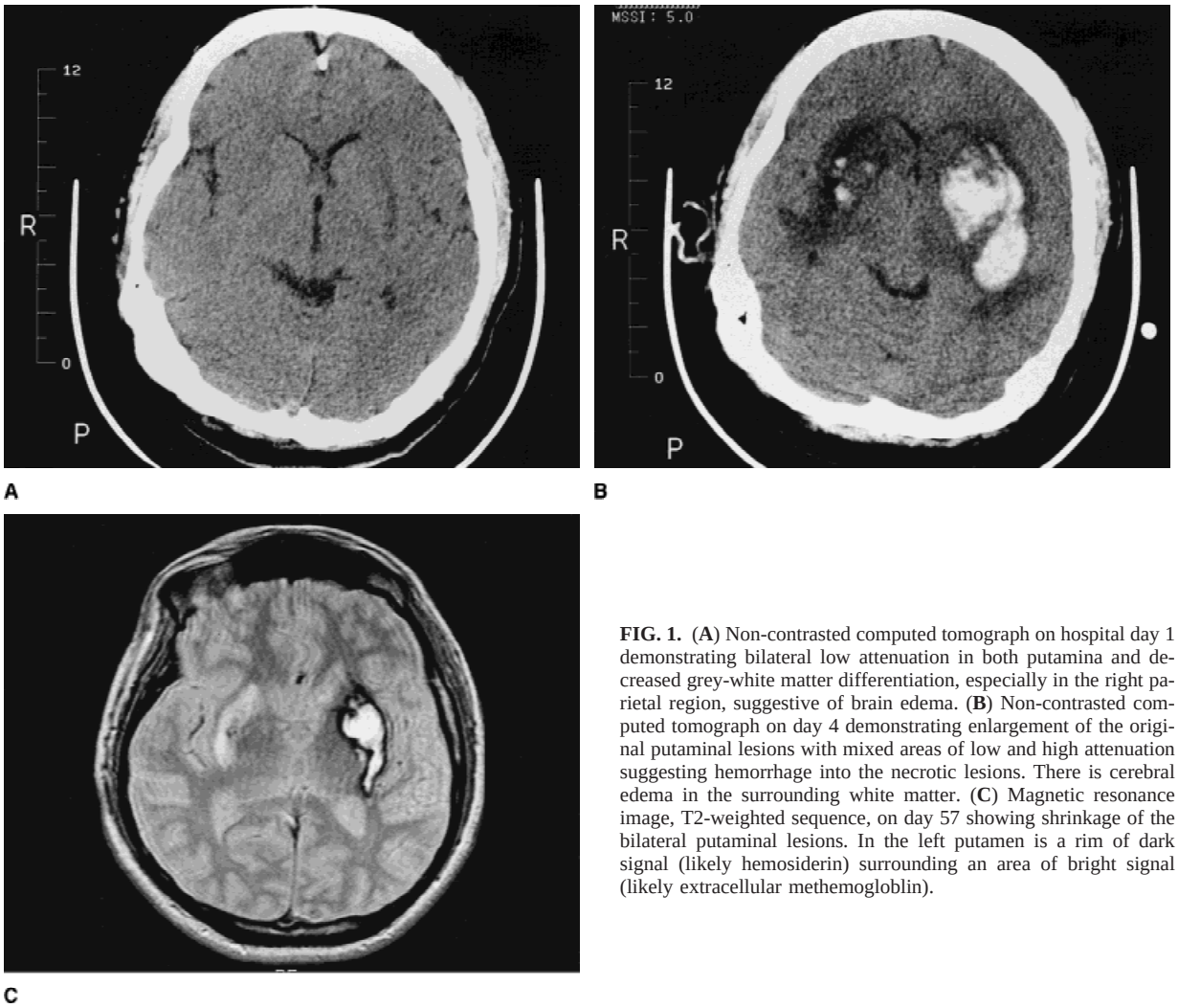

FIG. 1. (**A**) Non-contrasted computed tomograph on hospital day 1 demonstrating bilateral low attenuation in both putamina and decreased grey-white matter differentiation, especially in the right parietal region, suggestive of brain edema. (**B**) Non-contrasted computed tomograph on day 4 demonstrating enlargement of the original putaminal lesions with mixed areas of low and high attenuation suggesting hemorrhage into the necrotic lesions. There is cerebral edema in the surrounding white matter. (**C**) Magnetic resonance image, T2-weighted sequence, on day 57 showing shrinkage of the bilateral putaminal lesions. In the left putamen is a rim of dark signal (likely hemosiderin) surrounding an area of bright signal (likely extracellular methemogloblin).

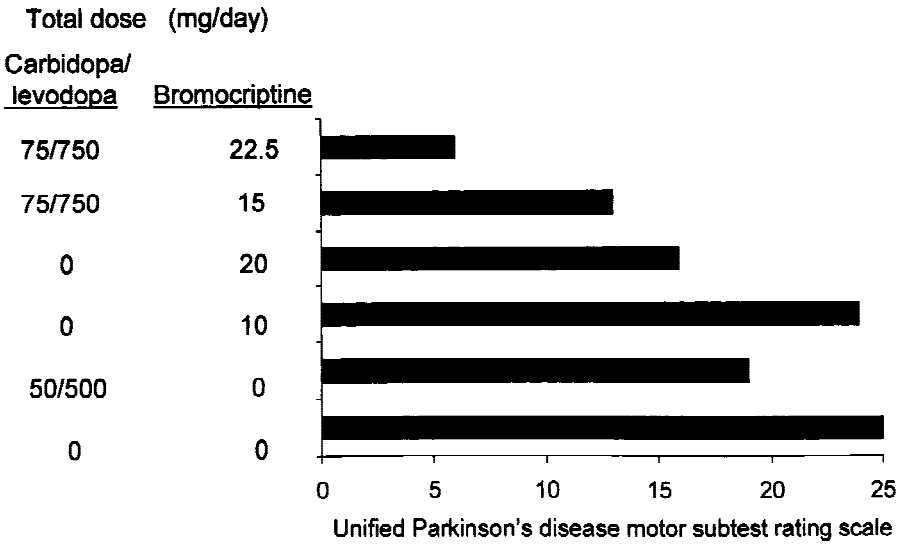

FIG. 2. Graph showing clinical response as measured by the Unified Parkinson's Disease Rating Scale, motor subset, to varying doses of anti-Parkinson disease medications.

methanol poisonings.[9–12] Methanol poisoning causes widespread cortical and cerebellar neuronal loss.[6,13] In addition, severe methanol poisoning has a striking propensity to cause necrosis of the basal ganglia, particularly the putamina.[6,8,11,13–20] Often the necrotic lesion spontaneously becomes hemorrhagic, but hemodialysis with systemic heparinization may increase the risk of hemorrhage.[8] Putaminal lesions are increasingly being recognized by CT or MRI and are usually bilateral and hemorrhagic.[11,12,15–20] The lesions may be confined to the putamen or extend into the head of the caudate and adjacent white matter. In addition, neuroimaging may demonstrate localized areas of cerebral edema, necrosis, and hemorrhage in the cortex, subcortical white matter, cerebellum, brain stem, and optic nerve.[11,15,17]

Patients who survive methanol poisoning may develop parkinsonism[9,13,21–23] or a mixture of pyramidal and extrapyramidal signs.[24] Based on available case studies, it appears that those with necrotic putaminal lesions are at higher risk of developing parkinsonism. Whereas some patients spontaneously improve, others are left with permanent features of parkinsonism.[9,12,20] Clinical features commonly include masked facies, drooling, bradykinesia, shuffling gait with a stooped posture, hypophonic speech, cogwheeling, and minimal or absent resting tremor. Our patient, and others, have also manifested limb and foot dystonia.[12,18,19]

Until now it was unclear whether these patients benefited from treatment with carbidopa/levodopa. Some articles reported no clinical improvement,[20] whereas others found modest benefit from carbidopa/levodopa.[9,13] However, both the degree and type of improvement and details on the dosage administered have been limited. In our patient, we found that administration of moderately large doses of carbidopa/levodopa and bromocriptine resulted in considerable clinical improvement.

The response we observed to both dopamine precursors and agonists suggests that methanol partially damages the nigrostriatal pathway but in this case left sufficient pre- and postsynaptic neurons intact to benefit from medication.

Acknowledgment: The authors thank the following individuals for their excellent care of this patient: Helen Busby, MD, Paul Montner, MD, Kathleen Haaland, PhD, Roland Lee, MD, Jose Tapia, MD, John Shonk, MD, Janice Knoefel, MD, Kathy Halverson, OD, Paula Boggs, Marissa Alaniz, Marta Gonzalez, and Paula Jones-Irvin.

Larry E. Davis, MD, FACP
Neurology Service
Veterans Affairs Medical Center
Albuquerque, New Mexico, U.S.A.
Departments of Neurology, Neuroscience, and Microbiology
University of New Mexico
School of Medicine
Albuquerque, New Mexico, U.S.A.

John C. Adair, MD
Neurology Service
Veterans Affairs Medical Center
Albuquerque, New Mexico, U.S.A.
Department of Neurology
University of New Mexico
School of Medicine
Albuquerque, New Mexico, U.S.A.

References

1. Bennett IL, Cary FH, Mitchell GL, Cooper MN. Acute methyl alcohol poisoning: a review based on experiences in an outbreak of 323 cases. *Medicine* 1953;32:431–463.
2. Naraqi S, Dethlefs RF, Stobodniuk RA, Sairere JS. An outbreak of acute methyl alcohol intoxication. *Aust N Z J Med* 1979;9:65–68.
3. Ekins BR, Rollins DE, Duffy DP, Gregory MC. Standardized treatment of severe methanol poisoning with ethanol and hemodialysis. *West J Med* 1985;142:337–340.
4. Weiner WJ, Lang AE. Unified Parkinson's Disease Rating Scale. In: *Movement Disorders—A Comprehensive Survey*. Mt Kisco, NY: Futura, 1989:687–725.
5. Von Burg R. Methanol toxicology update. *J Appl Toxicol* 1994; 14:309–313.
6. Mittal BV, Desai AP, Khade KR. Methyl alcohol poisoning: an autopsy study of 28 cases. *J Postgrad Med* 1990;37:9–13.
7. Keyvan-Larijarni H, Tannenberg AM. Methanol intoxication. Comparison of peritoneal dialysis and hemodialysis treatment. *Arch Intern Med* 1974;134:293–296.
8. Phang PT, Passerini L, Mielke B, Berendt R, King G. Brain hemorrhage associated with methanol poisoning. *Crit Care Med* 1988; 16:137–140.
9. Guggenheim MA, Couch JR, Weinberg W. Motor dysfunction as a permanent complication of methanol ingestion. *Arch Neurol* 1971;24:550–554.
10. Gonda A, Gault H, Churchill D, Hollomby D. Hemodialysis for methanol intoxication. *Am J Med* 1978;64:749–758.
11. Glazer M, Dross P. Necrosis of the putamen caused by methanol intoxication: MR findings. *AJR* 1993;160:1105–1106.
12. LeWitt PA, Martin SD. Dystonia and hypokinesis with putaminal necrosis after methanol intoxication. *Clin Neuropharmacol* 1988; 11:161–167.
13. McLean DR, Jacobs H, Mielke BW. Methanol poisoning: a clinical and pathologic study. *Ann Neurol* 1980;8:161–167.
14. Erlanson P, Fritz H, Hagstam K-E, Liljenberg B, Tryding N, Voigt G. Severe methanol intoxication. *Acta Med Scand* 1965;177:393–408.
15. Gaul HP, Wallace CJ, Auer RN, Fong TC. MR findings in methanol intoxication. *AJNR* 1995;16:1783–1786.
16. Mozaz MJ, Wyke MA, Indakoetxea B. Parkinsonism and defects of praxis following methanol poisoning. *J Neurol Neurosurg Psychiatry* 1991;54:843–844.
17. Pelletier J, Habib MH, Khalih R, Salamon G, Bartoli D, Jean P. Putaminal necrosis after methanol intoxication. *J Neurol Neurosurg Psychiatry* 1992;55:234–235.
18. Chen JC, Schneiderman JF, Wortzman G. Methanol poisoning: bilateral putaminal and cerebellar cortical lesions on CT and MR. *J Comput Assist Tomogr* 1991;15:522–524.
19. Ganguly G, Banerjee A, Mukherjee S, Das SK, Maity B. Bilateral basal ganglia hemorrhage—uncommon manifestation of methanol poisoning. *J Assoc Physicians India* 1996;44:834–835.
20. Indakoetxea B, Lopez de Munain A, Marti-Masso JF, Linazasoro G. Parkinsonismo tras intoxicacion por alcohol metilico. *Neurologica* 1990;5:238–241.
21. Verslegers W, Van Den Kerchove M, Crols R, De Potter W, Appel B, Lowenthal A. Methanol intoxication: parkinsonism and decreased met-enkephalin levels due to putaminal necrosis. *Acta Neurol Belg* 1988;88:163–171.
22. Oliveras Ley C, Galindo Gali F. Parkinsonian syndrome after methanol intoxication. *Eur Neurol* 1983;22:405–409.
23. Riegel VH, Wolf G. Schwere neurologische ausfalle als folge einer methylalkoholvergiftung. *Fortschr Neurol Psychiatr* 1966;34:346–351.
24. Scrimgeour EM. Outbreak of methanol and isopropanol poisoning in New Britain, Papua, New Guinea. *Med J Aust* 1980;2:36–38.

Central Pontine and Extrapontine Myelinolysis Presenting With Parkinsonism in a Patient With Cystic Fibrosis

Central pontine myelinolysis (CPM) is a disorder characterized by pseudobulbar palsy and tetraplegia often associated with impairment of consciousness.[1] Pathologically, there is symmetric destruction of myelin in the central portion of the pons. CPM has been described with chronic alcohol abuse, malnutrition, liver disease, rapid correction of hyponatremia and hypernatremia. Pathologic studies have disclosed the presence of destruction of myelin at additional sites outside the pons, including the basal ganglia.[2,3] Clinical evidence of extrapontine myelinolysis (EPM) is, in most cases, thought to be masked by CPM. Extrapyramidal disorders may occur occasionally as sequelae of typical CPM but are less frequently the presenting feature.[4] We report a case of EPM in a patient with cystic fibrosis presenting with parkinsonism.

Case History

A 26-year-old man with cystic fibrosis was admitted after traveling for 3 months in southern India. Three weeks before admission he became ill with malaise, vomiting, and abdominal pain. The vomiting stopped after 24 hours but he continued to be nauseous and developed hiccups and cramps in his limbs. He became increasingly agitated with visual hallucinations and, 10 days into the illness, started to vomit again. He was then admitted to a local hospital in India where, according to their records, he was found to be febrile, drowsy, and dehydrated. Electrolytes on admission were normal and blood films for malaria were negative. He was treated with intravenous fluids and tobramycin. The nature and rate of the fluid replacement was not documented in his records. The fever settled and he began to improve, but after 3 days he developed dysarthria and difficulty chewing. His arms became stiff and clumsy. These symptoms progressed during the week before his return to the UK. He had not received any neuroleptic medication and there was no history of alcohol abuse.

On admission, he was alert and orientated but agitated and disinhibited. There was marked hypomimia and drooling. He was severely dysarthric. Postural reflexes were impaired and there was mild gait ataxia. Arm swing was absent bilaterally. Pursuit eye movements were fragmented. He had difficulty opening his jaw and facial movement was diminished. He was unable to protrude his tongue or move it within his mouth. There was marked rigidity of the arms with profound bradykinesia and an intermittent rest tremor. Power in the limbs was normal. The tendon reflexes were symmetric and both plantar responses were flexor. There was mild lower limb ataxia. Sensation was normal. He was afebrile but was clubbed and appeared malnourished. Abdominal examination revealed splenomegaly.

T2-weighted magnetic resonance imaging (MRI) of the brain (Fig. 1) showed increased signal in the caudate and putamen bilaterally. There was also an area of increased signal in the center of the pons consistent with CPM. Cerebrospinal fluid examination was normal. Electrolytes and plasma glucose were normal. Liver enzymes were abnormal (ALP 194, gamma GT 164, ALT 57 IU/l) and the INR was prolonged at 1.9. Serum copper was slightly elevated at 24.9 μmol/L (normal range 11–21 μmol/L), but ceruloplasmin was normal and there were no Kaiser-Fleischer rings seen on slit lamp examination. Thyroid function, antinuclear factor, serum lactate, and urinary organic acids were normal. Japanese B encephalitis, mycoplasma, and legionella serology were negative.

He was treated with intravenous vitamins and started on 62.5 mg Madopar (levodopa and benserazide; Roche Products Ltd., U.K.) three times per day. The dose of Madopar was gradually increased to 187.5 mg three times per day, and this was associated with improvement in the dysarthria, rigidity, and bradykinesia. His course was complicated by a chest infection but this responded to treatment with ceftazidime and gentamicin. After 2 months, the extrapyramidal signs had resolved completely and the Madopar was successfully withdrawn.

Discussion

This patient presented with a subacute onset of parkinsonism with abnormalities on MRI consistent with EPM. Although few details of the illness and treatment in India are known, risk factors included vomiting, liver disease (secondary to cystic fibrosis), and poor nutrition related partly to diet and partly to variable compliance with pancreatic enzyme supplements. The plasma sodium concentration was reported to be normal on admission to a hospital in India, but there are likely to have been significant shifts in plasma osmolality as a result of the illness and treatment. Other potential causes for the extrapyramidal syndrome and signal change in the striatum were considered but investigation proved negative. In view of the additional changes in the pons, which were consistent with CPM, EPM was thought to be the most likely cause.

Extrapyramidal syndromes are more often seen as the typical features of CPM resolve than at presentation, but even this is uncommon and dystonia is more frequent than parkinsonism.[4] Four patients presenting with subacute parkinsonism have been reported previously.[5–8] In patients developing extrapyramidal syndromes as sequelae of typical CPM, MRI has shown either normal appearances in the basal ganglia or focal areas of signal change in the striatum.[4] In contrast, those patients presenting with subacute parkinsonism, in which adequate MRI has been available, have had diffuse signal change in the caudate and putamen with sparing of the globus pallidus[5,7,8] as in our patient. Our patient and two of the other reported cases also had radiologic appearances consistent with CPM which was clinically silent.[5,6] The explanation for the lack of pallidal involvement is unclear.

Psychiatric manifestations were present in three of the four previously reported patients presenting with parkinsonism.[5–7] In one of these patients, the parkinsonism only developed after exposure to haloperidol,[7] and it is possible that the striatal

A videotape accompanies this article.

Received October 31, 1997; revision received January 28, 1998. Accepted June 8, 1998. Complete documentation received January 20, 1999.

Address correspondence and reprint requests to Martin C. Prevett, DM, MRCP, National Hospital for Neurology and Neurosurgery, Queen Square, London, WC1N 3BG, U.K.

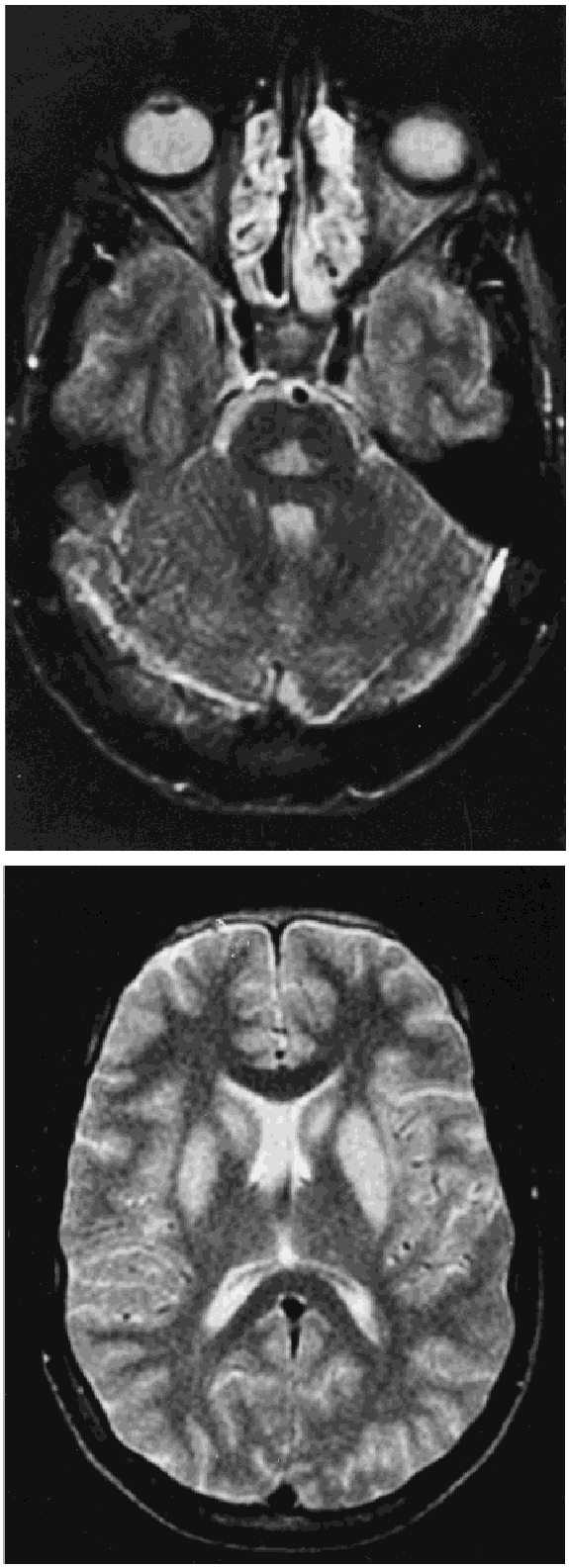

FIG. 1. T2-weighted axial MRI showing (**A**) increased signal in the central pons and (**B**) symmetric, diffuse increased signal in the caudate and putamen bilaterally, sparing the globus pallidus.

myelinolysis rendered the patient more susceptible to the antidopaminergic effects of haloperidol. Our patient exhibited agitation and disinhibition, but he was not exposed to any neuroleptic medication.

Our patient began to improve following treatment with levodopa. The symptomatic improvement may have been the result of treatment, but it is also possible that initiation of treatment coincided with the onset of spontaneous recovery. In two of the previously reported patients, improvement coincided with initiation of levodopa[5,6] but one had persistent parkinsonism despite treatment.[8] Details of treatment and outcome in the other patient were not documented.[7]

CPM and EPM have not been reported previously in cystic fibrosis. This is perhaps surprising given that patients with cystic fibrosis are at risk of hyponatremia as a result of a variety of mechanisms. Potential causes include liver disease and inappropriate ADH secretion secondary to chest infections. Peculiar to cystic fibrosis is the susceptibility to hyponatremic dehydration as a result of sodium loss with excessive sweating,[9] although the risk from this is probably minimized by advice to take sodium supplements when in hot climates.

In summary, despite potential risk factors, as far as we are aware, this is the first reported case of CPM/EPM in a patient with cystic fibrosis. Patients with CPM may rarely present with symptoms and signs reflecting concurrent EPM. Those presenting with parkinsonism are characterized radiologically by diffuse signal change in the caudate and putamen sparing the globus pallidus. During the acute stage, symptomatic relief may be obtained by treatment with levodopa. Complete resolution of symptoms is possible, although one patient has been reported with persistent parkinsonism.

Legend to the Videotape

At the beginning, the patient is counting revealing a severe dysarthria. A rest tremor is also evident. Eye movements are full but pursuit is jerky. There is a lack of facial movement with drooling, and tongue movement is severely impaired. Severe upper limb bradykinesia is demonstrated. The gait is characterized by a slightly stooped posture and absence of arm swing.

Acknowledgment: The authors thank Professor D. M. Geddes, Royal Brompton Hospital, for referring this patient and for his comments on the manuscript.

Martin C. Prevett, DM, MRCP
Martin N. Rossor, MA, MD, FRCP
National Hospital for Neurology and Neurosurgery
Queen Square
London, U.K.

References

1. Adams RD, Victor M, Mancall EL. Central pontine myelinolysis: a hitherto undescribed disease occurring in alcoholic and malnourished patients. *Arch Neurol* 1959;81:154–172.
2. Wright DG, Laureno R, Victor M. Pontine and extrapontine myelinolysis. *Brain* 1979;102:361–385.
3. Gocht A, Colmant HJ. Central pontine and extrapontine myelinolysis: a report of 58 cases. *Clin Neuropathol* 1987;6:262–270.
4. Maraganore DM, Folger WN, Swanson JW, Ahlskog JE. Movement disorders as sequelae of central pontine myelinolysis: report of three cases. *Mov Disord* 1992;7:142–148.
5. Dickoff DJ, Raps M, Yahr MD. Striatal syndrome following hy-

ponatremia and its rapid correction; a manifestation of extrapontine myelinolysis confirmed by magnetic resonance imaging. *Arch Neurol* 1988;45:112–114.
6. Tinker P, Anderson MG, Anand P, Kermode A, Harding AE. Pontine myelinolysis presenting with acute parkinsonism as a sequelae of corrected hyponatremia. *J Neurol Neurosurg Psychiatry* 1990; 53:87–88.
7. Schimrigk S, Amoiridis G. Extrapontine myelinolysis. *J Neurol Neurosurg Psychiatry* 1996;61:250.
8. Tomita I, Satoh H, Satoh A, Seto M, Tsujihata M, Yoshimura T. Extrapontine myelinolysis presenting with parkinsonism as a sequelae of rapid correction of hyponatremia. *J Neurol Neurosurg Psychiatry* 1997;62:422–423.
9. Smith HR, Dhatt GS, Melia WMA, Dickinson JG. Cystic fibrosis presenting as hyponatremic heat exhaustion. *BMJ* 1995;310:579–580.

Severe Akinetic Syndrome Resulting From a Bilateral Basal Ganglia Lesion Following Bone Marrow Transplantation

Bone marrow transplantation (BMT) is a well-established treatment for otherwise fatal disorders of hematopoiesis. However, allogeneic BMT, which requires chronic immunosuppressive therapy after transplantation, is associated with a high rate of complications, including neurologic disturbances, which are reported to occur in 60–70% of cases.[1] We report the case of a patient who developed a severe akinetic syndrome with long-lasting freezing episodes and profound postural impairment as a result of bilateral basal ganglia lesions mainly involving the globus pallidus 6 months following allogeneic BMT.

Case Report

A previously healthy 21-year-old man underwent allogeneic BMT because of myelodysplastic syndrome subclassified refractory anemia. The donor was a HLA-identical but AB0-major-incompatible brother. One month after BMT the patient was discharged in good general condition and prescribed 300 mg cyclosporine A twice a day. He kept well but developed aregeneratoric anemia and remained red cell transfusion-dependent. The patient's hematologic course has been described in detail in a separate report.[2]

Six months after BMT, the patient suddenly developed a severe gait disturbance with frequent falls. On admission to the hospital he was severely akinetic. Repeated dystonic movements, which were more marked in the upper than in the lower limbs, were evident. No meningeal or other focal signs, especially corticospinal or cerebellar, were found. Laboratory tests revealed moderate anemia, mild thrombocytopenia, and leukopenia. Other results, including serum electrolytes, kidney and liver function tests, C-reactive protein, lactate, and cerebrospinal fluid (CSF), were normal.

Magnetic resonance imaging (MRI) showed T1-weighted hypointense, Gd-DTPA-enhancing, and T2-weighted hyperintense lesions symmetrically in the lentiform nuclei extending caudally into the upper parts of the cerebral peduncules including the substantia nigra. Pathologic changes did not include the anterior commissure (Figs. 1 and 2, left).

L-dopa/benserazide at a dosage up to 300 mg/75 mg per day did not show any beneficial effect. While taking 2 mg trihexyphenidyl given three times per day, only the dystonia resolved. Cortical magnetic stimulation and visual evoked potentials were normal. A computed tomography scan 3 weeks after admission showed marked improvement with only slight hypodensities in the basal ganglia. Anemia improved and the patient did not require further red cell substitution.

However, akinetic symptoms persisted. On admission to the neurologic department 1 year after BMT, the patient showed a masked face with reduced blinking frequency and poverty and episodic long-lasting freezing of the head, trunk, and limb movements. The patient did not speak spontaneously and when asked answered with a delay of some seconds to minutes in severely slurred, low, and monotonous speech. He showed profound difficulties in closing his eyes voluntarily. Lid opening and extraocular movements were normal. Muscle tone always appeared to be slightly reduced and no tremor was observed. There was a subtle reduction of dexterity of fine finger movements and fatiguing of repetitive movements. However, the patient was able to eat, wash, and dress unaided. He could rise from a chair without pushing off with his arms. Posture was almost normal with a normal base, but the patient displayed bizarre positions with his head bent back and to one side, arms adducted, and elbows and wrists flexed. These slow tonic cervical and upper limb movements often occurred as well during freezing episodes in the sitting position. The patient showed marked postural instability and frequent falls. In response to a push forward and from a lateral position, he recovered after taking a few steps but he fell back without any attempt to avoid falling in response to the slightest pull on his shoulders. His gait was severely affected, predominantly characterized by hypotonia of the swinging leg, sometimes resulting in crossing of the legs during gait. Stride length and speed were only mildly reduced. Eye closure did not worsen the patient's postural deficits.

MRI follow up revealed symmetric T1-weighted hypointense and T2-weighted hyperintense sharply delineated lesions involving both pallidal segments. Spin-density images featured hyperintensity resulting from gliosis. No Gd-DTPA enhancement could be seen (Fig. 1, right). Midbrain lesions had vanished but atrophy of the cerebral peduncules characterized by a decrease of their size and widening of the interpeduncular and upper vermian cisterns was evident (Fig. 2, right). β-CIT-SPECT as a marker of the integrity of nigrostriatal dopaminergic neurons showed mild binding reduction in the right putamen (5.8) but nearly normal binding in the left striatum (6.7) excluding severe damage to the substantia nigra pars compacta (striatum/cerebellum ratios, normal range 7–10; for methods see reference 3). IBZM-SPECT demonstrated moderately reduced striatal dopamine D2 receptor density (1.5) (striatum/frontal cortex ratio, normal range 1.6–1.8; reference 4).

Electro-oculogram and electroencephalogram were normal.

A videotape accompanies this article.

Received January 20, 1997; revisions received August 1, 1997, October 17, 1997, and February 11, 1998. Accepted December 1, 1998.

Address correspondence and reprint requests to Walter Pirker, MD, Department of Neurology, Vienna General Hospital, University of Vienna, Währinger Gürtel 18-20, A-1090 Wien/Vienna, Austria.

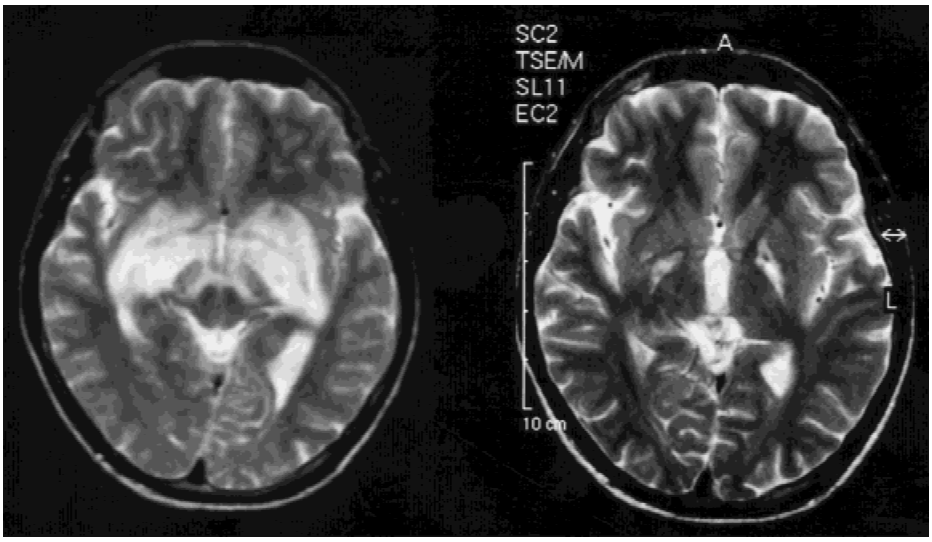

FIG. 1. Axial T2-weighted MRI images at the level of the anterior commissure in the acute phase (left) and 1 year later (right) showing hyperintense symmetric basal ganglia lesions in the acute state (left) and sharply delineated hyperintensities involving both pallidal segments in the chronic state (right).

Neuropsychologic testing showed reduced verbal fluency (five "S" words in 3 min) and abnormalities in the Wisconsin Card Sorting Test (two categories) but normal intelligence, attention, short-term memory, verbal memory, and paired associate learning. Psychiatric symptoms such as apathy, blunting of affect, or obsessive-compulsive behavior were absent. On the contrary, the patient was well aware of his motor deficits and highly motivated to improve his condition.

Therapeutic trials with 200 mg amantadine sulfate intravenously daily, 12 g piracetam intravenously, up to 1000/250 mg L-dopa/benserazide daily, and up to 3 mg pergolide per day were ineffective. More than 3 years after onset the patient's severe akinetic syndrome remains unchanged.

Discussion

The most common neurologic complications following BMT are central nervous system (CNS) infections, vascular events, and encephalopathy.[1] A CNS infection seems unlikely in this case because of the lack of fever, systemic signs of inflammation, meningeal signs, and CSF abnormalities at the onset of neurologic symptoms. Extrapontine myelinolysis seems unlikely because isolated involvement of the basal ganglia is extremely rare[5] and because electrolytes were normal. Laboratory tests revealed no signs of hepatic or renal failure as possible causes of metabolic encephalopathy.

Treatment-related leukoencephalopathy is a rare complication of BMT and may occur as a consequence of preparatory regimens days to months after BMT.[1] Recently, encephalopathy with parkinsonian symptoms in children treated with BMT and high-dose amphotericin B were reported.[6] The lesions were widespread with extensive involvement of the white matter. Transient parkinsonism and diffuse white matter lesions were observed in patients during cyclosporine treatment as well.[7] However, our patient exhibited an almost exclusive lesion of the basal ganglia and extrapyramidal symptoms were persistent.

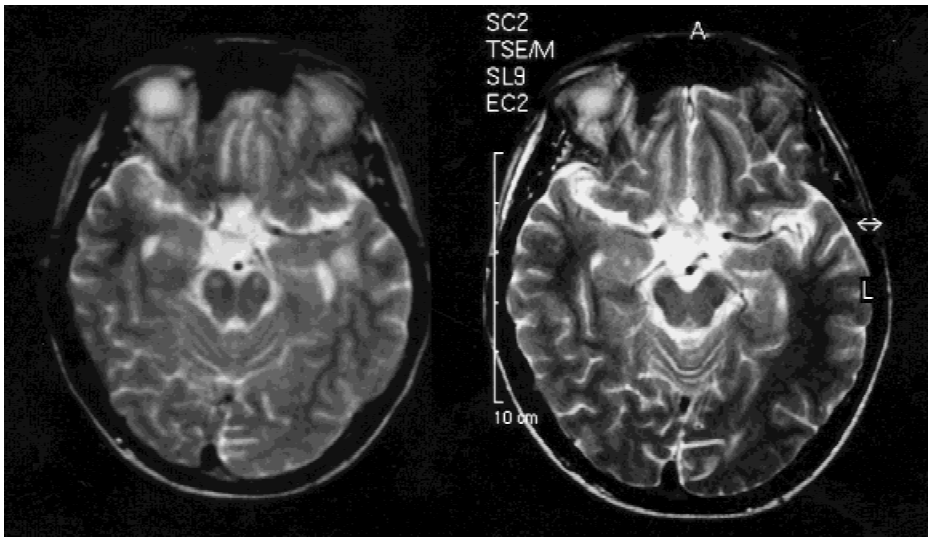

FIG. 2. Axial T2-weighted MRI images at the level of the midbrain in the acute phase (left) and 1 year later (right) showing symmetric hyperintensities in the cerebral peduncules in the acute state (left) and atrophy of the cerebral peduncules characterized by a decrease of their size and widening of the interpeduncular and upper vermian cisterns in the chronic state (right).

Bilateral lesions of the basal ganglia are well-known sequelae of hypoxic–ischemic and various toxic insults to the brain including carbon monoxide, cyanide, and carbon disulfide poisoning.[8] These lesions may be large and involve the caudate nucleus, the putamen, and the GP or are restricted to one of these nuclei. Bilateral lesions of the GP are often associated with lesions in the pars reticulata of the substantia nigra. This stereotypical topographic pattern of damage led to the concept of a selective vulnerability of the basal ganglia to hypoxic insults (for review, see reference 8). The lesion in our patient may have been a consequence of long-standing anemia before and after BMT in combination with a transient hypoxic event or chronic toxicity.

The outstanding clinical features of our patient were akinesia with long-lasting freezing episodes and profound postural impairment. Moreover, mild dystonia was evident, especially during freezing. The occurrence of akinesia in bilateral GP lesions is not predicted by current concepts of basal ganglia function.[9–11] According to the prevailing model, akinesia is a result of overactivity of the indirect pathway, and lesioning of the internal segment of GP (GPi) should result in hyperkinesia or in improvement of akinesia.[12] One explanation for the development of akinesia in our patient would be that the lesion did not involve Gpi. However, the MRI studies strongly suggest extensive damage of both segments of GP.

Marsden and Obeso, in their recent review on the role of the basal ganglia in motor control, emphasize that lesioning of the output structures of the basal ganglia and the thalamus paradoxically does not result in akinesia.[13] These authors point out that bilateral GP lesions in the vast majority do not produce akinesia and, if they do, then they predominantly cause axial symptoms.[13] In a review of 240 patients with basal ganglia lesions, only 9% had parkinsonism.[14] Of 15 patients with isolated bilateral GP lesions, four had mild parkinsonian features including bradykinesia, rigidity, postural instability, and postural tremor.[14] In contrast, our patient displayed akinesia with profound speech, gait and postural impairment without tremor and rigidity. Five patients with similar akinetic syndromes with predominant axial motor dysfunction without rigidity and resting tremor as a result of bilateral GP lesions have been reported by Haaxma[15] and Feve.[16]

Recent findings by the Grenoble group suggest that electrical stimulation of certain parts of GPi can lead to akinesia.[17] In a study, the effect of stimulation on different parts of GPi was investigated in patients with Parkinson's disease following implantation of quadripolar electrodes for therapeutic reasons. Stimulation of the most dorsally located electrodes alleviated akinesia. Stimulation of the most ventral electrodes led to a decrease in rigidity, effectively suppressed L-dopa-induced dyskinesias, but at the same time blocked the anti-akinetic effect of L-dopa.[17] Assuming that stimulation results in inhibition of neuronal elements in proximity to the electrodes, the finding of an increase in akinesia following stimulation of ventral parts of GPi would support the hypothesis that the akinetic syndrome in our patient is the consequence of involvement of the most ventral parts of GPi.

The dominating akinetic symptoms in our patient were deficits in voluntary movement initiation and long-lasting freezing episodes accompanied by dystonia. Freezing episodes with dystonic posturing such as in our case were evident in two of the four cases reported by Feve et al.[16] Freezing could be overcome by external stimuli, and perceptual and cognitive functions appeared to be preserved during these episodes. Concerning differential diagnosis, supplementary sensorimotor area (SMA) seizures can be excluded on clinical grounds. SMA seizures are characterized by abrupt, brief tonic posturing of the extremities. They start and end suddenly and typically last only 10–40 seconds.[18] These features are in marked contrast with the freezing phenomena in our patient which frequently lasted for several minutes. Moreover, SMA seizures usually occur predominantly during sleep,[18] whereas our patient exhibited his attacks exclusively during wakefulness. Long-lasting freezing episodes are more frequently encountered in vascular parkinsonism and in normal pressure hydrocephalus than in idiopathic Parkinson's disease, and are attributed to frontal lobe and white matter lesions in these conditions.[19] In patients with GP lesions, disruption of striatopallidothalamic output to cortical projection areas, especially the SMA, may be the functional basis for the same clinical symptomatology.

Like all four patients of Feve et al.[16] and Haaxma's case,[15] our patient had severe postural impairment. Because of the contrast between the severe axial deficits and only mild impairment of limb movements, Haaxma et al. hypothesized that the GP lesion in their case may have interfered with descending pathways to brain stem locomotor centers and further to reticulospinal pathways which are involved in the control of axial structures and posture.[15] This may account as well for our patient in whom MRI demonstrated damage to midbrain structures, likely involving projections to the mesencephalic locomotor region[20] and possibly involving this structure itself.

Apart from extrapyramidal symptoms, basal ganglia lesions frequently result in behavioral changes. Forty-six percent of the 240 patients with basal ganglia lesions included in the review by Bhatia and Marsden had some behavioral disorder, most commonly abulia, which occurred in 13% of all patients.[14] Lesions in abulic patients in the vast majority of cases involved the caudate nucleus, but abulia was seen as well in four of 15 patients with isolated bilateral GP lesions.[14] In contrast, psychiatric symptoms, especially apathy or blunting of emotional responses, were absent in our patient. Neuropsychologic testing revealed selective impairment in verbal fluency and in the Wisconsin Card Sorting Test. These tests have been shown to be sensitive to frontal lobe dysfunction.[21] Similar cognitive changes have been found in Haaxma's patient in a more detailed neuropsychologic study.[22]

In conclusion, we report an akinetic syndrome with long-lasting freezing episodes and profound postural impairment resulting from a bilateral globus pallidus lesion following BMT. The occurrence of akinesia in bilateral globus pallidus lesions, although described rarely and in a minority of these patients, is difficult to reconcile with current concepts of basal ganglia function. The predominantly axial type of motor disturbance in this and in similar cases might be caused by additional damage to descending pathways to brain stem structures involved in axial motor function.

Legends to the Videotape

Segment 1 illustrates the patient's bizarre gait characterized by hypotonia of the swinging leg, sometimes resulting in crossing of the legs during walking. Postural instability with lack of response on a pull test.

Segment 2 shows a long-lasting freezing episode with a dystonic rotation of the head to the left occurring during neu-

rologic examination. Freezing can be overcome by an external stimulus (throwing of a ball). Upper limb movements characterized by reduction of dexterity of fine finger movements and fatiguing of repetitive movements.

Acknowledgment: The authors thank Prof. Werner Poewe for critical review of the manuscript and his helpful advice.

Walter Pirker, MD
Christoph Baumgartner, MD
Department of Neurology
University of Vienna
Vienna, Austria

Stefan Brugger, MD
Department of Internal Medicine I
University of Vienna
Vienna, Austria

Daniela Prayer, MD
Department of Radiology
University of Vienna
Vienna, Austria

Susanne Kandlhofer, MD
Susanne Asenbaum
Lüder Deecke
Thomas Brücke
Department of Neurology
University of Vienna
Vienna, Austria

Klaus W. Lange, MD
Institute of Psychology
University of Freiburg
Freiburg, Germany

References

1. Patchell RA. Neurological complications of organ transplantation. *Ann Neurol* 1994;36:688–703.
2. Rabitsch W, Brugger SA, Pirker W, et al. Symmetrical necrosis of globus pallidus with severe gait disturbance in a patient with myelodysplastic syndrome given allogeneic marrow transplantation. *Ann Hematol* 1997;75:235–237.
3. Asenbaum S, Brücke T, Pirker W, et al. Imaging of dopamine transporters with [^{123}I]β-CIT and SPECT in Parkinson's disease. *J Nucl Med* 1997;38:1–6.
4. Brücke T, Podreka I, Angelberger P, et al. Dopamine D2 receptor imaging with SPECT: studies in different neuropsychiatric disorders. *J Cereb Blood Flow Metab* 1991;11:220–228.
5. Ellis SJ. Extrapontine myelinolysis after correction of chronic hyponatremia with isotonic saline. *Br J Clin Pract* 1995;49:49–50.
6. Mott SH, Packer RJ, Vezina LG, et al. Encephalopathy with parkinsonian features in children following bone marrow transplantations and high-dose amphotericin B. *Ann Neurol* 1995;37:810–814.
7. Wasserstein PH, Honig LS. Parkinsonism during cyclosporine treatment. *Bone Marrow Transplant* 1996;18:649–650.
8. Jellinger K. Exogenous lesions of the pallidum. In: Vinken PJ, Bruyn GW, Klawans HL, eds. *Handbook of Clinical Neurology*, vol 5. *Extrapyramidal disorders.* Amsterdam: Elsevier Science, 1986:465–491.
9. Percheron G, Filion M, Tremblay L, Fenelon G, Francois C, Yelnik J. The role of the medial pallidum in the pathophysiology of akinesia in primates. *Adv Neurol* 1993;60:84–87.
10. Albin RL, Young AB, Penney JB. The functional anatomy of basal ganglia disorders. *Trends Neurosci* 1989;12:357–381.
11. Alexander GE, Crutcher MD. Functional architecture and basal ganglia circuits: neural substrates of parallel processing. *Trends Neurosci* 1990;13:266–271.
12. DeLong MR. Primate models of movement disorders of basal ganglia origin. *Trends Neurosci* 1990;13:281–285.
13. Marsden CD, Obeso JA. The functions of the basal ganglia and the paradox of stereotaxic surgery in Parkinson's disease. *Brain* 1994; 117:877–897.
14. Bhatia KP, Marsden CD. The behavioral and motor consequences of focal lesions of the basal ganglia in man. *Brain* 1994;117:859–876.
15. Haaxma R, van Boxtel A, Brouwer WH, et al. Motor function in a patient with bilateral lesions of the globus pallidus. *Mov Disord* 1995;10:761–777.
16. Feve AP, Fenelon G, Wallays C, Remy P, Guillard A. Axial motor disturbances after hypoxic lesions of the globus pallidus. *Mov Disord* 1993;8:321–326.
17. Krack P, Pollak P, Limousin P, Benabid AL. Levodopa-inhibiting effect of pallidal surgery [Letter]. *Ann Neurol* 1997;42:P129.
18. Bleasel AF, Morris HHI. Supplementary sensorimotor area seizures. In: Wyllie E, ed. *The Treatment of Epilepsy: Principles and Practice,* 2nd ed. Baltimore, MD: Williams & Wilkins, 1997:432–441.
19. Giladi N, Kao R, Fahn S. Freezing phenomenon in patients with parkinsonian syndromes. *Mov Disord* 1997;12:302–305.
20. Patla AE. Neurobiomechanical bases for the control of human locomotion. In: Bronstein AM, Brandt T, Woollacott M, eds. *Clinical Disorders of Balance, Posture and Gait.* London: Arnold, 1995:19–40.
21. Stuss DT, Benson DF. *The Frontal Lobes.* New York, NY: Raven Press, 1986.
22. Haaxma R, Robbins TW, James M, Brouwer WH, Colebatch JG, Marsden CD. Neurobehavioral changes in a patient with bilateral lesions of the globus pallidus. *Behav Neurol* 1993;6:229–237.

An Unusual Jaw Tremor With Characteristics of Primary Orthostatic Tremor

Jaw tremors can occur in dystonia, essential tremor,[1] idiopathic Parkinson's disease,[2] and shivering,[3] and are associated with palatal myoclonus[4] and hereditary geniospasm.[5,6] However, the tremor frequency in all of these conditions usually does not exceed 12 Hz.

We report a woman with an unusual tremor of the jaw, with a frequency of 16 Hz. This is the first example of a focal jaw

*Deceased as of September 29, 1998.

A videotape accompanies this article.

Received June 18, 1998; revision received November 11, 1998. Accepted January 25, 1999.

Address correspondence and reprint requests to Kailash Bhatia, Department of Clinical Neurology, Institute of Neurology, Queen Square, London WC1 3BG, U.K.

tremor with a frequency comparable to that of primary orthostatic tremor (POT) which characteristically affects the legs.

Case Report

A 24-year-old woman suddenly developed a tremor of the jaw resembling chattering of the teeth in the cold. There had been no precipitating event or injury during the days prior to the onset or any use of medication within the year prior to onset. She had never experienced any similar episodes or the feeling of internal tremor before and was at complete rest at the onset. During the following 6 years she experienced bouts of jaw tremor lasting for seconds to many months. The tremor could be triggered by cold and was once noticed during sleep. There was no pain associated with it and it did not interfere with eating or drinking, but she had some difficulty speaking at times. The jaw tremor could be suppressed by clenching her teeth tightly or opening the mouth wide and was followed by a rebound of tremor. There was no response to alcohol. By history, her grandmother had developed a jaw tremor at age 85, although by description it was slower in frequency and not similar to the index case. The grandmother apparently had no tremor of her hands and no other problems apart from some slowness in walking. Carbamazepine, clonazepam, and acetazolamide had no significant effect on the patient's jaw tremor. For a few months while on 120 mg propranolol per day the tremor remitted but then returned. Primidone at a dose of 200 mg per day abolished the episodes of jaw tremor almost completely, although the patient continued to have an inward subjective feeling of tremor.

She was seen during one of the bouts of jaw tremor and was noted to have a remarkable fast tremor of the jaw (see the videotape) which could be suppressed by talking. The face, palate, eyes, and neck were unaffected. There was a fine postural tremor of both hands but no other extrapyramidal features. There were no Kayser-Fleischer rings, and the rest of the neurologic examination was unremarkable. Tremor recording by surface electromyography (EMG) at this time revealed a tremor frequency of 16 Hz. A magnetic resonance image of the brain was normal, as were full blood count, sedimentation rate, electrolytes, blood sugar, syphilis serology, and copper studies.

Seen again 6 years later, she continued to have bouts of jaw tremor. Surface myography of the right and left masseter muscles, performed at this time but between bouts, revealed a rhythmic tremor frequency of 14 Hz in the absence of a visible jaw tremor and 16 Hz during exacerbations when the tremor was visible (see Fig. 1). It was suppressed by clenching the jaw (Fig. 1A) or by opening the mouth completely (Fig. 1B). Visible tremor could be precipitated by glabellar tap or tapping of the open jaw. Tremor EMG bursts were regular, of brief duration (approximately 25 msec), and highly synchronous. The tremor could be reset by taps to the jaw. The frequency of the postural tremor of the hands was 8 Hz. There was no evidence of a tremor of the lower limbs when sitting or standing both clinically and on EMG recording.

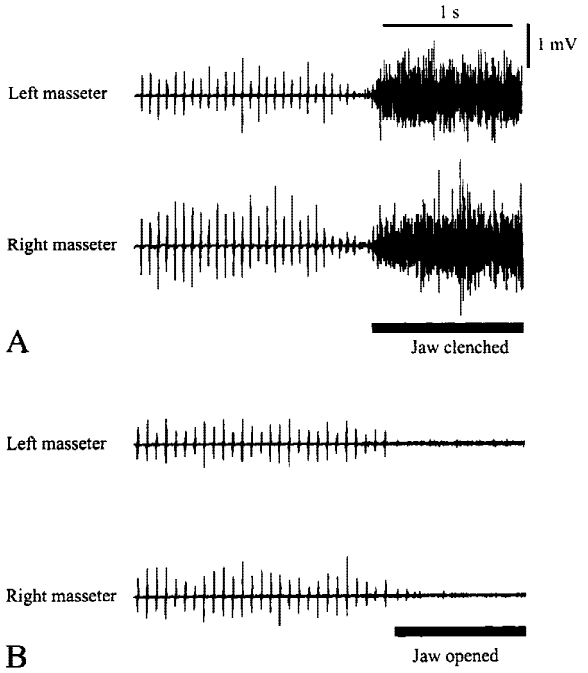

FIG. 1. Surface EMG recorded over left and right masseter during jaw closure (**A**) and opening the mouth wide (**B**). The 16 Hz tremor was suppressed by these maneuvers.

Discussion

A tremor frequency of 16 Hz is typically described only for POT, in which it characteristically occurs in the legs when standing but is suppressed by walking or sitting down.[7–9] The high frequency tremor in POT is absent at rest and usually does not involve the face. It is most pronounced in leg and trunk muscles and highly synchronous between upper and lower limbs.[7] In our patient, the rapid 16 Hz tremor affected the jaw alone, whereas there was an associated tremor of the hands of 8 Hz, and there was no tremor of the legs or the neck muscles. The jaw tremor was evident when the patient had her mouth closed (seated, lying down, and standing), and was suppressed when she opened her mouth wide or when talking. There are a number of similarities between this patient's jaw tremor and POT of the legs. The tremor frequency of 16 Hz is almost pathognomonic for POT and has not been described in any other kind of tremor. POT of the legs characteristically appears when the patient is standing. However, the fact that this patient's jaw tremor appeared when her mouth was gently closed is analogous to standing, because there is residual (antigravity) activity in the masseter muscles in control subjects when the mouth is closed (P. Brown, personal communication, April 1998). It can therefore be considered a postural tremor of the jaw equivalent to the postural tremor of the legs in POT. Additionally, like POT, which is suppressed by action, that is, walking, this patient's jaw tremor was suppressed by talking. It may be surmised that this tremor is rhythmic myoclonus, because it was seen during sleep on one occasion. It is conceivable, however, that residual antigravity activity in the masseter muscles may induce tremor during non-REM sleep. The jaw tremor in this patient was usually absent in sleep and was suppressed rather than aggravated by talking or clenching her mouth unlike action myoclonus. Also on EMG, there was an alternating rhythmic pattern of tremor. We therefore feel that this isolated jaw tremor may be a focal variant of POT.

Legend To The Videotape

This segment shows the patient's rapid up-and-down jaw tremor during one of her bouts. Note the brief cessation of the tremor when she closes her mouth and when she is speaking.

Anette Schrag, MD
Kailash Bhatia, MD
Peter Brown, MD
*C. David Marsden, DSc
Institute of Neurology
Queen Square
London, U.K.

References

1. Bain PG, Findley LJ, Thompson PD, et al. A study of hereditary essential tremor. *Brain* 1994;117:805–824.
2. Giladi N, Meer J, Kidan C, Greenberg E, Gross B, Honigman S. Interventional neurology: botulinum toxin as a potent symptomatic treatment in neurology. *Isr J Med Sci* 1994;30:816–819.
3. Lun V, Sun JC, Giesbrecht GG, Mekjavic IB. Shivering thermogenesis during acute hypercapnia. *Can J Physiol Pharmacol* 1994; 72:238–242.
4. Deuschl G, Mischke G, Schenck E, Schulte-Mönting J, Lücking CH. Symptomatic and essential rhythmic palatal myoclonus. *Brain* 1990;113:1645–1672.
5. Soland VL, Bhatia KP, Sheean GL, Marsden CD. Hereditary geniospasm: two new families. *Mov Disord* 1996;1:744–746.
6. Rosenberg ML, Clark JB. Familial trembling of the chin [Abstract]. *Neurology* 1987;37(suppl 1):190.
7. Britton TC, Thompson PD, van der Kamp W, et al. Primary orthostatic tremor: further observations in six cases. *J Neurol* 1992; 239:209–217.
8. Thompson PD, Rothwell JC, Day BL, et al. The physiology of orthostatic tremor. *Arch Neurol* 1986;43:584–587.
9. Deuschl G, Lucking CH, Quintern J. Orthostatischer tremor: klinik, pathophysiologie und therapie. *Z EEG-EMG* 1987;18:13–19.
10. Bauleo S, De Mitri P, Coccagna G. Evolution of segmental myoclonus during sleep: polygraphic study of two cases. *Ital J Neurol Sci* 1996;17:227–232.

Primary Antiphospholipid Syndrome Presenting as a Corticobasal Degeneration Syndrome

Corticobasal degeneration (CBD) is a distinctive clinical syndrome that results from asymmetric cortical and basal ganglionic destruction.[1] The basal ganglionic pathology causes an akinetic-rigid syndrome with dystonia, whereas asymmetric frontoparietal cortical damage leads to apraxia, cortical sensory loss, alien hand phenomenon, and cortical myoclonus.[2,3] The prominent cortical involvement may lead to confusion with other focal cortical degenerations such as frontotemporal dementia, whereas the supranuclear gaze palsy may lead to difficulty in distinguishing the syndrome from progressive supranuclear palsy (PSP).[4] Although PSP may involve the cortex and frontotemporal dementia may involve the basal ganglia, the combined significant clinical involvement of both cortex and basal ganglia is characteristic of CBD, and it is unusual for other conditions to affect both of these structures so severely. We present a case of antiphospholipid syndrome which clinically presented as a CBD-like syndrome.

Received September 16, 1998; revisions received January 20 and February 22, 1999. Accepted February 23, 1999.

Address correspondence and reprint requests to Andrew J. Lees, MD, National Hospital for Neurology and Neurosurgery, Queen Square, London WC1N 3BG, U.K.

Case Report

A 44-year-old woman was referred for a neurologic opinion with an exacerbation of long-standing migraine. She had early parkinsonism with hypomimic facies, a shuffling gait, and a marked left-sided akinetic-rigid syndrome which made it difficult for her to dress. She was treated with amantadine and L-dopa both of which were ineffective, and there was progressive difficulty in use of the left hand. Five months after the initial presentation, she developed florid livedo reticularis and difficulty reading with horizontal diplopia. The amantadine was stopped when the livedo reticularis first appeared without resolution of the rash. She was admitted for further investigation. There was no history of miscarriage or venous or arterial thrombosis. On examination she had widespread livedo reticularis and a vasculitic rash on both feet. She had a vertical supranuclear gaze palsy, more marked on upward than downward gaze. Vertical smooth pursuit eye movements were intact but horizontal smooth pursuit eye movements were jerky. There was no visual or sensory neglect. There was left-sided upper motor neuron facial weakness and asymmetric upper limb rigidity and bradykinesia which affected the left arm more severely than the right. Mild pyramidal weakness and marked apraxia for miming the use of objects and copying finger movements was present in the left hand and arm which was not present on the right. There was loss of graphesthesia in the left hand and loss of joint position sense to the left elbow. There was no alien limb phenomenon or myoclonus. Reflexes were pathologically brisk with flexor plantars, the gait was slow and stiff with absent arm swing, but the postural reflexes were relatively well preserved. The initial clinical diagnosis was progressive supranuclear palsy or corticobasal degeneration with features suggestive of systemic vasculitis. The difficulty with use of the left hand was thought to be the result of dysfunction of both praxis and extrapyramidal function. Investigations showed that there was proteinuria with a creatinine clearance of 52 mL/min, elevated activated partial thromboplastin time with a circulating lupus anticoagulant, elevated anticardiolipin antibodies with IgG titer 62.2 (positive >5) and IgM titer 11.1 (positive >5). The platelet levels were normal. Antinuclear antibodies were present at a titer of 1:80 but there were no anti-DNA or ENA antibodies. Complement levels were normal and the ANCA test was normal. Magnetic resonance imaging (MRI) of the brain revealed multiple infarcts in the cerebral hemispheres and basal ganglia with prominent lesions in the right parietal lobe and head of the left caudate nucleus (Fig. 1). Doppler ultrasound of the carotid vessels showed no significant stenosis. Magnetic resonance angiography showed no large vessel stenosis and echocardiography was normal. A skin biopsy was not contributory. A diagnosis of primary antiphospholipid syndrome with cortical and subcortical infarction was made, and warfarin and aspirin treatment was started.

Over the subsequent 3 years of follow up, there was a moderate improvement in her left-sided apraxia but she remained

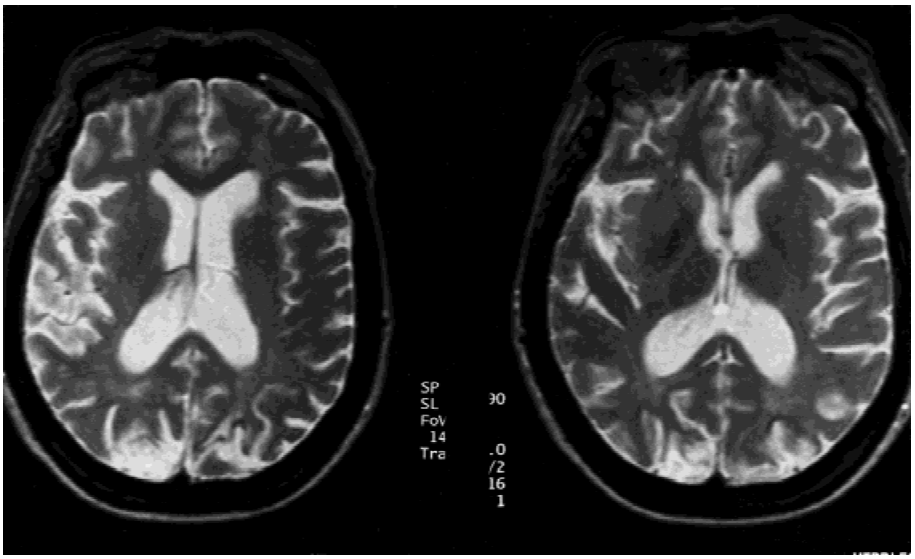

FIG. 1. Axial T2-weighted MRI scan showing infarcts in the left parietal and occipital lobes and in the head of the right caudate nucleus.

bradykinetic. A repeat MRI scan of the brain 2.5 years later showed the cerebral vascular disease was virtually unchanged with one small additional infarct in the right opercular region.

Discussion

Relatively few conditions can mimic corticobasal degeneration but these include Creutzfeldt-Jakob disease, Pick's disease, progressive multifocal leukoencephalopathy, PSP, hemiatrophy–hemiparkinsonism syndrome, cerebrovascular disease, and adult-onset sudanophilic leukodystrophy[5–7] (K. Bhatia, personal communication, 1998). Although PSP may be misdiagnosed as CBD,[8] and dystonia[9] and apraxia[10,11] may be features of PSP, it is unusual to have marked clinical cortical sensory loss in this condition. Antiphospholipid syndrome predisposes to both large and small vessel occlusion[12] and has a predilection to affect the basal ganglia, and as such would seem likely to produce the combination of cortical and basal ganglia damage which characterize CBD.

Antiphospholipid antibodies have been known to be a part of systemic lupus erythematosis (SLE) for many years, and a separate primary antiphospholipid syndrome (PAPS) without the features of SLE is also recognized. PAPS is associated with both venous and arterial thrombosis, thrombocytopenia, migraine, livedo reticularis, and recurrent miscarriages. PAPS is one of the more common causes of secondary stroke in the young. Our case is consistent with PAPS with the absence of clinical features of SLE and anti-double-stranded DNA antibodies, and the presence of high-titer antiphospholipid antibodies with cerebrovascular disease, migraine, and livedo reticularis. In addition, CBD was made less likely by the age of onset of our patient; in a recent clinicopathologic series, patients with CBD had an average age of onset of 63 with a range of 45–75.[13] Aside from stroke, PAPS can cause movement disorders with chorea, alternating hemichorea, hemiballismus, and dystonia all having been reported as complications.[14–16] In some of these cases, a vascular etiology appears to be responsible, for example, with acute-onset hemiballismus, but in other cases it has been suggested that there may be an autoimmune response to the basal ganglia analogous to Sydenham's chorea. Our case has MRI evidence of infarction of both the cortex and the caudate nucleus but given the bilateral nature of our patient's signs, there must either have been further vascular damage not seen with MRI imaging or an additional autoimmune component. Postmortem assessment of the PAPS-related movement disorders and the development of antibasal ganglia antibody tests will help to resolve this issue.

In summary, we have presented a case of antiphospholipid syndrome masquerading as corticobasal degeneration, and we propose that antiphospholipid syndrome is considered as a cause of symptomatic movement disorders particularly when seen with livedo reticularis, migraine, or unexplained infarcts on neuroimaging.

Huw R. Morris, MRCP
Andrew J. Lees, MD
National Hospital for Neurology and Neurosurgery
Queen Square
London, U.K.

References

1. Gibb WR, Luthert PJ, Marsden CD. Corticobasal degeneration. *Brain* 1989;112:1171–1192.
2. Thompson PD, Day BL, Rothwell JC, Brown P, Britton TC, Marsden CD. The myoclonus in corticobasal degeneration. Evidence for two forms of cortical reflex myoclonus. *Brain* 1994;117: 1197–1207.
3. Gibb WR, Luthert PJ, Marsden CD. Clinical and pathological features of corticobasal degeneration. *Adv Neurol* 1990;53:51–54.
4. Litvan I, Agid Y, Goetz C, et al. Accuracy of the clinical diagnosis of corticobasal degeneration: a clinicopathologic study. *Neurology* 1997;48:119–125.
5. Cannard K, Galvez-Jimenez N, Watts R. Creutzfeldt-Jakob disease presenting and evolving as rapidly progressive corticobasal degeneration [Abstract]. *Neurology* 1998;50:A95.
6. Lang AE, Bergeron C, Pollanen MS, Ashby P. Parietal Pick's disease mimicking cortical-basal ganglionic degeneration. *Neurology* 1994;44:1436–1440.
7. Giladi N, Fahn S. Hemiparkinsonism–hemiatrophy syndrome may mimic early-stage cortical-basal ganglionic degeneration. *Mov Disord* 1992;7:384–385.

8. Litvan I, Campbell G, Mangone CA, et al. Which clinical features differentiate progressive supranuclear palsy (Steele-Richardson-Olszewski syndrome) from related disorders? A clinicopathological study. *Brain* 1997;120:65–74.
9. Barclay CL, Lang AE. Dystonia in progressive supranuclear palsy. *J Neurol Neurosurg Psychiatry* 1997;62:352–356.
10. Bergeron C, Pollanen MS, Weyer L, Lang AE. Cortical degeneration in progressive supranuclear palsy. A comparison with cortical-basal ganglionic degeneration. *J Neuropathol Exp Neurol* 1997; 56:726–734.
11. Leiguarda RC, Pramstaller PP, Merello M, Starkstein S, Lees AJ, Marsden CD. Apraxia in Parkinson's disease, progressive supranuclear palsy, multiple system atrophy and neuroleptic-induced parkinsonism. *Brain* 1997;120:75–90.
12. Levine SR, Deegan MJ, Futrell N, Welch KM. Cerebrovascular and neurologic disease associated with antiphospholipid antibodies: 48 cases. *Neurology* 1990;40:1181–1189.
13. Wenning GK, Litvan I, Jankovic J, et al. Natural history and survival of 14 patients with corticobasal degeneration confirmed at postmortem examination. *J Neurol Neurosurg Psychiatry* 1998;64: 184–189.
14. Angelini L, Rumi V, Nardocci N, Combi ML, Bruzzone MG, Pellegrini G. Hemidystonia symptomatic of primary antiphospholipid syndrome in childhood. *Mov Disord* 1993;8:383–386.
15. Cordova JL, Neira O, Abumohor P, Palma S, Vergara F, Guzman L. Anticardiolipin antibodies and primary antiphospholipid syndrome of the central nervous system: report of 10 clinical cases. *Rev Med Chil* 1991;119:765–771.
16. Sugiyama Y, Yamamoto T, Tsukamoto T, Saito T, Takahashi T. A case of chorea as a sole presentation of primary anti-phospholipid antibody syndrome. *Rinsho Shinkeigaku* 1991;31:1224–1228.

Successful Treatment of Hemichorea With Olanzapine

Hemiballismus/hemichorea is most often associated with lesions of the subthalamic nucleus or its afferent or efferent pathways. Although there are a wide range of etiologies for hemiballismus/hemichorea, the most common cause is infarction.[1] Hemichorea secondary to infarction may occur independent of hemiballismus. It is not uncommon for hemichorea to occur simultaneously in the distal aspect of the affected limb, and it is well known that resolving hemiballismus often becomes hemichorea before the distal movements stop. We present a hypertensive patient, noncompliant with medication, who had a sudden onset of hemichorea which was successfully treated with the atypical neuroleptic olanzapine.

Case Report

A 71-year-old woman presented to the emergency room of Jackson Memorial Hospital with involuntary, continuous jerking of her left arm and leg. The movements began 3 days earlier when she awoke in the morning. Initially only her left leg was moving from side to side on the bed but later the same day the movements spread to the left arm. She described the movements to be slow, irregular, and clumsy. The movements worsened at rest and stopped during sleep. The constant motion interfered with activities of daily living. No sensory changes were reported.

There was no history of an intermittent movement disorder, no family history of abnormal movements, and no history of exposure to neuroleptic medication. She had a history of hypertension for many years and was noncompliant with antihypertensive medication. On examination her blood pressure was 190/140 mm Hg. She had choreodystonic movements of both the left arm and leg. The movements were more prominent distally. She had a slightly wide-based gait, slowing of alternating finger movements and foot tapping on the left, but there was no focal paresis.

Laboratory evaluation, including complete blood count, electrolytes, liver and renal function, coagulation studies, ANA, lupus anticoagulant, ACE levels, thyroid function studies, and urine toxicology screen, were all normal. Computed tomography scan of the brain revealed bilateral basal ganglia calcification. No lacunes or lesions were seen in the region of the subthalamic nucleus. Magnetic resonance imaging of the brain showed periventricular white matter changes. Diagnostic investigation, including echocardiogram and electroencephalogram, were normal. Carotid doppler examination demonstrated mild intimal thickening in both common carotid arteries. Transesophageal echocardiogram showed no evidence of thromboembolism.

She was initially treated with antihypertensive medication and aspirin. Olanzapine at a dosage of 2.5 mg at bedtime was started to treat her hemichorea. The following morning significant clinical improvement occurred. Increasing olanzapine to 5 mg at bedtime resulted in complete resolution of the hemichorea. The patient did not return to the neurology outpatient department. Multiple attempts to contact her were unsuccessful and she was lost to follow up.

Discussion

Although the early descriptions of hemiballismus/hemichorea emphasized a grim prognosis with the majority of patients dying within weeks to months of the onset of these abnormal movements,[2,3] the introduction of neuroleptics has radically altered the prognosis for hemiballismus/hemichorea secondary to vascular lesions.[4] It has become standard treatment to use neuroleptics that block dopamine D_2 receptor sites to achieve adequate suppression of the movements. Dopamine-depleting agents such as reserpine are also effective in treating this disorder.

Although no lacune was shown in our patient, Dewey and Jankovic[5] reported that no lesion is identifiable in almost 40% of cases. Our patient's long history of poorly treated hypertension and the sudden onset of the abnormal movements strongly suggests a vascular etiology.

Olanzapine, which was successfully used to treat hemichorea in this patient, is one of several new atypical neuroleptics that has a pharmacologic profile similar, but not identical, to clozapine. Clozapine has been reported to control hemiballismus.[6] An atypical neuroleptic is characterized by a reduced capacity to induce acute extrapyramidal symptoms (EPS) or tardive dyskinesia as well as increased efficacy, particularly for the negative symptoms of schizophrenia.[7] The diminished D_2 affinity of

Received November 5, 1998; revision received February 15, 1999. Accepted February 16, 1999.

Address correspondence and reprint requests to William J. Weiner, MD, Department of Neurology, University of Miami School of Medicine, 1501 NW 9th Avenue, Miami, FL 33136, U.S.A.

olanzapine raises the question of whether olanzapine will be an effective therapy for choreiform disorders. Conversely, the relatively mild EPS profile may make olanzapine an especially useful antipsychotic for the drug-induced hallucinations in Parkinson's disease.[8] Recent reports suggest that olanzapine may exacerbate parkinsonism in patients with Parkinson's disease and suppress chorea in tardive dyskinesia indicating the presence of clinically relevant dopamine D_2 receptor antagonistic properties.[9–11]

Our experience successfully treating hemichorea with olanzapine also suggests that olanzapine produces a clinically significant blockade of the dopaminergic motor pathways of the basal ganglia. The use of antipsychotic medications, typical or atypical, to treat hemichorea should be kept at the lowest effective dose for the shortest period of time possible. Further study will be necessary to determine whether olanzapine is as effective as traditional neuroleptics for the various choreiform disorders or if olanzapine is preferable to traditional neuroleptics for the treatment of choreic disorders resulting from its reduced risk of tardive dyskinesia.

Beth Safirstein, MD
Lisa M. Shulman, MD
William J. Weiner, MD
Department of Neurology
University of Miami
School of Medicine
Miami, Florida, U.S.A.

References

1. Weiner WJ, Lang AE. Other choreas and miscellaneous dyskinesias. In: *Movement Disorders: A Comprehensive Survey*. Mt. Kisco, NY: Futura Publishing Co, 1989:569–573.
2. Meyers R. Ballismus. In: Vinken PJ, Bruun GW, eds. *Handbook of Clinical Neurology*, vol 6. Amsterdam: Elsevier, 1968:476–490.
3. Moersch FP, Hernohan JW. Hemiballismus: a clinicopathologic study. *Arch Neurol Psychiatry* 1939;41:365–372.
4. Klawans HL, Moses HD, Nausieda PA, Weiner WJ. Treatment and prognosis of hemiballismus. *N Engl J Med* 1976;295:1348–1350.
5. Dewey RB, Jankovic J. Hemiballismus–hemichorea: clinical and pharmacologic findings in 21 patients. *Arch Neurol* 1989;46:862–867.
6. Bashir K, Manyam BV. Clozapine for the control of hemiballismus. *Clin Neuropharmacol* 1994;17:477–480.
7. Tamminga LA, Lahti AC. The new generation of antipsychotic drugs. *Int Clin Psychopharmacol* 1996;11:73–76.
8. Wolters EC, Jansen ENH, Tuynman-Qua HG, Bergmans PLM. Olanzapine in the treatment of dopaminominetic psychosis in patients with Parkinson's disease. *Neurology* 1996;47:1085–1087.
9. Friedman J. Olanzapine in the treatment of dopaminomimetic psychosis in patients with Parkinson's disease. *Neurology* 1988;50:1195–1196.
10. Jimenez-Jimenez FJ, Tallon-Barranco A, Orti-Pareja M, Zurdo M, Porta J, Molina JA. Olanzapine can worsen parkinsonism. *Neurology* 1998;50:1183–1184.
11. Stacy M, Kurth M, Woolhiser K. Olanzapine in the treatment of tardive dyskinesia. *Mov Disord* 1997;12:846.