

LETTERS AND
CORRESPONDENCE

Letters and correspondence submitted for possible publication must be identified as such. Text length must not exceed 500 words and five bibliographic references. A single concise figure or table may be included if it is essential to support the communication. Letters not typed double-spaced will not be considered for publication. Letters not meeting these specifications will not be returned to authors. Letters to the Editor are utilized to communicate a single novel observation or finding. Correspondence is to be used to supplement or constructively comment on the contents of a publication in the journal and cannot exceed the restrictions for Letters to the Editor. The Editor reserves the right to shorten text, delete objectional comments, and make other changes to comply with the style of the journal. Permission for publication must be appended as a postscript. Submissions must be sent to Paul Chervenick, M.D., Editor of Brief Reports/Letters to Editors, American Journal of Hematology, H. Lee Moffitt Cancer Center, University of South Florida, 12902 Magnolia Drive, Tampa, FL 33612 to permit rapid consideration for publication.

A Case of Primary Refractory Hodgkin's Disease Treated Successfully With Paclitaxel

To the Editor: The management of patients with Hodgkin's Disease (HD) has been one of the major successes of clinical oncology in this century. Three of every four patients can be expected to be cured of this previously uniformly fatal disease [1,2]. Most patients with advanced disease achieve durable remissions and long-term survival when treated with combination chemotherapy. Patients who fail to attain a complete remission after treatment with one of the standard chemotherapy regimens have the poorest prognosis. Although they sometimes respond to a non-cross-resistant program, these remissions usually are brief. New drugs are needed to be tested in refractory patients to one or more salvage regimens and for those who are not candidate for high-dose chemotherapy with bone marrow or peripheral stem transplantation. We report a case of a patient with primary refractory HD who failed one standard and two salvage chemotherapy regimens and achieved a complete remission following treatment with paclitaxel (Taxol). A 34-year-old white man presented in March 1994 with dyspnea, bloody sputum, night sweats, and weight loss. He was found to have a 10 × 7-cm mediastinal mass on computed tomography (CT) of the chest. Mediastinoscopy and video assisted thoracoscopy revealed a large tumor, which on pathologic study was consistent with nodular sclerosing HD. Following appropriate staging, he was found to have bulky stage IIB disease with mediastinal and cervical lymphadenopathy. He received the standard MOPP/ABV hybrid regimen and achieved a partial response radiographically; however, by completion of the sixth cycle his mediastinal mass demonstrated some regrowth and he was referred for radiation therapy. He received a total of 4,050 Cgy to the mediastinum and completed treatment in December 1994. His mediastinal mass failed to demonstrate any reduction in size. A gallium scan showed focal uptake within the mediastinal mass consisting with residual disease. In February 1995 he was referred to a bone marrow transplant center. It was felt that he was not a candidate for high-dose chemotherapy because of obstructive and restrictive lung disease. He then received two courses of etoposide, cisplatin, cytarabine, and methylprednisolone along with G-CSF because of postchemotherapy neutropenia. His tumor failed to respond in size and he refused

any further treatment at that time. Serial chest X-rays demonstrated disease stability until late June 1996 when his mediastinal mass showed significant regrowth with the appearance of new left lung nodules. He then received two cycles of prednisone, etoposide, chlorambucil, and CCNU with 25% reduction in the mediastinal mass and 50% reduction in the lung nodules. Two additional cycles failed to produce any further response and treatment was discontinued. Within a few months later, his B symptoms recurred and by December 1997 he was found to have bilateral multiple pulmonary nodules of 1 to 2 cm each. An open lung biopsy demonstrated recurrent HD. One month later his pulmonary nodules progressed. He then received single agent paclitaxel at 175 mg/m² intravenously every three weeks. He achieved a partial response after four cycles and a complete response after six. His symptoms completely resolved and he is currently receiving two additional cycles of paclitaxel.

Review of the literature showed that the activity of paclitaxel in patients with primary refractory HD has been reported in two studies with mixed results [3,4]. One of the studies combined paclitaxel with etoposide and included patients with refractory and relapsed HD and non-Hodgkin's lymphoma. Nine responses (four complete and five partial) were seen in 28 treated patients [4]. Evaluating new agents for refractory HD presents a challenging problem because treatment of newly diagnosed patients has been so successful and because some patients can be cured with second line therapy and high-dose chemotherapy. The occasional patient who fails to respond to standard treatment regimens and does not qualify for bone marrow transplantation presents a challenge to the treating physician. Based on the experience of others and ourselves, we recommend exploring further the use of paclitaxel in such patients.

ANDRE M. KALLAB

Assistant Professor of Medicine, Division of Hematology/Oncology at the Medical College of Georgia, Augusta, Georgia

PAUL DAINER

Associate Professor of Medicine, Division of Hematology/Oncology at the Medical College of Georgia, Augusta, Georgia

REFERENCES

1. Rosenberg SA. The treatment of Hodgkin's disease. *Ann Oncol* 1994;5:17–21.
2. Bonadonna G. Modern treatment of malignant lymphomas: a multidisciplinary approach? *Ann Oncol* 1994;5(Suppl 2):5–16.
3. Younes A, Cabanillas F, McLaughlin PW, Hagemeister FB, Farber C, Sarris A, Pate O, Myers J, Portlock C. Preliminary experience with paclitaxel for the treatment of relapsed and refractory Hodgkin's disease. *Ann Oncol* 1996;7(10):1083–1085.
4. Kancherla R, Mannancheril A, Lake DE, Seiter K, Durrani H, Lipschutz M, Navone J, Feldman EJ, Ahmed T. Phase II study of taxol and etoposide in relapsed/refractory lymphoma. *Proc Am Soc Clin Oncol* 1997;16:33. Abstract nr 116.

Recurrent Lymphocytic Pleural Effusion After Intravenous Immunoglobulin

To the Editor: A 35-year-old female was initially diagnosed in 1981 with stage IIA Hodgkin's disease treated successfully with MOPP (mechlorethamine, oncovin, procarbazine, and prednisone) and mantle radiation.

Idiopathic thrombocytopenic purpura (ITP) was diagnosed four years later and was treated successfully with prednisone. Her ITP recurred in 1992 and splenectomy was performed. The surgical pathology did not reveal any evidence of lymphoma. Unfortunately, her ITP recurred shortly thereafter and various treatments including intravenous immunoglobulin (IVIG), danazol, vitamin C, cyclophosphamide, and vincristine were tried with only brief response. She was referred to this institution in April 1996 and since then she received IVIG (Venoglobulin® S 10%, Alpha Therapeutic Corporation, Los Angeles, CA) 1 gm/kg/day for two days every 4–6 weeks [1]. On January 23, 1997 she was admitted as usual for IVIG. On the second day, she developed chest pain and dyspnea. Chest radiograph revealed bilateral pleural effusion. Pleural tapping revealed WBC 2,977/ μ L, 97% mature lymphocytes, glucose 92 mg/dL, protein 3.3 gm/dL, and LDH 274 IU/L. Cytology was negative. Serum antinuclear antibody (ANA) was negative; C3 and C4 levels were normal. The bacterial and acid-fast bacillus cultures of the pleural fluid were sterile. The symptoms gradually resolved after an empiric course of cefuroxime. The pleural fluid resolved completely two weeks later. In February 1997, she was placed on intravenous anti-D immunoglobulin with no response. On March 17, 1997, she was readmitted for another IVIG (Venoglobulin® S). Again bilateral pleural effusion developed on the second day with pleural fluid showing similar findings and no malignant cells. Pleural effusion resolved spontaneously after thoracentesis without antibiotic. On April 24, 1997, she was again admitted with thrombocytopenia and a different preparation of IVIG (Sandoz, East Hanover, NJ) was administered with no recurrence of pleural effusion.

This is the first case to our knowledge of recurrent lymphocytic pleural effusion after IVIG infusion and this complication is not mentioned in the recent review [2,3]. The time course between IVIG infusion and the onset of pleural effusion, as well as the absence of other disorders, make the immunoglobulin the most likely causative agent.

JAVIER BOLANOS-MEADE
YI-KONG KEUNG
EVERARDO COBOS

Department of Internal Medicine, Division of Oncology/Hematology,
Texas Tech University Health Sciences Center and Southwest Cancer
Center, Lubbock, Texas

REFERENCES

1. The American Society of Hematology ITP Practice Guideline Panel. Diagnosis and treatment of idiopathic thrombocytopenic purpura: recommendations of the American Society of Hematology. *Ann Intern Med* 1997;126:319–326.
2. Berkman SA, Lee ML, Gale RP. Clinical uses of intravenous immunoglobulin. *Ann Intern Med* 1990;112:278–292.
3. Stangel M, Hartung HP, Marx P, Gold R. Side effects of high-dose intravenous immunoglobulins. *Clin Neuropharmacol* 1997;20(5):385–393.

lignancies [2,3]. Since a recently identified *Smad5* is involved in the intracellular signal pathways that mediate the inhibitory effects of TGF- β on hematopoiesis [4], *Smad5* rather than *Smad2* and *Smad3* may be a real target in hematological malignancies. To test this hypothesis, we analyzed for mutations of the *Smad5* gene in 35 hematological malignancies by polymerase chain reaction-single strand conformation polymorphism (PCR-SSCP) analysis. Most of the samples were previously analyzed for mutations of the *Smad2* and the *Smad3* genes; no mutations of the *Smad2* and the *Smad3* genes were found in these samples. Genomic DNA extraction and PCR-SSCP was performed as described previously [5]. No mutations of the *Smad5* gene were found within the coding region. Together with our previous findings that the *Smad2*, *Smad3*, and *Smad4* genes are not altered [2,3,6], alterations of the *Smads* genes are infrequent in hematological malignancies. Further studies are necessary to clarify the mechanism of TGF- β resistance in hematological malignancies.

ACKNOWLEDGMENTS

This study was supported in part by a Grant-in-Aid from the Ministry of Education, Science, Sports, and Culture of Japan.

TAKAYUKI IKEZOE
SEISHO TAKEUCHI
MAKOTO KOBAYASHI
HIROKUNI TAGUCHI

Department of Internal Medicine, Kochi Medical School, Kochi, Japan

REFERENCES

1. Riggins GJ, Kinzler KW, Vogelstein B, Thiagalingam S. Frequency of *Smad* gene mutation in human cancers. *Cancer Res* 1997;57:2578–2580.
2. Ikezoe T, Takeuchi S, Kamioka M, Daibata M, Kubonishi I, Taguchi H, Miyoshi I. Analysis of the *Smad2* gene in hematological malignancies. *Leukemia* 1998;12:94–95.
3. Ikezoe T, Takeuchi S, Arai T, Yuasa Y, Taguchi H. Analysis of the *Smad3* gene in hematological malignancies. *Int J Hematol* (in press).
4. Bruno E, Horrigan SK, Van Den Berg D, Rozler E, Fitting PR, Moss ST, Westbrook C, Hoffman R. The *Smad5* gene is involved in the intracellular signaling pathways that mediate the inhibitory effects of transforming growth factor- β on human hematopoiesis. *Blood* 1998;91:1917–1923.
5. Gemma A, Hagiwara K, Vincent F, Ke Y, Hancock AR, Nagashima M, Bennett WP, Harris CC. *hSmad5* gene, a human *hSmad* family member: its full length cDNA, genomic structure, promoter region and mutation analysis in human tumors. *Oncogene* 1998;16:951–956.
6. Verbeek W, Spirin K, Hatta Y, Miller C, Kawamata N, Takeuchi S, Koike M, Asou H, Simpson JK, Koeffler HP. *DPC4/Smad4* in non-pancreatic tumors with frequent LOH 18q21 and in hematological malignancies. *Int J Oncol* 1997;10:257–260.

Analysis of the *Smad5* Gene in Hematological Malignancies*

To the Editor: The *Smads* are involved in the transforming growth factors (TGF)- β intracellular signal pathway, and are recognized as important tumor suppressors. Indeed, both the *Smad4* and the *Smad2* genes are mutated in some of human malignancies [1]. We previously reported that both the *Smad2* and the *Smad3* genes were not mutated in hematological ma-

Vancomycin-Associated Thrombocytopenia: Case Report and Review of the Literature*

To the Editor: Vancomycin, a glycopeptide antibiotic isolated from *Streptomyces orientalis* in 1956, has been widely used since 1958 for treating various infections from gram-positive organisms including methicillin-resistant staphylococci and penicillin-resistant streptococci [1]. Major tox-

*Contract grant sponsor: Ministry of Education, Science, Sports, and Culture (Japan).

*Department of Defense Disclaimer: The views expressed in this article are those of the authors and do not reflect the official policy or position of the Department of the Navy, Department of Defense, or the U.S. government.

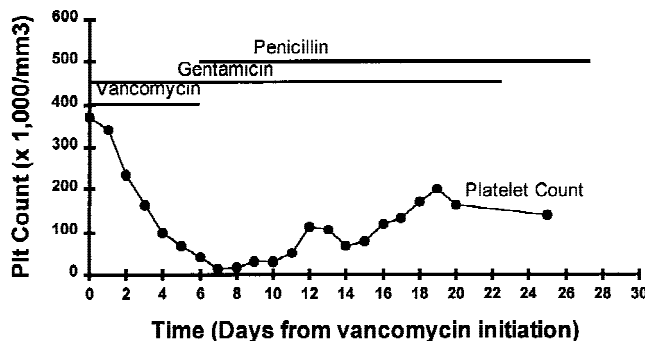


Fig. 1. Platelet count over hospital course.

icities from vancomycin therapy include "red man" syndrome, a nonimmunologically mediated histamine release reaction associated with rapid infusion [2], ototoxicity [3], nephrotoxicity [3], and reversible neutropenia [4]. Vancomycin-associated thrombocytopenia is rare [5–7]. We report a case of severe thrombocytopenia temporally related to the use of vancomycin and reviewed the literature on vancomycin-associated thrombocytopenia.

A 72-year-old woman with a long-standing heart murmur presented with a two-month history of fever and constitutional symptoms. Physical examination revealed a holosystolic murmur at the sternal borders with radiation to the carotid arteries. Laboratory studies revealed leukocytosis with left shift and a platelet count of 407,000/mm³. Transesophageal echocardiography demonstrated a 0.8 cm × 0.3 cm mobile vegetation on the anterior leaflet of the mitral valve. Four sets of blood cultures grew *Corynebacterium pseudodiphtheriticum*, subsequently shown to be penicillin susceptible. The patient was admitted and begun on vancomycin and gentamicin empirically for endocarditis.

On day 4 of vancomycin treatment, the patient's platelet count dropped to 97,000/mm³, reaching a nadir of 14,000/mm³ by day 7 (Fig. 1). Penicillin was substituted for vancomycin on day 6. Two days after discontinuation of vancomycin, the platelet count began to rise, reaching 150,000/mm³ within five days. Vancomycin-dependent antiplatelet immunoglobulin (Ig)G antibody was not detectable 10 days after vancomycin initiation.

Neutropenia is the most common cytopenia associated with vancomycin use, occurring with a frequency of 2–3% [4]. Although immunological neutrophil destruction is postulated, no evidence for vancomycin-dependent antineutrophil antibodies has ever been provided. Vancomycin-associated thrombocytopenia is much rarer, having been previously reported in nonleukemic patients only twice in the English literature [5,6]. In all cases, there was a temporal association between vancomycin initiation and platelet count decline. Platelet counts decreased to below 20,000/mm³ from two to six days after initiation of vancomycin and started recovering within four days of discontinuation. One patient had spontaneous local hemorrhage at the platelet nadir [5], one had recurrent thrombocytopenia upon rechallenge 30 days later [6], and one had an increase in platelet-associated IgG [5].

In a recent report of two leukemic patients, concurrent use of vancomycin was associated with thrombocytopenia and failure to respond to platelet transfusion [7]. One patient developed thrombocytopenia 10 days after initiation of vancomycin (the other was already pancytopenic before starting vancomycin) and both were refractory to platelet transfusion. The presence of vancomycin-dependent antiplatelet IgG antibodies in both patients and restoration of responsiveness to platelet transfusion in one after high-dose intravenous IgG suggested drug-induced immunologic destruction of platelets.

In summary, we present a patient with thrombocytopenia temporally related to vancomycin use. This is a rare but potentially fatal event. The presence of vancomycin-dependent antiplatelet IgG antibodies and response to intravenous IgG suggest a drug-induced immunologic destruction of platelets as the underlying mechanism for the thrombocytopenia and

the subsequent refractoriness to platelet transfusion in certain leukemic patients.

JANAKI C. KURUPPU

Department of Medicine, University of Maryland Medical Center,
Baltimore, Maryland

THONG P. LE

Division of Infectious Diseases, National Naval Medical Center,
Bethesda, Maryland

CARMELITA U. TUAZON

Department of Medicine, the George Washington University Medical
Center, Washington, DC

REFERENCES

1. Lundstrom TS, Sobel JD. Vancomycin, trimethoprim-sulfamethoxazole, and rifampin. *Infect Dis Clin North Am* 1995;9(3):747–751.
2. Polk RE, Healy DP, Schwartz LP, Rock DT, Garson ML, Roller K. Vancomycin and the red-man syndrome: pharmacodynamics of histamine release. *J Infect Dis* 1988;157:502–507.
3. Sorrell TC, Collignon PJ. A prospective study of adverse reactions associated with vancomycin therapy. *J Antimicrob Chemother* 1985;16:235–240.
4. Mordenti J, Ries C, Brooks GF, Unadkat N, Tseng A. Vancomycin-induced neutropenia complicating bone marrow recovery in a patient with leukemia. Case report and a review of the literature. *Am J Med* 1986;80:333–335.
5. Walker RW, Heaton A. Thrombocytopenia due to vancomycin. *Lancet* 1985;1:932.
6. Zenon GJ, Cadle RM, Hamill RJ. Vancomycin-induced thrombocytopenia. *Arch Intern Med* 1991;151:995–996.
7. Christie DJ, Van Buren N, Lennon SS, Putnam JL. Vancomycin-dependent antibodies associated with thrombocytopenia and refractoriness to platelet transfusion in patients with leukemia. *Blood* 1990;75(2):518–523.

Hemoglobin SC and Multiple Myeloma

To the Editor: Hematological malignancies in adults with SS and SC disease were thought to be extremely rare until twenty years ago. One explanation for the paucity of malignancy was that these patients succumbed to complications of their disease before they had a chance to develop neoplastic disorders. We now know that patients with hemoglobin SC (and sometimes SS) have a benign clinical course [1]. We are reporting the case of a 62-year-old female, native of Jamaica (West Indies) with hemoglobin SC disease. She has never had a sickling crisis or visual problems. She has had chronic leg ulcers and an uneventful pregnancy. She has a 64-year-old sister (who is being followed at our clinic) with asymptomatic SC disease, and a sister who died at age 18 during what appears to have been a sickling crisis.

On a routine visit she was found to have a hemoglobin of 6.5 g/dl (a decrease from her usual 8 g/dl). Her white blood cells, platelets, and renal function were normal. Her reticulocyte count remained unchanged. There was no evidence of gastrointestinal bleeding or deficiencies in B12 folate or iron. There was no evidence of infection. A bone marrow aspirate showed many large plasma cells. Serum immunoelectrophoresis revealed an IGA K of 2,702 mg/dl. In less than six months it rose to 4,750 mg/dl. Therapy was initiated with an alkylating agent. Her hemoglobin increased to its baseline.

Sixteen cases of hematological malignancies have been described in adults with SS and SC disease over the past 20 years. They include multiple myeloma (six cases), acute myeloblastic leukemia, malignant histiocytosis, and Hodgkin's disease [2–5]. Stricker et al. [2] suggest a possible increase in such malignancies. They have shown alterations in chromosome 5 in two

sickle cell patients with leukemia, raising the possibility of a chromosomal link between the two diseases. Myeloma is more common in blacks and is found in patients with sickle cell at an earlier age [4]. We therefore suggest a comprehensive evaluation including bone marrow studies in patients with SS or SC disease in whom a fall in hemoglobin cannot be attributed to increased hemolysis or concurrent infection.

ARYEL NICOLEAU
BARRY KAPLAN
JEAN D. BALZORA

Newark Hospital Medical Center of Queens, Flushing, New York

REFERENCES

1. Serjeant GR, Ashcroft MT, Serjeant BE. The clinical features of haemoglobin SC disease in Jamaica. *Br J Haematol* 1973;24(4):491-501.
2. Stricker RB, Linker CA, Crowley TJ, Embury SH. Hematologic malignancy in sickle cell disease: report of four cases and review of literature. *Am J Hematol* 1986;21(2):223-230.
3. Sarma PS, Viswanathan KA, Mukherjee MM. Multiple myeloma in a patient with sickle cell anaemia. *J Assoc Physicians India* 1986;34(12):877-878.
4. Talerman A, Serjeant GR, Milner PF. Normal pregnancy in a patient with multiple myeloma and sickle cell anaemia. *West Indian Med J* 1971;20(2):97-100.
5. Anderson IS, Yeung KY, Hillman D, Lessin LS. Multiple myeloma in a patient with sickle cell anemia. Interacting effects on blood viscosity. *Am J Med* 1975;59(4):568-574.

Desmoid Tumors Supervening in Two Patients With Chronic Lymphocytic Leukemia

To the Editor: Desmoid tumor, also known as desmoid fibromatosis or deep fibromatosis, is a subtype of fibromatosis arising from deep facial or

soft tissue structures [1]. It is characterized by a locally aggressive behavior with a tendency for local recurrence but without distant metastases. Abdominal and extra-abdominal subtypes have been described. Recently, chromosomes abnormalities involving 5q21, trisomy 8, and chromosome Y, have been evidenced in desmoid tumors [1,2].

Chronic lymphocytic leukemia (CLL) has been associated frequently with second malignancies such as Richter's lymphoma, myelodysplasia, acute lymphoblastic leukemia, polycythemia, renal cell carcinoma, and various types of epithelioma [3]. However, the association of CLL and desmoid tumor has never been reported before. We report herein two patients with both disorders, and possible explanations for this association are reviewed.

A 42-year-old woman had a diagnosis of CLL (CD5+ 19+ 20+ 21+ 22+ 23+ 24+ Dr+ TQ1+ FMC7- sIgMk+) in 1974, and was treated with chlorambucil from 1974 to 1978, and 1983 to 1995. In 1993, she experienced *pneumocystis carinii* pneumonia. In March 1997, a large mass developed in the abdominal wall and was surgically resected. Pathological examination revealed a desmoid tumor. Immuno-histochemically, the cells stained for vimentin and actin, but not for desmin. Cytogenetic studies performed on desmoid tumor cells were normal. At that time, the CD4 cell count was $0.55 \times 10^9/l$. Cytogenetic studies performed on peripheral blood lymphocytes revealed an abnormal karyotype with 44XX, der(4p), -5, -17, der(17) t(5;17). Because of the high incidence of desmoid tumors in the familial adenomatous polyposis (Gardner's syndrome), a total colonoscopic exam was performed. No polyp was detected. The patient is free of recurrence after 16 months.

A 50-year-old man had diagnosis of CLL (CD5+ 19+ 21+ 23+ 24+ Dr+ TQ1+ FMC7-) in 1987. He was treated with chlorambucil from 1988 to 1997. In April 1996, a large rapidly growing cervical mass developed and the diagnosis of Richter's syndrome was evoked. A surgical biopsy was performed, and a desmoid tumor was diagnosed. Complete surgical resection was performed after magnetic resonance imaging (Fig. 1). The tumor cells stained with vimentin and actin, and exhibit a normal karyotype. The CD4 cell count was $1.41 \times 10^9/l$. The karyotype performed on peripheral blood lymphocytes disclosed 46XY, del(9)(q11). A colonoscopic exam

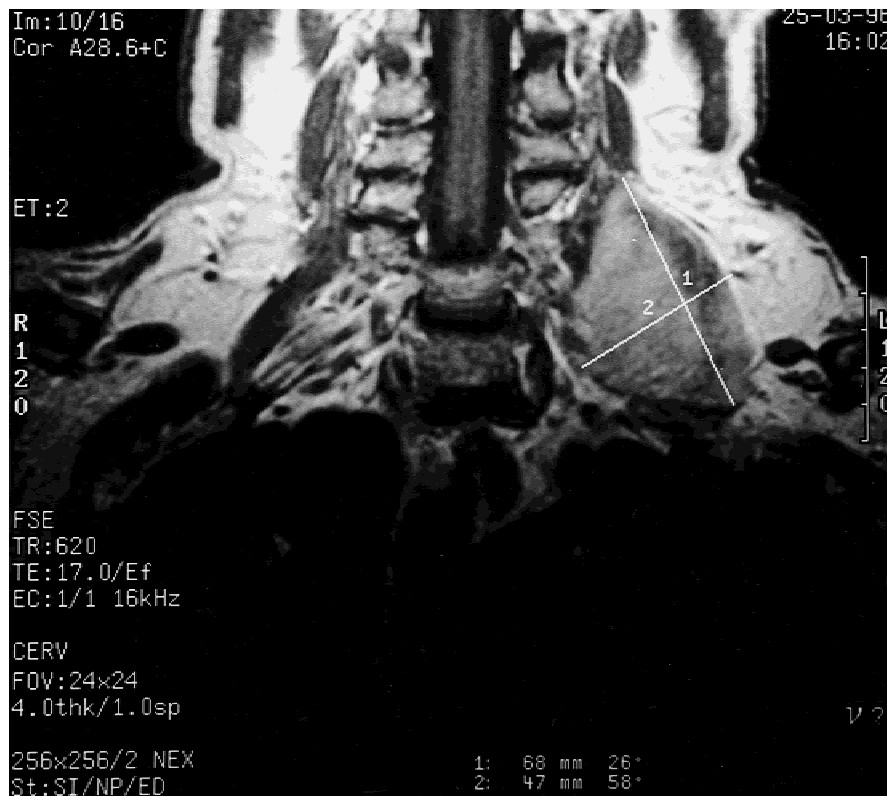

Fig. 1. Magnetic resonance imaging of desmoid tumor infiltrating the left cervical region (patient 2).

was performed and showed two benign polyps. Nine months later a thoracic malignant melanoma with axillary lymph nodes extension was diagnosed. Complete surgical resection was performed, without adjuvant therapy. Chlorambucil was stopped. The patient is free of recurrence after 27 months.

We report the association of desmoid tumors with CLL in two patients. An explanation for this apparent association is not clear. The probability of this association arising by chance is unlikely given the low incidence of desmoid tumors in the general population [1]. Trauma and radiation may serve as a trigger mechanism [1], but none of these factors were found in our patients' histories. A treatment-related second malignancy may have developed. Our two patients were treated with chlorambucil for respectively 9 and 17 years prior to developing a desmoid tumor. An increase in the incidence of epithelial tumors has been noticed in patients who have received long-term continuous chlorambucil [4]. However, to the best of our knowledge, desmoid tumors in patients treated with chlorambucil have never been described. A defect in the immune system caused by the CLL is another possible explanation. The CD4 cell count was not altered in our patients, but they experienced *pneumocystis carinii* pneumonia and malignant melanoma, two diseases known to occur in the setting of profound immunodeficiency.

Another possible explanation for the association is that there is a common predisposing factor confounding the relationship. A series of genetic mutations have been associated with desmoid tumors [1,2]. The incidence of desmoid tumors in familial adenomatous polyposis is approximately 10%. The gene of adenomatous polyposis has been identified on chromosome 5q22 [1]. The association between CLL and desmoid tumors could be explained by a common cytogenetic mechanism, however we failed to evidence this specific cytogenetic abnormality in our patients.

MARC PULIK
LAURE JARY
FRANÇOIS LIONNET
PHILIPPE GENET

Department of Hematology, Rue du Lieutenant Colonel Prudhon,
Argenteuil, France

ALAIN GAULIER

Department of Pathology, Rue du Lieutenant Colonel Prudhon,
Argenteuil, France

HOSSEIN MOSSAFA

Department of Cytogenetics, Laboratoires Cerba, Saint Ouen
l'Aumône, France

REFERENCES

1. Enzinger FM, Weiss SW, editors. Soft tissue tumors. 3rd ed. St Louis: Mosby; 1995. p 201-229.
2. Cin PD, Sciort R, Aly MS, Delabie J, Stas M, De Wever I, Van Damme B, Van den Berghe H. Some desmoid tumors are characterized by trisomy 8. *Genes Chromosome Cancer* 1994;10:131-135.
3. Travis LB, Curtis RE, Hankey BF, Fraumeni JF. Second cancers in patients with chronic lymphocytic leukemia. *J Natl Cancer Inst* 1992;84:1422-1427.
4. French Cooperative Group on Chronic Lymphocytic Leukemia. Effects of chlorambucil and therapeutic decision in initial forms of chronic lymphocytic leukemia (stage A): results of a randomized clinical trial in 612 patients. *Blood* 1990;75:1414-1421.

Severe Life-Threatening Hyperphosphatemia Associated With Tumor Lysis in a Patient With Acute Lymphoblastic Leukemia

To the Editor: Tumor lysis syndrome is a life-threatening syndrome of electrolyte derangements resulting from the mass lysis of tumor cells, and

it is commonly associated with rapidly growing tumors, especially with acute leukemias [1]. Among the electrolyte abnormalities observed, hyperphosphatemia is relatively common and may be present even before chemotherapy, due to spontaneous cell death [2]. However, severe life-threatening hyperphosphatemia in patients with tumor lysis syndrome is extremely unusual [3]. Herein we present an 18-year-old patient with T cell acute lymphoblastic leukemia (L_2) and a leukocyte count $120 \times 10^3/\mu\text{l}$ who developed severe hyperphosphatemia (serum phosphorus 18 mg/dl) within two days of starting chemotherapy with vincristine, methotrexate, and high doses of dexamethasone. The patient also developed hyperkalemia (serum potassium 5.8 mmol/l), hyperuricemia (serum uric acid 13 mg/dl), hypocalcemia (serum calcium 8.2 mg/dl), and a deterioration of renal function (serum urea 80 mg/dl, serum creatinine 1.8 mg/dl). These metabolic abnormalities were observed despite intravenous volume expansion and allopurinol administration (300 mg per day). To avoid preanalytical errors, a serum sample carefully obtained without stasis or hemolysis and immediately sent to the laboratory yielded similar results. The impressive hyperphosphatemia could be mainly due to the tumor lysis syndrome observed after initiation of chemotherapy but also encountered as a complication of steroid therapy only [4]. It is well known that tumor lysis-associated hyperphosphatemia is more profound in patients with acute lymphoblastic leukemia as blast cells contain about four times as much phosphorus than mature lymphocytes [5]. In our case, the severity of hyperphosphatemia was aggravated by the reduction in glomerular filtration rate, because if renal function is normal, severe hyperphosphatemia usually does not develop despite the accelerated phosphorus release.

Additionally, the small increase in creatine kinase levels, which was also observed after chemotherapy initiation in our patient, could be an evidence of disease- or treatment-induced muscle damage, which could have significantly contributed to the increase in serum phosphorus levels. In fact, because muscles contain substantial quantities of phosphate, muscle breakdown can release phosphate into the extracellular fluid [6].

To avoid the adverse consequences of hyperphosphatemia, treatment with normal saline and furosemide to increase elimination of phosphate was rapidly introduced. Additionally, glucose solution with insulin was also given to shift phosphate into cells. The therapy was followed by a normalization of renal function and a progressive decrease in serum phosphate toward normal levels. Since the therapy of acute leukemia has been intensified recently, the risk for development of tumor lysis and its consequences has increased as well, necessitating preventive measures, such as maintaining a good urine output, and a close monitoring of serum metabolic parameters, including serum phosphorus levels, during treatment.

HARALAMPOS J. MILONIS

House Officer, Department of Internal Medicine, Medical School,
University of Ioannina, Ioannina, Greece

MOSES S. ELISAF

Associate Professor of Medicine, Department of Internal Medicine,
Medical School, University of Ioannina, Ioannina, Greece

REFERENCES

1. Silverman P, Disrelhorst CW. Metabolic emergencies in clinical oncology. *Semin Oncol* 1989;16:504-515.
2. Arrambide K, Toto RD. Tumor lysis syndrome (Review). *Semin Nephrol* 1993;13:273-280.
3. Saleh RA, Graham-Pole J, Cumming WA. Severe hyperphosphatemia associated with tumor lysis in a patient with T-cell leukemia. *Pediatr Emerg Care* 1989;5(4):231-233.
4. Malik IA, Abubakar S, Alam F, Khan A. Dexamethasone-induced tumor lysis syndrome in high-grade non-Hodgkin's lymphoma. *South Med J* 1994;87(3):409-411.
5. Bourke E, Yanagawa N. Assessment of hyperphosphatemia and hypophosphatemia (Review). *Clin Lab Med* 1993;13:183-207.
6. Thomas MAA, Ibels LS. Rhabdomyolysis and acute renal failure. *Aust N Z J Med* 1985;15:623-628.

Low Seroprevalence of *Helicobacter pylori* in Patients With Leukemia

To the Editor: *Helicobacter pylori* (*H. pylori*) causes peptic ulcer disease (PUD), gastric cancer, and MALTOMA. Seroprevalence of *H. pylori* is low in patients receiving organ transplants, possibly due to the use of antibiotics [1,2]. However, commonly prescribed antibiotics cannot control *H. pylori* infection [3]. *H. pylori* eradication requires oral administration of antibiotics with sufficient acid suppression. Thus, parenteral antibiotics may not eradicate *H. pylori*. We checked seroprevalence of *H. pylori* in patients with leukemia to evaluate the anti-*H. pylori* property of parenteral antibiotics; those were used during remission induction therapy.

Fifty-seven patients with leukemia (more than three months after complete remission had been verified) were enrolled in the study. They consisted of acute myelogenous leukemia, acute lymphocytic leukemia (ALL), and chronic myelogenous leukemia after blastic crisis. They had been treated with chemotherapy, and patients with ALL received cytosine arabinoside. As controls, 49 healthy individuals (22 were endoscopically normal) and 49 endoscopically proven PUD patients without immunohematologic disorders were enrolled. Following informed consent, the sera were obtained. To ensure accuracy for harboring *H. pylori* and to make independency from patients' immune systems, serum levels of pepsinogens were measured [4,5]. Titers of anti-*H. pylori* IgG antibody were measured with an ELISA kit (Determiner: Kyowa Medex Co., Ltd., Tokyo). Serum pepsinogens I and II were measured with RIA kits (Pepsinogen I · RIA beads and II · RIA beads; Dynabot Japan, Tokyo). Statistical significance was evaluated using one-way factorial ANOVA and multiple comparison tests, and chi-square test.

Table I shows the differences between three groups in age, seroprevalence of anti-*H. pylori* antibody, and serum pepsinogens. There were differences in *H. pylori* seroprevalence between all groups: 19.3% for leukemia, 38.8% for healthy individuals, and 87.7% for PUD. Concerning serum pepsinogens, leukemic patients manifested the lowest levels of both serum pepsinogens I and II ($P < 0.001$ except in comparison with pepsinogen I in normal individuals). Leukemic patients showed the highest pepsinogen I/II ratio suggesting a negative likelihood for harboring *H. pylori* [4,5].

We verified that *H. pylori* seroprevalence was less in patients with leukemia than it was in immunohematologically normal individuals, irrespective of the presence or absence of PUD. This phenomenon was supported by the serum pepsinogen levels, i.e., the pepsinogen I/II ratio in the leukemic patients was highest among the three groups. The immunohematologically normal individuals showed lower pepsinogen I/II ratio and higher levels of pepsinogen II compared with the leukemic patients. Successful eradication of *H. pylori* results in an increased pepsinogen I/II ratio [4], and *H. pylori*-seropositive individuals manifest lower levels of serum

pepsinogen II than *H. pylori*-seronegative individuals [5]. Both results, low seroprevalence of *H. pylori* and high ratio of serum pepsinogen I/II, suggest that systemic administration of antibiotics during remission induction therapy eradicates *H. pylori*. The discrepancy in anti-*H. pylori* seroprevalence between leukemic patients and other antibiotic users could be due to the differences in dosage, i.e., leukemic patients receive multiple and lengthy use of antibiotics, resulting in a greater cumulative dose than commonly administered doses. Such antibiotic treatments during remission induction therapy appear to eradicate *H. pylori*.

YOSHIHIRO MATSUKAWA
TAKEYOSHI ITOH
SUSUMU NISHINARITA
TOSHITERU OHSHIMA
TAKASHI HORIE

First Department of Internal Medicine, Nihon University School of Medicine, Tokyo, Japan

SHIN AIZAWA

First Department of Anatomy, Nihon University School of Medicine, Tokyo, Japan

AKITAKA SUZUKI
KEISUKE TOYAMA

First Department of Internal Medicine, Tokyo Medical College, Tokyo, Japan

SATOSHI TAKAHASHI
SHIGETAKA ASANO

The Institute of Medical Science, University of Tokyo, Tokyo, Japan

TETSUYA MINE

Fourth Department of Internal Medicine, University of Tokyo School of Medicine, Tokyo, Japan

REFERENCES

1. Dummer JS, Perez-Perez GI, Breining MK, Lee A, Wolf SN, Kormos R, Griffith BP, Blaser MJ. Seroepidemiology of *Helicobacter pylori* infection in heart transplant recipients. Clin Infect Dis 1995;21:1303.
2. Rudi J, Engler S, Theilmann L, Otto G, Stremmel W. Prevalence of serum antibodies to *Helicobacter pylori* and to CagA protein in liver transplant recipients. Am J Gastroenterol 1997;92:1492.
3. Rothenbacher D, Bode G, Adler G, Brenner H. Use of commonly prescribed antibiotics is not associated with prevalence of *Helicobacter pylori* infection in adults. Scand J Gastroenterol 1997;32:1096.
4. Furuta T, Kaneko E, Baba S, Arai H, Futami H. Percentage changes in serum pepsinogens are useful as indices of *Helicobacter pylori*. Am J Gastroenterol 1997;92:84.
5. Asaka M, Kimura T, Kubo N, Takeda H, Mitani S, Miyazaki T, Miki K, Graham DY. Relationship of *Helicobacter pylori* to serum pepsinogens in an asymptomatic Japanese population. Gastroenterology 1992;102:760.

TABLE I. Seroprevalence of *Helicobacter pylori* and Levels of Serum Pepsinogens in Patients With Leukemia in Remission†

	Leukemia	Normal	Peptic ulcer
No. of patients	57	49	49
Age (years)	39.5 ± 15.1	40.9 ± 7.7	42.1 ± 6.4
α HP (%)	11/57 (19.3)	19/49 (38.8)	43/49 (87.7)
PG I (ng/mL)	42.5 ± 17.4	44.2 ± 23.1**	61.8 ± 32.4*
PG II (ng/mL)	8.44 ± 4.91	14.2 ± 9.52*	16.3 ± 10.1*
PG I/PG II	5.72 ± 2.01	3.86 ± 1.73*	4.19 ± 1.31*

†Data are expressed as mean ± SD. HP, *Helicobacter pylori*; PG, pepsinogen.

* $P < 0.001$.

** $P < 0.01$ vs. leukemia.

Uterine Infiltration as First Sign of Acute Myeloid Leukemia

To the Editor: Extramedullary leukemic infiltration can occur during the evolution of acute myeloid leukemia (AML), but is rarely of clinical importance at diagnosis and in the early stages of the disease. We report here in the case of a 41-year-old woman with a uterine infiltration as presenting sign of AML.

The patient was admitted to the hospital because of dyspareunia. Gynecological examination revealed a tender, polylobulated cervical mass infiltrating the para-uterine tissues. Abdominal CT scan showed in addition multiple, necrotic, retro-peritoneal, and iliac adenopathies (Fig. 1). Blood

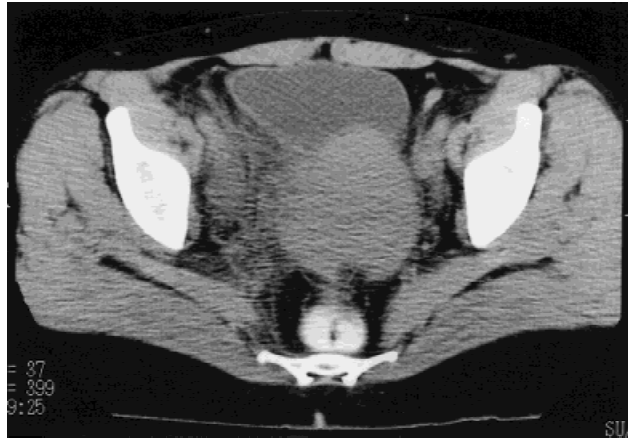

Fig. 1. Abdominal CT scan showing infiltration of uterus and para-uterine tissues.

chemistry was as follows: CRP 20.2 mg/L, proteins 62 g/L, LDH 836 U/L. Blood cell counts were: Hb 12.5 g/dL, Ht 36% (MCV 90.3), WBC $86.2 \times 10^9/L$ with 10% neutrophils, 1% eosinophils, 1% lymphocytes, and 88% blasts (exhibiting a high nucleocytoplasmic ratio, a basophilic cytoplasm, a cleaved cell nucleus but no Auer rods), and thrombocytes $131 \times 10^9/L$.

Bone marrow aspiration revealed a massive (>90%) infiltration by blasts expressing the same morphological characteristics as the blasts found in the periphery. These blasts stained positive for myeloperoxidase and Sudan black, but negative for myelocytic and monocytic esterase. No karyotypic abnormalities were detected by conventional analysis (28 mitoses examined).

On cytofluorometric analysis the blasts were CD13, CD33, CD2, DC4, and CD34 positive.

The diagnosis of AML type M1 was made according to the FAB criteria.

Histologic examination of a cervical biopsy showed a massive infiltration by chloracetate esterase- and peroxidase-positive leukemic blasts.

The patient underwent two cycles of chemotherapy (Ara-C/idarubicine; Ara-C/AMSA). A control bone marrow aspiration performed 4 weeks after the first cycle showed complete disappearance of the leukemic infiltration; similarly, a CT scan showed disappearance of the adenopathies and the para-uterine infiltration. The patient was subsequently treated with an allogeneic bone marrow transplantation from her human leukocyte antigen-compatible sister. One year after transplantation, the patient is still in complete remission.

In AML, aggregates and infiltration of leukemic cells are often found in biopsies made during the evolution of the disease, in autopsies, and more rarely, at diagnosis, where they constitute the first sign of the leukemia. Involvement of nearly every organ has been described [1], but in most cases infiltrations were due to blasts of the M4 or M5 subtype of AML.

Leukemic infiltrations of urogenital system tissue have, until now, only rarely been reported: single cases of kidney, bladder neck, prostatic, or testicular involvement have been described [2,3]. Uterine infiltration has also been reported in one patient, but as a first sign of relapse after chemotherapy, and not as the presenting symptom at diagnosis [4].

The uterine mucosa is infiltrated by CD56 positive natural killer (NK) cells, which are particularly abundant around the time of implantation and during early pregnancy, and are possibly involved in trophoblast migration and establishment of the placenta [5]. As CD56 is an adhesion molecule, it could play an active role in the homing of NK cells to the uterus and perhaps, similarly, in the highly unusual accumulation of myeloid blasts in the uterus of our patient. We indeed found that the blasts highly expressed CD56.

THOMAS MATTHES
CLAUDIA COLLAO
KAVEH SAMI
BERNARD CHAPUIS

*Division of Hematology, Hôpital Cantonal Universitaire,
Genève, Switzerland*

CHRISTOPHE GIRARDET
SOPHIE DIEBOLD-BERGER

*Division of Pathology, Hôpital Cantonal Universitaire,
Genève, Switzerland*

REFERENCES

1. Beutler E, Lichtman MA, Coller BS, Kipps TJ. In: Williams hematology. 5th ed. 1995. p 274.
2. Russo A, Basquez E, Russo G, Schilvio G. Testicular relapse in acute myelogenous leukaemia after 3½ years of complete remission. *Acta Haematol (Basel)* 1981;65:131-134.
3. Quien ET, Wallach B, Sandhaus L, Kidd P, Strair R, Saidi P. Primary extramedullary leukaemia of the prostate: case report and review of the literature. *Am J Hematol* 1996;53(4):267-271.
4. Shiga Y, Shichishima T, Aikawa K, Gotoh J, Furukawa T, Yamagiwa A, Ishibashi T, Maruyama Y. A case of acute nonlymphocytic leukaemia with leukaemic cell infiltration to the uterus followed by bone marrow relapse. *Rinsho Ketsueki* 1994;35(5):501-505.
5. King A, Burrows T, Loke YW. Human uterine natural killer cells. *Nat Immun* 1996-97;15:41-52.