The Maturation of the Rabbit Fetal Lung following Maternal Administration of Pilocarpine

DENNIS M. SMITH,[1] SUE A. SHELLEY [2] AND JOHN U. BALIS [2]
Departments of Pathology and Anatomy, Loyola University Stritch School of Medicine, Maywood, Illinois 60153

ABSTRACT Pilocarpine HCl, a parasympathomimetic drug, was administered to pregnant white rabbits in a daily subcutaneous injection of 5 mg/kg on days 24 through 27 of gestation. Fetuses from these animals and from saline-injected controls were obtained by caesarean section at day 28 of gestation. Light microscopic examination revealed thinner alveolar septa in the lungs of pilocarpine-treated fetuses and, morphometrically, a significant increase in the number of mature type II cells, both per unit area and per 1,000 lung cells of any kind. Examination by electron microscopy revealed that the alveolar epithelium of pilocarpine-treated fetuses demonstrated morphologic correlates of increased maturation. These included thinning of type I cells to form blood-air barriers and substantial reductions in the glycogen content of both epithelial cell types. Type II cells of pilocarpine-treated fetuses contained (as indicated by morphometric analysis) more and larger lamellar inclusion bodies, as well as more multivesicular bodies than those of controls. Biochemical determination indicated that the glycogen content of fetal lung, but not liver, was reduced significantly in the pilocarpine-treated group. The findings of this study indicate that maternal administration of pilocarpine results in increased maturation of the fetal alveolar epithelium, thus providing a basis for the autonomic manipulation of fetal lung maturation.

It is well established that immaturity of the lung is the primary etiologic factor predisposing to the development of the respiratory distress syndrome of the newborn, the primary cause of death in premature infants (Gluck and Kulovich, '73). The overall maturity of the fetal lung has been found to depend to a great extent on the maturity of the type II epithelial cells of the alveolus. These cells are the recognized source of lung surfactant, a surface tension lowering substance, rich in dipalmitoyl phosphatidylcholine, which lines the alveolar space (for review see Farrell and Avery, '75). The type II cells contain characteristic lamellar inclusion bodies, the intracellular storage form of surfactant, as well as other secretory elements including rough endoplasmic reticulum, Golgi apparatus and multivesicular bodies, the presumed precursors of lamellar inclusion bodies.

Type II cells, as well as the attenuated type I cells, differentiate from immature cuboidal cells which contain abundant glycogen, an undeveloped secretory apparatus and no lamellar inclusion bodies (Kikkawa et al., '68, '71). Indicative of the maturational changes of type II cells from these cuboidal precursors are a marked decrease in glycogen content, development of the rough endoplasmic reticulum and Golgi complex and, as the secretory apparatus matures, a concomitant increase in the number of multivesicular bodies and lamellar inclusion bodies.

Previous studies have indicated that glucocorticoids, and perhaps other pharmacologic agents, promote fetal lung maturation by accelerating the structural, functional and biochemical development of the alveolar type II cells (for review see Avery, '75). Pilocarpine, a parasympathomimetic alkaloid, has been shown by previous morphological studies to stimulate the secretion of surfactant by type II cells of the adult rat (Goldenberg et al.,

Received June 19, '78. Accepted Aug. 23, '78.

[1] This work done in partial fulfillment of the requirements for the Ph.D. degree, department of Anatomy, Loyola University of Chicago graduate school.

[2] Present address: Department of Pathology, University of South Florida School of Medicine, Tampa, Florida 33612.

'69). Other studies have suggested that administration of pilocarpine to adult animals results in a reduction of minimal surface tension of lung extracts (Kirkland, '70), enhancement of phospholipid release (Olsen, '72) and an acceleration of lecithin turn-over (Morgan and Morgan, '73). In addition, Massaro ('75) found that pilocarpine stimulated the release of protein into the surface-active fraction of rabbit lungs.

There is little information available concerning the effects of pilocarpine on the surfactant system of fetal animals. However, physiologic evidence has indicated that pilocarpine does lower the surface tension in lungs of fetal rabbits, presumably by increasing the secretion of surfactant (Corbet et al., '76). In addition, recent studies have indicated that pilocarpine stimulates surfactant release from fetal rat lung in culture (Pysher et al., '77). The present study was designed to investigate the reactions of the developing fetal rabbit lung to maternally administered pilocarpine, using morphologic methods primarily.

MATERIALS AND METHODS

A total of 33 (18 control, 15 experimental) female New Zealand white rabbits (Langshaw farms, Augusta, Michigan) were mated under direct observation and the time of mounting was considered to be time zero of gestation. The rabbits were at all times maintained on a diet of approximately 90 g of standard lab chow per day, and were allowed water ad libitum. Pregnant rabbits received a daily subcutaneous dose of pilocarpine HCl (Sigma), 5 mg/kg in 1 ml of saline, on days 24 through 27 of gestation. Pregnant rabbits injected with saline, alone, served as controls.

At the twenty-eighth gestational day venous blood was collected from the pregnant does for evaluation by the SMA-12 test series. This test provides quantitative data for the following serum constituents: calcium, inorganic phosphates, glucose, blood urea nitrogen (BUN), uric acid, cholesterol, total phosphorus, albumin, total bilirubin, alkaline phosphatase, LDH and SGOT. The does were killed using air embolism and the fetuses were obtained by immediate hysterotomy. Following removal of the amniotic sac the fetuses were prevented from breathing by the application of pressure on the trachea, and then weighed. In order to maintain uniformity between experiments, fetuses of corresponding uterine placement were used for each procedure. The most lateral fetus of the right uterine horn was removed first and the thorax opened by a mid-ventral incision. The entire upper and lower lobes of the right lung were each removed, chopped independently into approximately 1 mm cubes and fixed in 2% phosphate-buffered glutaraldehyde. The left lung was fixed in toto by immersion in 10% buffered formalin. Concurrently, lungs and livers of fetuses removed from the left uterine horn were frozen immediately by immersion in liquid nitrogen.

Formalin-fixed tissues were embedded in paraffin, cut at 4-6 μm, stained with hematoxylin and eosin or periodic acid-Schiff (PAS), with or without diastase pretreatment, and examined by light microscopy. The glycogen content of the lungs and livers which were quick-frozen was determined using the method of Murat and Serfaty ('74).

The lung tissues placed in glutaraldehyde were allowed to fix overnight in the original solution. They were washed in Sorenson's phosphate buffer, post-fixed in 1% buffered osmium tetroxide for two hours, dehydrated rapidly through a graded ethanol series and propylene oxide, and embedded in Epon 812. Sections 1 μm thick were cut from randomly selected blocks, stained with toluidine blue and photographed at 400 $\times$ magnification on Kodak PCF3 film. The transparencies thus obtained were used in a blind study where the number of cells of any type, as well as the number of mature type II alveolar epithelial cells per unit area (0.035 mm^2) was recorded. Cells of bronchioles or blood vessels larger than capillaries were not included in the cell count and the area occupied by these cells was determined using a standard grid pattern and subtracted from the unit area of the slide. Results were expressed as type II cells/unit area and type II cells/1,000 cells.

Thin (60-80 nm) sections were obtained from the same blocks, stained with uranyl acetate and lead citrate and examined in an RCA EMU-3 electron microscope. In addition to observation of ultrastructural features, a morphometric analysis of lamellar inclusion bodies and multivesicular bodies in the type II cells of control and pilocarpine-treated fetuses was undertaken. Thin sections of lung from six fetuses in each group, all from different litters, were evaluated in a double blind study. All alveolar epithelial cells which were cuboidal and possessed microvilli were photo-

graphed at a standard magnification. This resulted in photographs of at least 120 cells from each of the upper and lower lobes of the two groups. Using the photographs, the number of inclusion bodies and multivesicular bodies in each cell was recorded, as well as the size, measured at its maximum diameter, of each lamellar inclusion body present.

All data were analyzed using Student's t-test.

RESULTS

Following each pilocarpine injection the pregnant does exhibited all the signs expected from the administration of a parasympathomimetic agent. Salivation, lacrimation and diarrhea began approximately 15 minutes post-injection and persisted for about three hours. The pilocarpine-treated does exhibited a mild weight loss (average of 3.8%) compared to a slight weight gain in the control animals during the same time period (average of 2.4%). This difference was thought to be due to diarrhea since the food and water intake were essentially the same in control and treated animals. Furthermore, the results of the SMA-12 tests on the serum of the two groups showed no significant differences in any of the 12 parameters tested.

Fetuses of control and pilocarpine-treated mothers (hereafter for convenience referred to as control or pilocarpine-treated fetuses) were comparable grossly, with an occasional dwarf or dead fetus being found in each group. The average weight of the pilocarpine-treated fetuses from eight does was 26.95 g (± 1.97, SEM) as compared with 35.42 g (± 1.42) for control fetuses. Grossly the lungs of pilocarpine-treated fetuses appeared normal.

By light microscopy the lungs of pilocarpine-treated fetuses appeared to possess thinner alveolar septa and more numerous blood-air barriers than control fetal lungs (compare figs. 2, 4). The alveoli of the control lungs were lined by immature cuboidal epithelial cells as well as type I and type II cells (fig. 3). Examination of PAS-stained paraffin sections showed a marked decrease in the amount of PAS-positive material in the lung cells of pilocarpine-treated fetuses. In slides stained with PAS after diastase pretreatment, no difference was noted between pilocarpine-treated and control fetal lungs, indicating that the difference originally noted in PAS staining was due to glycogen content. The validity of this observation was substantiated by the biochemical determination of glycogen content, which was found to be significantly reduced in pilocarpine-treated fetuses (table 1). There was no significant difference in the value for fetal liver between the two groups, indicating that pilocarpine administration did not induce a generalized depletion of glycogen stores.

Light microscopic morphometric analysis revealed a significant increase in the number of mature type II cells in the lungs of pilocarpine treated fetuses, both per unit area and per 1,000 lung cells of any kind (fig. 1). Such a study was possible since mature, or well differentiated type II cells are readily recognizable in 1-μm sections by their size, shape and, most importantly, the presence of lamellar inclusion bodies (figs. 3, 5).

Ultrastructural examination revealed that the alveoli of control fetuses were lined by immature cuboidal cells as well as type I and type II cells. The nuclei of type I cells in control fetal lungs were often surrounded by relatively abundant cytoplasm, indicative of an immature state. While the cytoplasmic processes of these cells in some areas formed blood-air barriers, these processes were frequently thick and contained, in addition to abundant glycogen, mitochondria and rough endoplasmic reticulum (fig. 6). Type II cells present in controls contained abundant glycogen, a poorly developed secretory apparatus and relatively few multivesicular bodies (figs. 8, 10). The inclusion bodies present in these cells often possessed a homogeneous core surrounded by relatively few lamellae.

The alveolar epithelium of pilocarpine-treated fetuses demonstrated striking ultra-

TABLE 1

Glycogen content (mg/gm tissue)

	Number of litters	Number of fetuses	Lung	Liver
Control	5	17	4.11±0.33	16.98±2.03
Pilocarpine	7	25	2.65±0.13	14.98±1.30
			$p<0.001$	n.s.

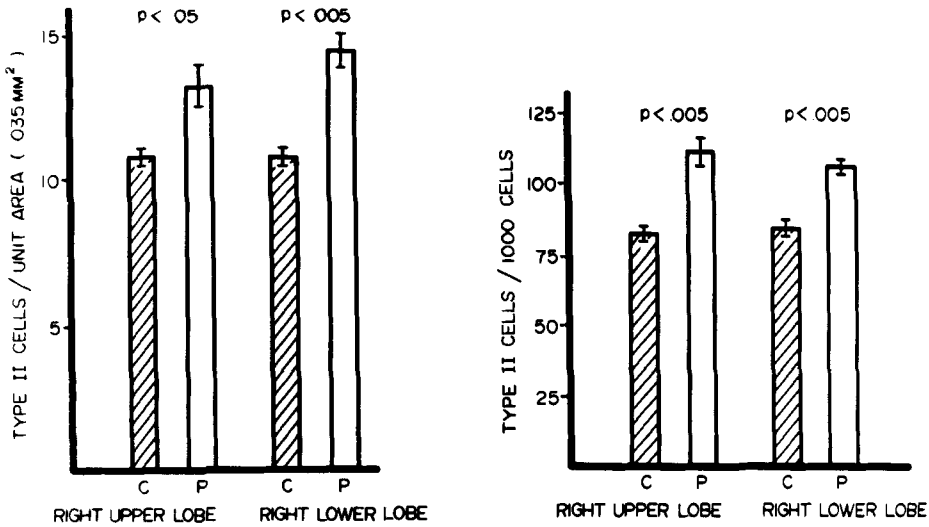

Fig. 1 The histogram on the left illustrates the numerical distribution of mature, or well differentiated type II alveolar epithelial cells per unit area (0.035 mm^2) of a 1-μm-thick section of fetal lung from the upper and lower lobe of each group. On the right is a similar histogram of the number of mature type II cells per 1,000 lung parenchymal cells. P, pilocarpine treated; C, control.

structural differences from controls. The most prominent change was the virtual absence of glycogen in many of these cells. Type I cells of pilocarpine-treated fetuses appeared, in general, at a more advanced stage of maturation than did those of controls. The cytoplasm of the cell body formed a thin rim around the nucleus and the cell processes were attenuated to form blood-air barriers (fig. 7). When glycogen was present in the type II epithelial cells of pilocarpine-treated fetuses it was usually found in association with surfactant material (fig. 11). Additional findings in these cells frequently included an increase or dilation of the rough endoplasmic reticulum associated with the presence of relatively numerous multivesicular bodies and large, densely osmiophilic lamellar inclusion bodies with well defined lamellae, which, according to Kikkawa's classification ('68), would represent more mature forms (figs. 9, 11). Lamellar bodies in type II cells of pilocarpine-treated fetuses were also seen in the process of being secreted into the alveolar space (fig. 9) with greater frequency than in controls, where this was rarely observed. Also observed more often in pilocarpine-treated fetuses were membranous whorls and segments of tubular myelin, indicative of surfactant lipids in the alveolar space. The remainder of the organelles within the type II cells were much the same in the two groups with the exception of the Golgi apparatus, which was prominent or multiple with greater frequency in the type II cells of pilocarpine-treated fetuses.

Ultrastructural morphometric analysis substantiated the above stated subjective interpretations of the electron microscopic findings. The results, listed in table 2, indicate that the number of lamellar inclusion bodies per type II cell, the average size of the lamellar inclusion bodies and the number of multivesicular bodies per ten type II cells were all increased significantly in the pilocarpine-treated group when compared with controls.

DISCUSSION

The findings of this study indicate that administration of pilocarpine to pregnant rabbits results in accelerated maturation of the fetal lung. Morphological correlates of increased maturation were apparent when fetuses were obtained at the twenty-eighth gestational day.

Based on electron microscopic examination of fetal rabbit lung it was determined that the twenty-eighth gestational day was best suited for the elucidation of changes occurring in the lungs of pilocarpine-treated fetuses. At this time control fetal lungs were found to be relatively immature, in that the glycogen content of alveolar epithelial cells was high and cuboi-

TABLE 2

Results of electron microscopic morphometric analysis

Parameter	Control	Pilocarpine	p
Inclusion bodies/type II cell			
Upper lobe	3.95 ±0.48	5.36 ±0.37	<0.05
Lower lobe	3.19 ±0.39	5.02 ±0.40	<0.01
Size of inclusion bodies (μm)			
Upper lobe	0.692±0.024	0.813±0.017	<0.001
Lower lobe	0.674±0.034	0.836±0.031	<0.005
Multivesicular bodies/ten type II cells			
Upper lobe	1.93 ±0.45	3.02 ±0.43	<0.05
Lower lobe	1.47 ±0.29	3.43 ±0.78	<0.05

dal cells lining the alveoli contained few, if any, lamellar inclusion bodies. These findings are at variance with those of Kikkawa et al. ('68, '71) who observed no glycogen in alveolar epithelial cells at day 28 of gestation. The reason for this discrepancy between our results and those of Kikkawa is not clear, but may in part be related to differences in buffer or dehydration procedure used. Studies in our laboratory have indicated that phosphate-buffered glutaraldehyde and a rapid dehydration procedure are necessary for optimum preservation of the glycogen present in fetal rabbit alveolar epithelium (unpublished observations).

In the present study pilocarpine was administered by a maternal route to avoid the possibility of maturational changes brought about simply by the trauma inherent in the operational procedure used to inject drugs in utero. In a study by Robert et al. ('75), confirmed by pilot experiments in our laboratory, it was observed that the lungs of fetuses injected with saline in utero showed evidence of a marked acceleration of maturation when compared to similar fetuses of non-operated mothers. In addition, a primary aim of our study was to evaluate the effect of repeated stimulation over a period of several days, which necessitated employing the maternal route. It was assumed that pilocarpine would cross the placental barrier since it is well established that the vast majority of compounds with a molecular weight less than 600 readily cross this barrier (Mirkin and Singh, '76) and pilocarpine HCl has a molecular weight of 244.7.

Based on the study by Goldenberg et al. ('69) using adult rats, we initially injected 150 mg/kg pilocarpine subcutaneously. Although this dose worked well in non-pregnant rabbits, when administered to pregnant does it resulted in immediate convulsions and death. Subsequent experimentation revealed the dosage of 5 mg/kg to be optimal insofar as the pregnant females exhibited all the signs of parasympathetic stimulation but neither the doe nor the fetuses suffered any increase in mortality. Data obtained in this study did, however, reveal that the body weight of the pilocarpine-treated fetuses was decreased somewhat compared to controls. The reason for this reduction in weight is unclear; however, it is apparently not directly related to malnutrition since food intake of the mother and fetal liver glycogen were not reduced from controls. Similar weight losses have been described previously in cortisol-treated rabbit fetuses (Motoyama et al., '71).

Our data indicated a significant increase in the number of mature type II cells per unit area as well as an increase relative to the total number of lung cells. It is of interest that Kauffmann ('77), using similar morphometric techniques, found results much like those of the present study in an investigation of maturational changes in the lungs of fetal mice following maternal administration of dexamethasone.

Ultrastructural morphometric analysis indicated that the number and size of lamellar inclusion bodies, as well as the number of multivesicular bodies, were increased significantly in the pilocarpine-treated group. Therefore, not only are there greater numbers of mature type II cells in the lungs of pilocarpine-treated fetuses, but these cells contain more, and larger, inclusion bodies, as well as more multivesicular bodies than do type II cells of controls. This would indicate that repeated stimulation of the exocrine function of fetal alveolar epithelium with pilocarpine treatment causes not only an increased secretion of

surfactant, as does a single dose (Corbet et al., '76), but also an increased synthesis and storage of surfactant by type II cells.

It is appropriate to mention that certain forms of fetal distress may produce changes in the fetal lung similar in some respects to those in the present study. These changes include an initial stimulation of secretion by type II cells and a transitory acceleration of maturation (Balis et al., '75). However, in the reaction to stress or injury, these changes are accompanied by septal edema and cellular proliferation, neither of which was observed in the present study. Additionally, increased synthesis and secretion of surfactant material was reported by Kikkawa and Motoyama ('73) in fetal rabbits treated with AY-9944, an inhibitor of cholesterol biosynthesis. This stimulation, however, was accompanied by retardation of the general maturation of the lung, which was again not true in the present study.

Pilocarpine has been reported to be capable of stimulating the secretion of surfactant by type II cells in adult animals (Goldenberg et al., '69; Morgan and Morgan, '73). Corbet et al. ('76) have demonstrated that direct administration of pilocarpine to fetuses in utero results in a reduction of surface tension, indicating increased secretion of surfactant. The mechanism by which pilocarpine causes this secretion is, however, unclear and several possible explanations exist. For example, although primarily a parasympathomimetic cholinergic agent, pilocarpine stimulates the adrenal medulla and, in addition, the possibility exists that pilocarpine stimulates certain nerves in the central nervous system, since it is readily diffusible through lipid membranes (Koelle, '70).

Hung et al. ('72) demonstrated axonal endings of an autonomic nature in close proximity to type II pneumocytes and concluded that these provided a morphologic connection between the autonomic nervous system and surfactant secretion. In a recent pharmacologic study, Corbet et al. ('77) theorized that the action of pilocarpine in lowering the surface tension of lung extracts may be due to sympathetic stimulation. Some studies have indicated, however, that sympathetic stimulation results in increased surface tension in the lungs (Beckman et al., '71). Therefore, although the question of whether the effect of pilocarpine is due to parasympathetic or sympathetic activation remains unresolved, it seems highly probable that its action is related to the existence of an autonomic control mechanism for surfactant secretion.

The findings of the present study indicate that repeated pilocarpine stimulation of the fetal rabbit surfactant system results in increased maturation of the type II epithelium of the alveolus, and of the lung as a whole. The protocol of this study does not absolutely rule out the possibility of endogenous corticosteroid influence. However, Pysher et al. ('77) have demonstrated that fetal lung in culture is responsive to pilocarpine. Although the natural role of the autonomic nervous system in the developing lung is unknown, our results indicate that the maturation of the fetal lung can be influenced through autonomic manipulation.

ACKNOWLEDGMENTS

This study was supported by NIH Grant HD-04434.

The authors wish to thank Doctor Gissur Brynjolfsson, Chairman, department of Pathology, Loyola University Stritch School of Medicine, for his strong support and encouragement of this study. The authors gratefully acknowledge the technical assistance of Elaine Smith, Maria Mezari and Barbara Kirby.

LITERATURE CITED

Avery, M. E. 1975 Pharmacologic approaches to the acceleration of fetal lung maturation. Br. Med. Bull., *31:* 13-17.

Balis, J. U., P. Pagast, L. McKeever and S. Shelley 1975 Perinatal reactions of the rabbit lung to maternal endotoxemia. Lab. Invest., *33:* 289-297.

Beckman, D. L., J. W. Bean and D. R. Baslock 1971 Sympathetic influence on lung compliance and surface forces in head injury. J. Appl. Physiol., *30:* 394-399.

Corbet, A. J. S., P. Flax and A. J. Rudolph 1976 Reduced surface tension in lungs of fetal rabbits injected with pilocarpine. J. Appl. Physiol., *41:* 7-14.

——— 1977 Role of autonomic nervous system controlling surface tension in fetal rabbit lungs. J. Appl. Physiol., *43:* 1039-1045.

Farrell, P. M., and M. E. Avery 1975 Hyaline membrane disease. Am. Rev. Resp. Dis., *111:* 657-688.

Gluck, L., and M. V. Kulovich 1973 Fetal lung development. Current concepts. Ped. Clin. N. Amer., *20:* 367-379.

Goldenberg, V. F., S. Buckingham and S. C. Sommers 1969 Pilocarpine stimulation of granular pneumocyte secretion. Lab. Invest., *20:* 147-158.

Hung, K. S., M. S. Hertweck, J. D. Hardy and C. G. Loosli 1972 Innervation of pulmonary alveoli of the mouse lung: An electron microscopic study. Am. J. Anat., *135:* 477-496.

Kauffman, S. L. 1977 Acceleration of canalicular development in lungs of fetal mice exposed transplacentally to dexamethasone. Lab. Invest., *36:* 395-401.

Kikkawa, Y., M. Kaibara, E. K. Motoyama, M. M. Orzalesi

and C. D. Cook 1971 Morphologic development of fetal rabbit lung and its acceleration with cortisol. Am. J. Pathol., *64:* 423-443.

Kikkawa, Y., and E. K. Motoyama 1973 Effect of AY-9944, a cholesterol biosynthesis inhibitor, on fetal lung development and on the development of type II alveolar epithelial cells. Lab. Invest., *28:* 48-54.

Kikkawa, Y., E. K. Motoyama and L. Gluck 1968 Study of the lungs of fetal and newborn rabbits. Morphologic, biochemical and surface physical development. Am. J. Pathol., *52:* 177-192.

Kirkland, V. L. 1970 Effect of pilocarpine on pulmonary surfactant in the rat. Pharmacologist, *12:* 264.

Koelle, K. B. 1970 Neurohumoral transmission and the autonomic nervous system. In: The Pharmacologic Basis of Therapeutics. L. S. Goodman and A. Gilman, eds. New York, Macmillan, pp. 402-441.

Massaro, D. 1975 In vivo protein secretion by lung. Evidence for active secretion and interspecies differences. J. Clin. Invest., *56:* 263-271.

Mirkin, B. L., and S. Singh 1976 Placental transfer of pharmacologically active molecules. In: Perinatal Pharmacology and Therapeutics. B. L. Mirkin, ed. Academic Press, New York, pp. 1-69.

Morgan, T. E., and B. C. Morgan 1973 Surfactant synthesis, storage and release by alveolar cells. In: Respiratory Distress Syndrome. C. A. Vilee, D. B. Vilee and J. Zuckerman, eds. Academic Press, New York, pp. 117-125.

Motoyama, E. K., M. M. Orzalesi, Y. Kikkawa, M. Kaibara, B. Wu, C. J. Zigas and C. D. Cook 1971 Effect of cortisol on the development of fetal rabbit lungs. Ped., *48:* 547-555.

Murat, J. C., and A. Serfaty 1974 Simple enzymatic determination of polysaccharide (glycogen) content of animal tissues. Clin. Chem., *20:* 1576-1577.

Olsen, D. B. 1972 Neuro-humoral secretory stimulation of pulmonary surfactant in the rat. Physiologist, *15:* 230.

Pysher, T. J., K. D. Konrad and G. B. Reed 1977 Effects of hydrocortisone and pilocarpine on fetal rat lung explants. Lab. Invest., *37:* 588-594.

Robert, M. V., A. T. Bator and H. W. Taeusch 1975 Pulmonary pressure-volume relationships after corticotropin (ACTH) and saline injections in fetal rabbits. Ped. Res., *9:* 760-761.

Abbreviations

A, Alveolar space
C, Capillary space
c, Cuboidal epithelial cell
E, Endothelial cell of capillary
G, Glycogen
L, Lamellar inclusion body
M, Mitochondrion
MV, Multivesicular body
N, Nucleus
R, Rough endoplasmic reticulum
S, Surfactant material
T, Transitional form of inclusion body

PLATE 1

EXPLANATION OF FIGURES

2 Low-power micrograph of a 1-μm-thick toluidine blue-stained section of control fetal lung. Note thick alveolar septa and relatively sparse blood-air barriers. × 550.

3 Same lung as figure 2, higher magnification. A mature type II cell is shown at the arrow. Portions of the alveolar space are lined by immature cuboidal cells (c) which contain abundant darkly stained glycogen. × 2,200.

4 Section of lung from a 28-day pilocarpine-treated fetus. Note thinner alveolar septa and better development of blood-air barriers. × 550.

5 Same lung as figure 4, higher magnification. Mature type II cells containing intensely stained lamellar inclusion bodies are noted at the arrows. × 2,200.

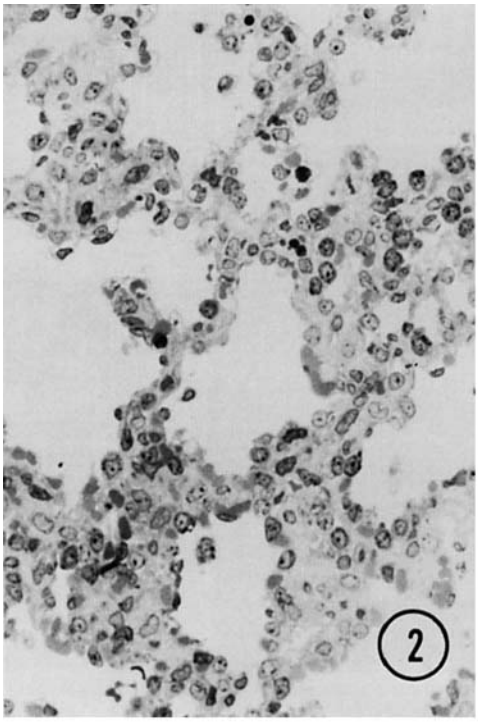
2

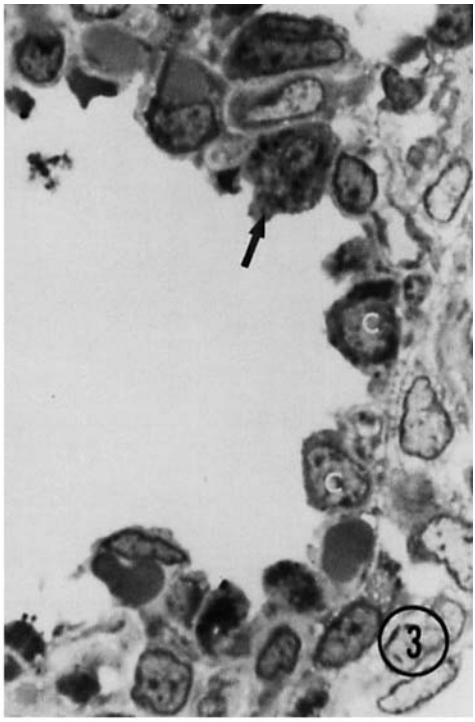
3

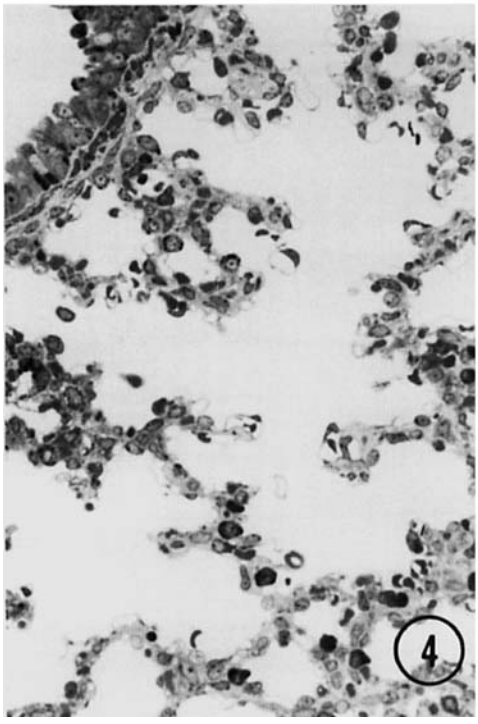
4

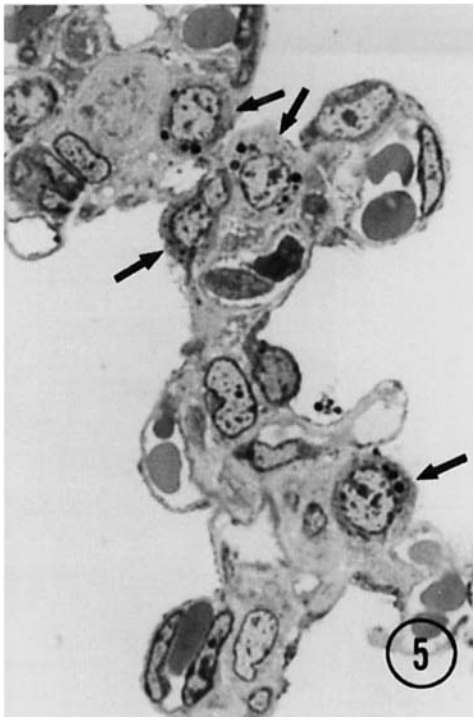
5

PLATE 2

EXPLANATION OF FIGURES

6 Type I alveolar epithelial cell from a 28-day control rabbit fetus. Nucleus (N) is surrounded by abundant cytoplasm containing much glycogen (G). Cell extension is thin on the right and forms blood-air barrier over capillary (C). On the left side the cell extension is thick, contains mitochondria (M) and rough endoplasmic reticulum (R) and overlies a capillary endothelial cell (E). × 14,000.

7 Type I cell of a 28-day pilocarpine-treated fetus. Nucleus (N) is surrounded by a thin rim of cytoplasm containing virtually no glycogen. Cell extensions are attenuated to form blood-air barriers over capillary lumens (C). Note surfactant material (S) in alveolar space. × 10,000.

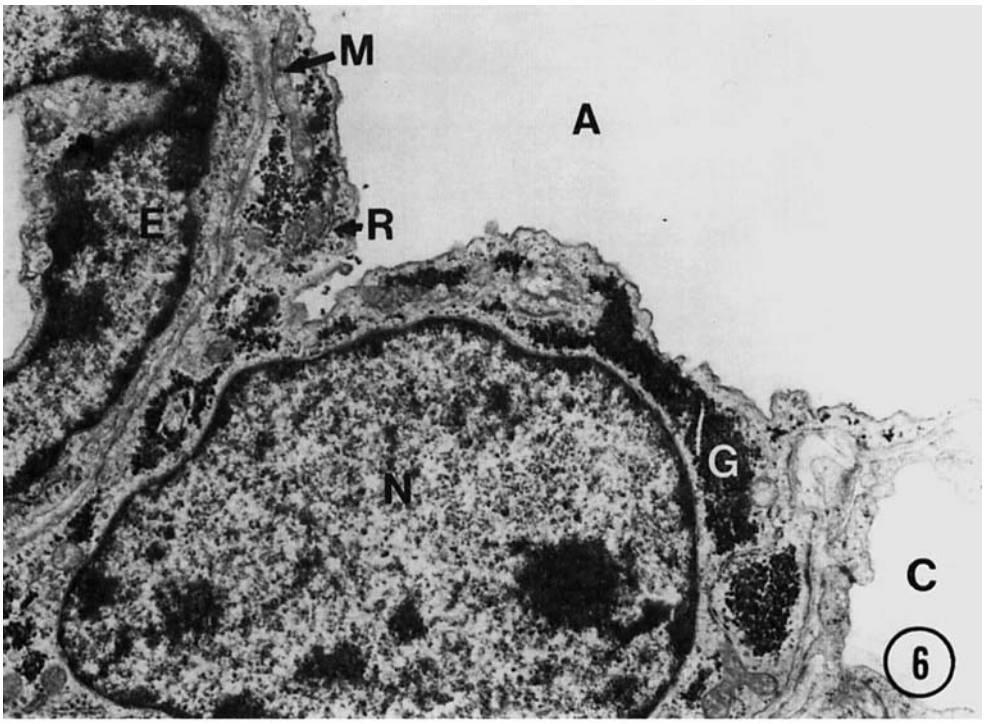
M
A
E
R
N
G
C
6

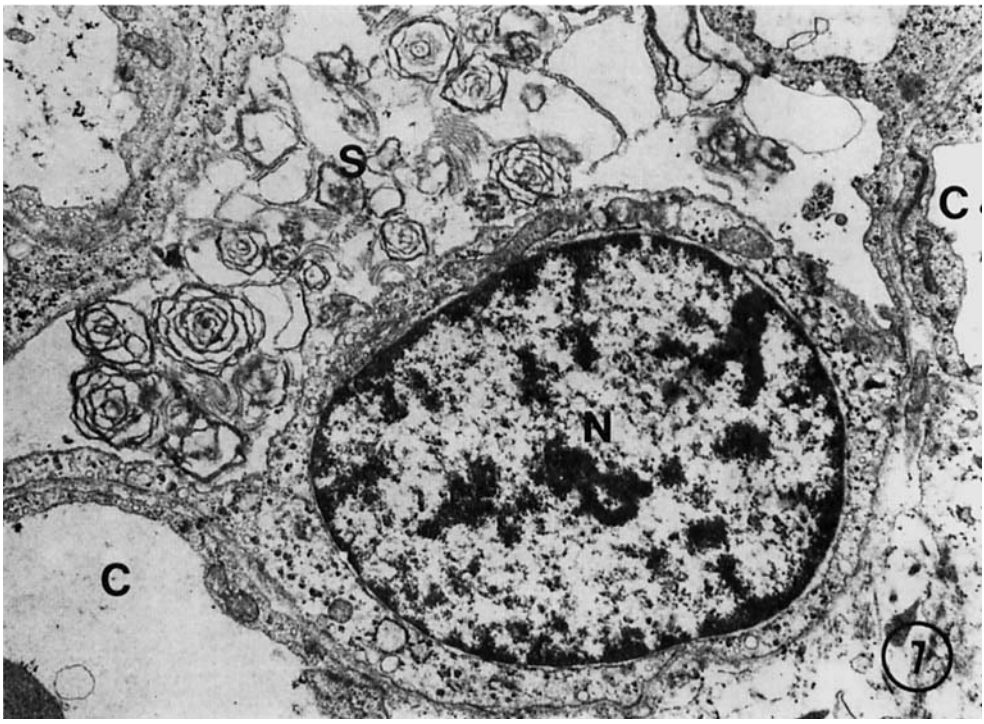
S
C
N
C
7

PLATE 3

EXPLANATION OF FIGURES

8 Type II cell of a 28-day control rabbit fetus. The cytoplasm contains abundant glycogen (G) and few lamellar inclusion bodies (L), usually containing sparse lamellae. A, alveolar space. × 13,000.

9 Type II cell of a 28-day pilocarpine-treated fetus. Glycogen is virtually absent while lamellar inclusion bodies (L) are numerous and show well developed, darkly stained lamellae. Notice lamellar body apparently in the process of being secreted (S) into alveolar space (A), as well as a multivesicular body (MV) and well developed cisternae of rough endoplasmic reticulum (R). × 10,500.

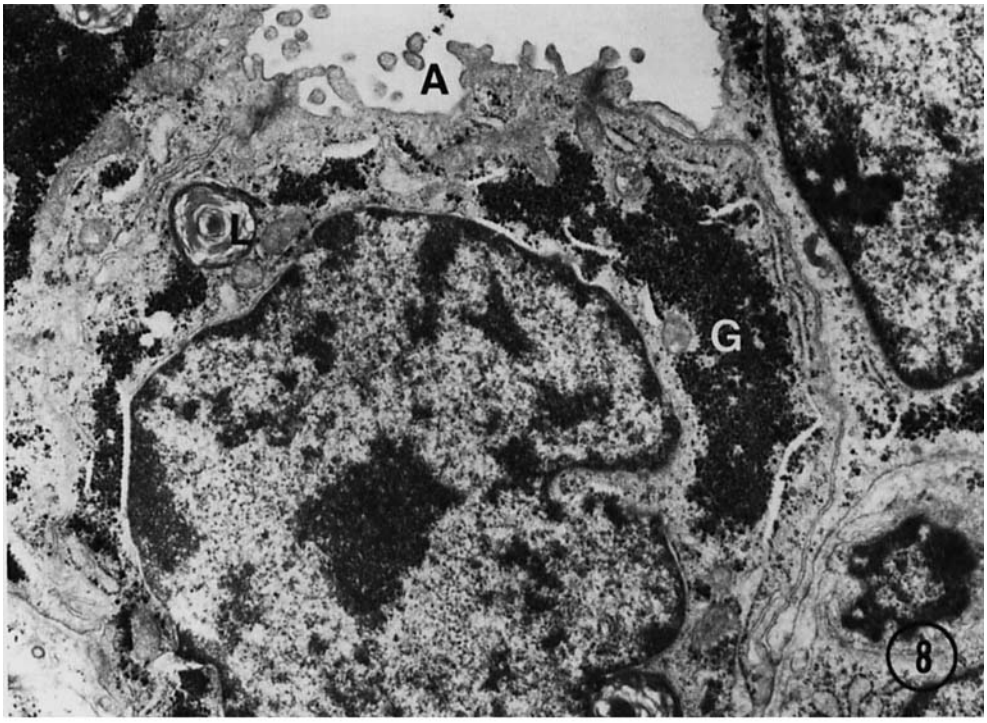
A
L
G
8

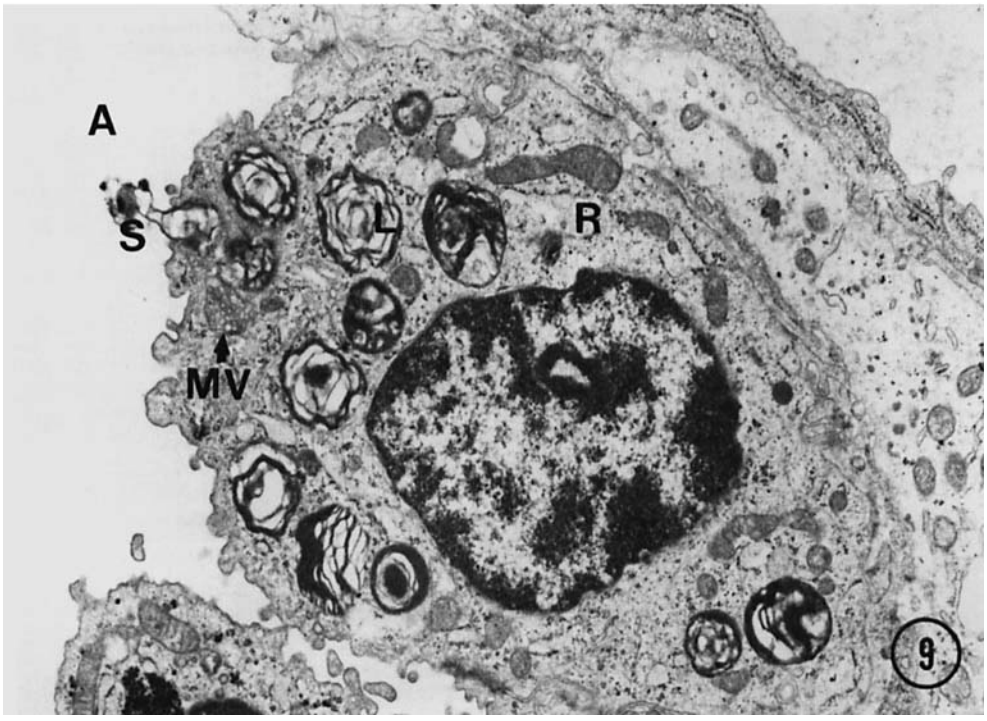
A
S
L
R
MV
9

PLATE 4

EXPLANATION OF FIGURES

10 Portion of a 28-day control type II cell. Note glycogen (G) and indistinct lamellae of inclusion body (L). M, mitochondrion; N, nucleus. × 30,000.

11 Portion of a type II cell from a pilocarpine-treated fetus. Glycogen (G), when present, is usually found in association with surfactant material (L). Note transitional form of inclusion body (T). M, mitochondrion. × 33,000.

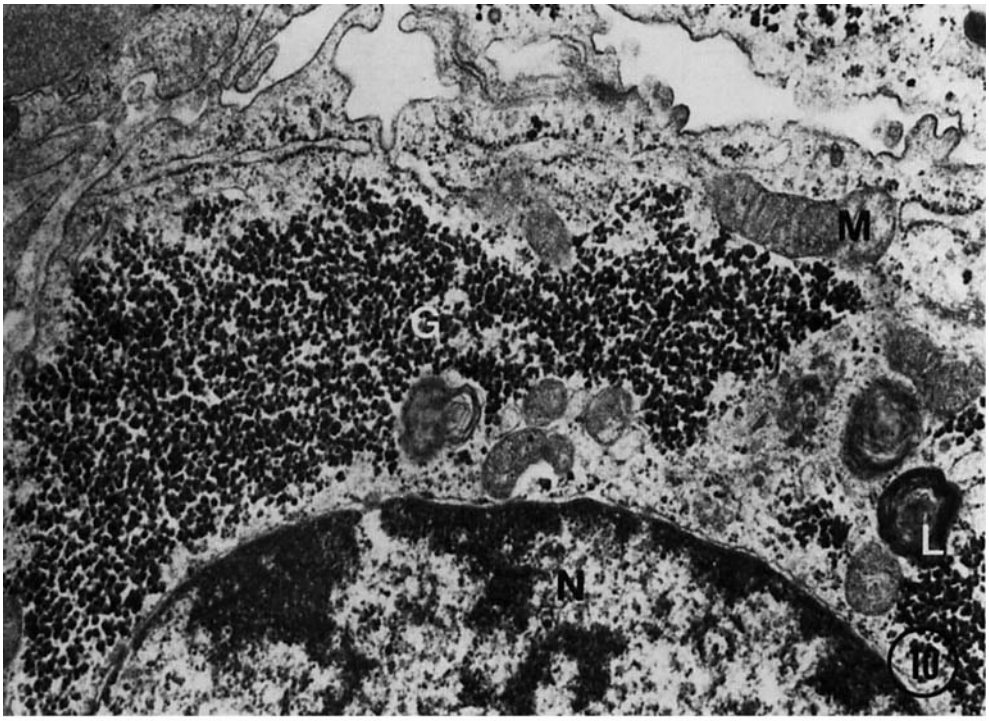
M
G
L
N
10

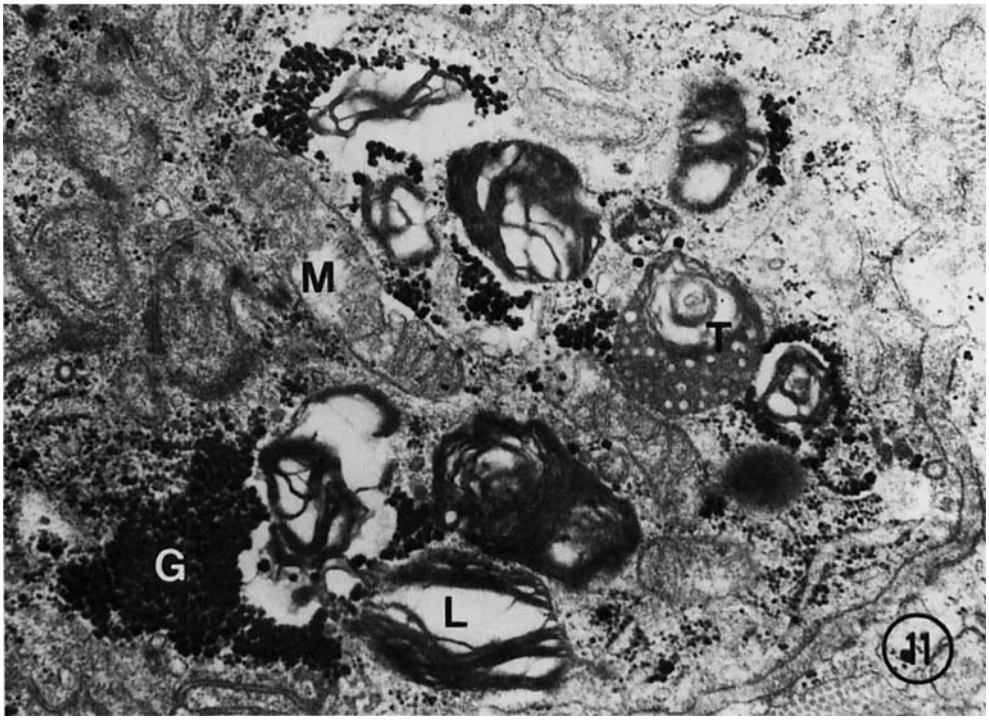
M
T
G
L
11