International Urology and Nephrology 26 (2), pp. 199–204 (1994)

Sclerotherapy of Hydroceles with Polidocanol

H. FUSE, M. SAKAMOTO, Y. FUJISHIRO, T. KATAYAMA

Department of Urology, Faculty of Medicine, Toyama Medical and Pharmaceutical University, Toyama, Japan

(Accepted June 12, 1993)

Fifteen patients with hydroceles of the testis or spermatic cord were treated by aspiration and injection of the sclerosant solution polidocanol. The cure rate of hydroceles after one sclerotherapy session was 73%, and the overall cure rate using the procedure was 87%. No patient experienced pain during or after the procedure, which was conducted without anaesthesia. No complications were observed. It is concluded that sclerotherapy of hydroceles with polidocanol may be a useful alternative to open operation, due to its ease of administration, low frequency of complications, and high rate of effectiveness, and that this agent is preferable to certain other drugs in that it causes no pain during or after the injection.

Introduction

Hydroceles of the testis are usually treated surgically, and the operation most often used is that described by Lord [11] and Winkelmann [19]. Although simple aspiration has also been used, it is usually followed by recurrence. Sclerotherapy was first performed in the thirteenth century, by injecting a solution of powder and ginger, but was largely abandoned thereafter, probably because of poor results. It has remained difficult to find an agent which is effective and has no side effects. The most commonly used sclerosants include phenol [15], sodium tetradecyl sulphate [4], tetracycline [3, 5, 9], and, recently, ethanolamine oleate [7]. The cure rates with these solutions vary from 28 to 100% [2, 3, 6, 7, 13–15].

Polidocanol has gained wide acceptance as a sclerosant in the treatment of oesophageal and lower extremity varices, for which only a few minor side effects have been reported [1]. These data motivated us to investigate its effect on hydroceles of the testis.

Patients and methods

The subjects were 15 patients with hydrocele, ranging in age from 30 to 78 years (mean age 50 years). Eight had hydrocele of the right testis and 6 of the left testis, and 1 had hydrocele of the right spermatic cord. Four patients had previous history of 2–4 hydrocele aspirations.

VSP, Utrecht
Akadémiai Kiadó, Budapest

The hydrocele was held with one hand and transilluminted so that an intravenous plastic cannula (18 gauge) could be inserted into the upper part of the sac through a visibly avascular area. Without local anaesthesia, the hydrocele was aspirated through the cannula. After the sac was completely emptied by squeezing the scrotum gently and aspirating all remaining fluid, the testis was carefully palpated to exclude any underlying pathology, and 2 ml of 3% polidocanol (Aethoxysclerol, Kreussler & Co. GmbH, Germany) was injected into the scrotum. In patients with a multilocular hydrocele confirmed by ultrasonography, all compartments were punctured and 2 ml of the agent was instilled into each compartment. The scrotum was gently massaged for 3 minutes in order to evenly distribute the agent within the cavity, and the patient was asked to wear a scrotal support for a few days. The procedure was performed on an ambulatory basis in all patients, who were discharged from the hospital after 2–3 hours of observation.

Scrotal ultrasonography was performed to examine the intrascrotal condition including the presence of the hydrocele before and after sclerotherapy. Cytological and bacteriological examinations of the aspirated fluid were performed to exclude tumour and inflammation, respectively.

In recurrence of the hydrocele occurred within one month after the sclerotherapy, only aspiration was performed, while sclerotherapy was performed for another recurrence.

Efficacy was evaluated one month after the sclerotherapy and every 3 months after the procedure thereafter.

Results

The size of the hydrocele ranged from 30 to 250 ml (mean size 110 ml). Patient 5 had a bilocular hydrocele, the size of which was 10 and 20 ml, respectively. The aspirated fluid was clear or straw-coloured in all hydroceles. The observation period after treatment ranged from 3 to 9 months. The effects of sclerotherapy are illustrated in Fig. 1. Scrotal ultrasonography 1 month after

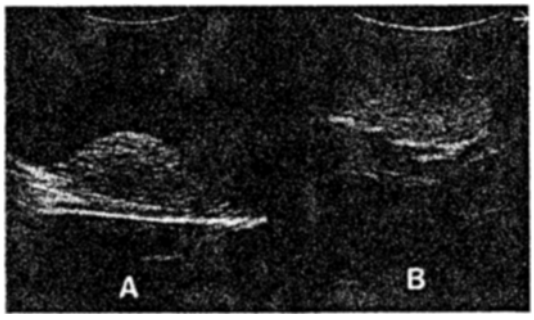

Fig. 1. Ultrasonogram before (A) and after (B) sclerotherapy

the treatment revealed recurrence in 6 of the 15 patients. Aspiration alone was performed in these 6 patients. Two months later, 4 of the 6 patients had recurrence again, and injection of the agent was performed. Two of these 4 patients were cured 6 months after the second injection, but the other 2 patients underwent operation for the hydrocele since the disease was not cured after 3 treatments. The hydrocele cure rate after one sclerotherapy session was 73% (11 patients), and the overall cure rate with the procedure was 87% (13) (Fig. 2).

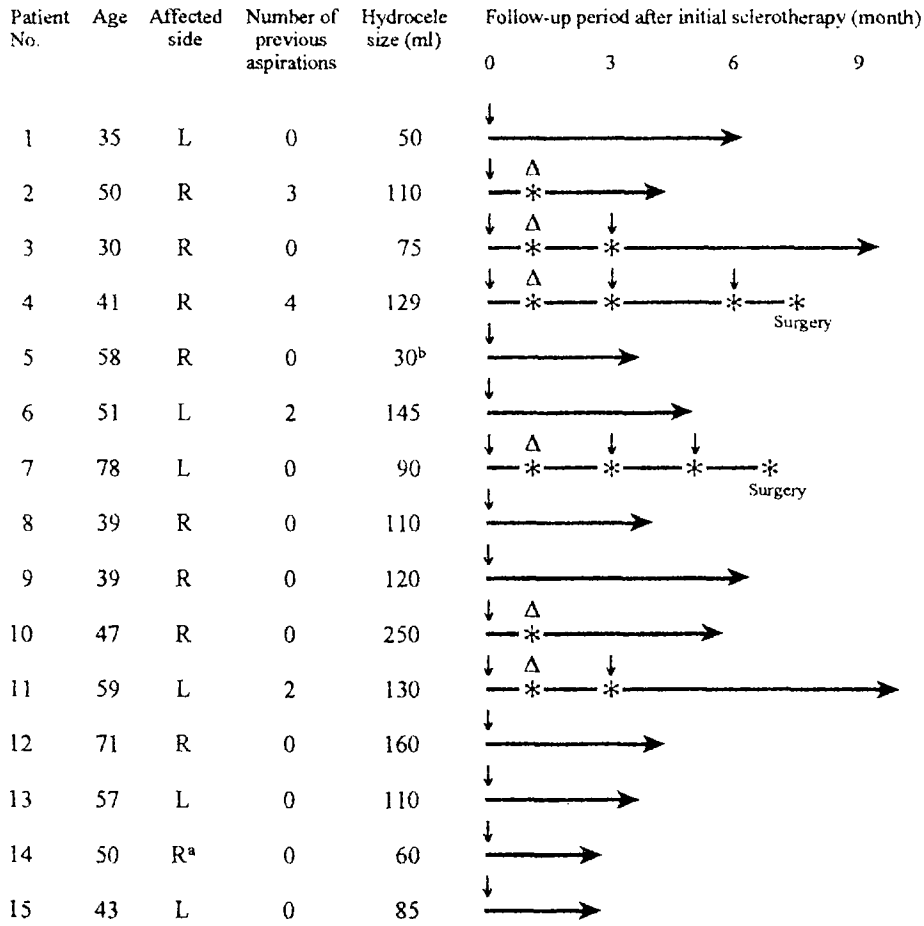

Fig. 2. Results of sclerotherapy

No patient experienced pain after aspiration and injection of the agent. A hard induration developed within the hydrocele sac in some patients, but this disappeared during the follow-up period. During the ultrasonographic follow-up period (up to 9 months), no change in the testicular tissue was observed, nor was any infection, oedema or haematoma observed after the procedure or during the follow-up period. There were no allergic reactions. The cytological and bacteriological findings for the aspirated fluid were normal in all patients.

Discussion

Operative treatment of hydroceles has a high cure rate, but is associated with a high incidence of major complications, including haematoma and infection. In contrast, techniques not involving excision of the sac are associated with fewer postoperative side effects [16]. Furthermore, sclerotherapy does not necessitate hospitalization, which makes it highly cost-effective.

Thompson and Odell [17] reported poor results after sclerotherapy with phenol and tetradecyl sulphate. However, Nash [15] obtained a 95% cure rate for hydroceles with phenol, and Macfarlane [13] a 100% cure rate with tetradecyl sulphate. Tetracycline has been used with variable results; Badenoch et al. [2] reported that only 33% of patients were cured after tetracycline injection, while Hu et al. [8] obtained a 96% cure rate. A two-component fibrin adhesive (Tisseel) has been used, but it is not recommended since recurrence apparently occurs in nearly all cases [10, 18]. Using polidocanol, Gasser et al. [6] found that the cumulative cure rate of hydroceles in 32 patients was 93% after 1 to 3 procedures. Lund and Bartolin [12] also reported 85% cure rate with this technique. These results are comparable to the present overall cure rate of 87%. Hu et al. [8] found that 80% of the patients experienced some pain after sclerotherapy using tetracycline; we, in a previous study [5], also found similar results. In contrast, Gasser et al. [6] found that polidocanol did not cause pain; in the present study, no patient complained of pain during or after the procedure, which was performed without anaesthesia.

Complications after sclerotherapy are few, although haematoma and epididymo-orchitis have been reported [13]. In the present study, no side effect was observed. Zimmerman et al. [20] reported that sodium tetradecyl sulphate has anti-fertility effects which are due to the binding of agents to the membrane of sperm. In our study, although the anti-fertility effects of polidocanol were not investigated, no ultrasonographically detectable changes were observed. Further studies, such as histological examination and semen analysis, are needed to clarify this side effect.

Moloney [14] stated that multilocular epididymal cysts may be treated by injection if there are only 2 or 3, but are on the whole best treated by surgery. In the present study, 1 patient with bilocular hydrocele was cured by the tech-

nique. Ultrasonography before treatment to evaluate the nature of the hydrocele is recommended. We emphasize the risk of malignancy as a cause of hydrocele, and cytological examination of the aspirate, scrotal ultrasonography, and thorough palpation of the testis after fluid aspiration should always be performed.

We conclude that polidocanol is an effective sclerosant for the treatment of hydroceles having minimal side effects and a low recurrence rate. However, at this time sclerotherapy is not recommended for males who plan to have children until its effects on testicular and epididymal function have been more fully elucidated.

References

1. Amblard, P.: Our experiences with Aethoxysclerol. *Phlebologie, 30,* 213 (1977).
2. Badenoch, D. F., Fowler, C. G., Jenkins, B. J., Roberts, J. V., Tiptaft, R. C.: Aspiration and instillation of tetracycline in the treatment of testicular hydrocele. *Br. J. Urol., 59,* 172 (1987).
3. Bodker, A., Sommer, W., Andersen, J. T., Kristensen, J. K.: Treatment of hydrocele of the testis with aspiration and injection of tetracycline. *Br. J. Urol., 57,* 192 (1985).
4. Byne, P. D., May, R. E.: Aspiration and injection treatment of hydroceles and epididymal cysts. *Br. J. Clin. Pract., 32,* 256 (1978).
5. Fuse, H., Nishikawa, Y., Shimazaki, J., Katayama, T.: Aspiration and tetracycline sclerotherapy of hydrocele. *Scand. J. Urol. Nephrol., 25,* 5 (1991).
6. Gasser, F., Kirkeby, H. J., Berg, V., Gasser, G.: Sclerotherapy of hydroceles and epididymal cysts with polidocanol (Aethoxysclerol). *Surg. Res. Comm., 7,* 183 (1990).
7. Hellström, P., Tammela, T., Kontturi, M., Lukkarinen, O.: Ethanolamine oleate as a sclerosant for testicular hydroceles and epididymal cysts. *Br. J. Urol., 62,* 445 (1988).
8. Hu, K.-N., Khan, A. S., Gonder, M.: Sclerotherapy with tetracycline solution for hydrocele. *Urology, 24,* 572 (1984).
9. Kaye, R.: Treatment of hydroceles by injection of sclerosing agents. *N. Engl. J. Med., 307,* 1149 (1982).
10. Larsen, T., Devantier, A., Iversen, E., Fischer, A., Hansen, R., Dragsted, J.: Treatment of testicular hydrocele with fibrin adhesive. *Ugeskr. Laeger, 148,* 896 (1986).
11. Lord, P. H.: A bloodless operation for the radical cure of idiopathic hydrocele. *Br. J. Surg., 51,* 914 (1964).
12. Lund, L., Bartolin, J.: Treatment of hydrocele testis with aspiration and injection of polidocanol. *J. Urol., 147,* 1065 (1992).
13. Macfarlane, J. R.: Sclerosant therapy for hydroceles and epididymal cysts. *Br. J. Urol., 55,* 81 (1983).
14. Moloney, G. E.: Comparison of results of treatment of hydrocele and epididymal cysts by surgery and injection. *Br. Med. J., 3,* 478 (1975).
15. Nash, J. R.: Sclerotherapy for hydroceles and epididymal cysts. *Br. J. Surg., 66,* 289 (1979).
16. Rodriquez, W. C., Rodriquez, D. D., Fortuno, R. F.: The operative treatment of hydrocele: A comparison of 4 basic techniques. *J. Urol., 125,* 804 (1981).
17. Thompson, H., Odell, M.: Sclerosant treatment for hydroceles and epididymal cysts. *Br. Med. J., 2,* 704 (1979).

18. Thorup, J., Schultz, A., Christiansen, L.: Treatment of hydrocele with puncture and injection of fibrin adhesive (Tisseel). *Ugeskr. Laeger, 148,* 1759 (1986).
19. Winkelmann, O.: Neue Methode der radikalen Operation der Hydrocele. *Zentralbl. Chir., 44,* 1092 (1898).
20. Zimmerman, R. E., Nevin, R. S., Allen, D. J., Jones, C. D., Goettel, M. E., Burck, P. J.: Antifertility effects of tetradecyl sodium sulphate in rabbits. *J. Reprod. Fertil., 68,* 257 (1983).