Knee Surg Sports Traumatol Arthrosc (2008) 16:803–805
DOI 10.1007/s00167-008-0555-5

WRIST

Neovascularisation in de Quervain's disease of the wrist: novel combined therapy using sclerosing therapy with polidocanol and eccentric training of the forearms and wrists—a pilot report

Karsten Knobloch · Andreas Gohritz · Marcus Spies · Peter M. Vogt

Received: 4 March 2008 / Accepted: 14 April 2008 / Published online: 31 May 2008

Abstract De Quervain's disease has been described as an entrapment of the extensor pollicis brevis and abductor pollicis tendons in the first dorsal compartment of the wrist is a common cause of wrist and hand pain. Currently, intrasheath corticosteroid injections have been reported to be successful as well as surgical release of the first dorsal compartment. We report on three female recreational athletes (median age 57 years, pain VAS 7/10) where we found significant neovascularisation of the extensor retinaculum using Power-Doppler sonography, which was not evident among subjects without de Quervain's disease of the wrist. Polidocanol sclerosing therapy (0.25% 1 ml) was performed with consecutive eccentric training (Thera-Band Flex-Bar, 6 × 15 repetitions of the forearm and wrist extensors and flexors daily). Four weeks later two patients had a resolution of their pain levels (DASH 61 vs. 27, $p < 0.05$) with resolution of the neovascularisation, while one patient underwent surgery despite pain reduction (6 to 2) 3 weeks following sclerosing therapy. Neovascularisation has been found in de Quervain's disease of the wrist using Power Doppler sonography. Combined treatment with Power Doppler controlled sclerosing therapy with consecutive eccentric training led to encouraging pilot results in terms of pain reduction and functional improvement within 1 month of therapy. A prospective randomized controlled trial is warranted to answer the question whether the sclerosing therapy, the eccentric training or the combination of both is beneficial in de Quervain's disease of the wrist.

K. Knobloch (✉) · A. Gohritz · M. Spies · P. M. Vogt
Plastic, Hand and Reconstructive Surgery,
Hannover Medical School, Carl-Neuberg-Str. 1,
30625 Hannover, Germany
e-mail: kknobi@yahoo.com

Keywords Tendon · Pain · Wrist · Sclerosing · Ultrasound

Introduction

Entrapment of the extensor pollicis brevis and abductor pollicis tendons in the first dorsal compartment of the wrist is a common cause of wrist and hand pain. Fritz de Quervain has been credited with the description in 1895. A similar entity has been reported in the 1893 edition of Gray's Anatomy named "washerwoman's sprain". Finkelstein [3] reported in 1930 the stenosing tendovaginitis of the wrist with local tenderness and swelling 1 to 2 cm proximal to the radial styloid and knifelike pain when the thumb is extended in the palm and the wrist is forced into ulnar deviation (Finkelstein's sign). Technetium bone scanning may show increased uptake in the distal radius deep to the first dorsal compartment with a focal area of superficial linear hyperaemia [6]. Enhanced magnetic resonance imaging has been suggested in tendinopathy of the hand and wrist [8].

Therapy involves both, conservative and operative options. Reasonable success rates with intra-sheath corticosteroid injections have been reported recently, however currently we do not have any randomized controlled trial regarding the use of corticosteroid injections for de Quervain' s disease [2, 7]. Furthermore, potential adverse effects of local injected corticosteroids to tendons are reported such as tendon ruptures. Given the strong published evidence of neovascularisation involved in tendinopathy such as at the Achilles tendon, the patellar tendon, the supraspinatus tendon or in tennis elbow, we thought to analyse de Quervain's disease of the wrist regarding potential neovascularisation. We introduced a

novel combined therapy involving sclerosing therapy using polidocanol and eccentric training to relieve pain.

We report on a total number of three females (median age 57 years) performing tennis as a recreational sport with tenderness and pain over the first dorsal compartment with mean visual analogue scale 7 out of 10 and median DASH score of 61. Finkelstein and Eickhoff signs were positive before therapy. Ultrasound revealed in all patients enlarged tendon diameter of the extensor pollicis brevis tendon (median 4.6 mm diameter) with peritendious fluid. Power Doppler sonography revealed significant neovascularisation (grade 2 to 3+) at the first dorsal compartment of the extensor retinaculum (Fig. 1a), where sclerosing therapy with 1 ml of 0.25% polidocanol was performed under Power Doppler control until the neovascularisation resolved in every patient (Fig. 1b). In contrast, subjects without de Quervain's disease of the wrist did not display any tendon enlargement, peritendinous fluid or any sign of neovascularisation in the vicinity of the first dorsal compartment of the wrist.

A compression dressing was applied for 24 h after sclerosing therapy with polidocanol. Furthermore, an eccentric training was initiated at the third day following sclerosing therapy with the Thera-Band Flex-Bar (green). In a standing position the patients had to perform forceful supination and pronation with straight forarms and elbows (holding each position for 2 s) with 6 × 15 repetitions each day (Fig. 2a, b). The first scheduled control examination was performed 4 weeks later. In two of the three females symptoms had reduced to VAS 1/10 with a DASH score reduction from 61 to 21 (female 1) and 71 to 34 (female 2) with a median neovascularisation score of 0.5. Female 3 did not follow the eccentric training programme and underwent open surgical release of the first dorsal compartment, although pain level had reduced from 6 to 2 within 3 weeks despite the fact she did perform the eccentric training for 1 week only. After 12 weeks of eccentric training, the two patients were pain free with DASH scores of 14 at median. The females were back on the tennis court by 6 weeks after the injection with pain level on exertion of VAS 1/10.

Neovascularisation has been found in de Quervain's disease of the wrist using Power Doppler sonography in contrast to healthy subjects. Combined treatment with Power Doppler controlled sclerosing therapy using polidocanol with consecutive eccentric training led to encouraging results in terms of pain reduction and functional improvement within 1 month of therapy. These results at the wrist level can be interpreted in line with the published results of sclerosing therapy using polidocanol

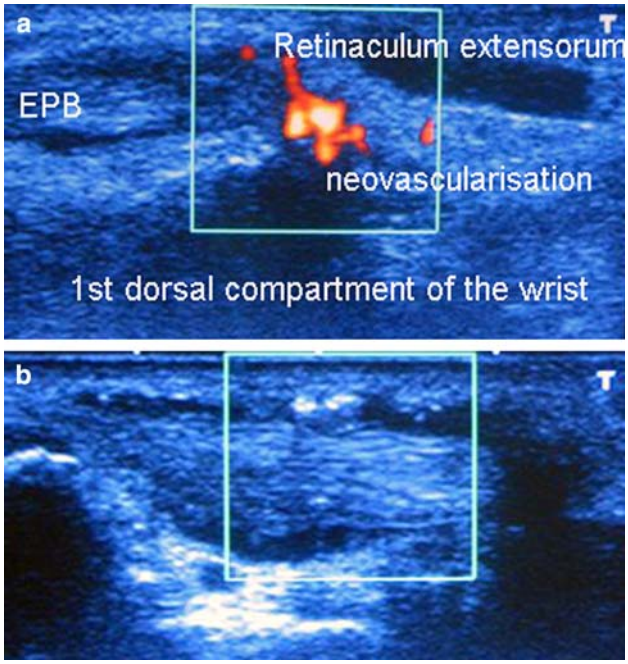

Fig. 1 **a** Neovascularisation of the first dorsal compartment in de Quervain's disease of the wrist identified with Power–Doppler sonography with peritendinous fluid around the enlarged tendon of the extensor pollicis brevis tendon. **b** Extensor pollicis brevis tendon immediately after sclerosing therapy with polidocanol under strict guidance of the Power–Doppler until the flow resolved



Fig. 2 Eccentric training using the Thera-Band Flex-Bar with straight arms daily over 12 weeks

in Achilles tendinopathy [5], shoulder impingement syndrome [1], and tennis elbow and flexor tendinopathy at the wrist [4]. We thought to combine the sclerosing therapy as a measure to pain reduction with early painful eccentric training for the forearm and wrist for a structural change of the tendons. Surprisingly, at week four, two patients did not report of any significant pain. In line neovascularisation was reduced from a median of 2.5 to 0.5 with no further second polidocanol injection due to the low pain level. However, these pilot results cannot be interpreted as the final answer in this regard.

Limitations

This case series is a pilot report on sclerosing therapy at the wrist level. Larger prospective controlled randomized trials are necessary to elucidate the value of sclerosing therapy using polidocanol, eccentric training of the forearms and wrist or the combination of both. Furthermore, prospective randomized trials might study the effects of the aforementioned strategy in contrast to open surgical release. Currently it seems that sclerosing therapy with 0.25% polidocanol is reasonable safe, however one has to care for potential allergic reactions as well as vascular compromise in the neighbourhood of the injection side. Second, one has to control for potential nerve disturbances of the superficial branch of the radial nerve, which we did not encounter in our pilot case series.

In conclusion, neovascularisation has been found in de Quervain's disease of the wrist using Power Doppler sonography. Combined treatment with Power Doppler controlled sclerosing therapy with consecutive eccentric training led to encouraging pilot results in terms of pain reduction and functional improvement within 1 month of therapy. A prospective randomized controlled trial is warranted to answer the question whether the sclerosing therapy, the eccentric training or the combination of both is beneficial in de Quervain's disease of the wrist.

References

1. Alfredson H, Harstad H, Haugen S, Ohberg L (2006) Sclerosing polidocanol injections to treat chronic painful shoulder impingement syndroms—results of a two-centre collaborative pilot study. Knee Surg Sports Traumatol Arthrosc 14:1321–1326
2. Alvarez-Nemegyei J, Canoso JJ (2004) Evidence-based soft tissue rheumatology: epicondylitis and hand stenosing tendinopathy. J Clin Rheumatol 10:33–40
3. Finkelstein H (1930) Stenosing tendovaginitis at the radial styloid procress. J Bone Joint Surg Am 12:509–540
4. Knobloch K, Spies M, Busch KH, Vogt PM (2007) Sclerosing therapy and eccentric training in flexor carpi ulnaris tendinopathy in a tennis player. Br J Sports Med May 31 (Epub ahead of print)
5. Lind B, Ohberg L, Alfredson H (2006) Sclerosing polidocanol injections in mid-portion Achilles tendinosis: remaining good clinical results and decreased tendon thickness at 2-year follow-up. Knee Surg Traumatol Arthrosc 14:1327–1332
6. Leslie WD (2006) The scintigraphic appearance of de Quervain tenosynovitis. Clin Nucl Med 31:602–604
7. Sawaizumi T, Nanno M, Ito H (2007) De Quervain's disease: efficacy of intra-sheath triamcinolone injection. Int Orthop 31:265–268
8. Tehranzadeh J, Ashikyan O, Anavim A, Tramma S (2006) Enhanced MR imaging of tenosynovitis of hand and wrist in inflammatory arthritis. Skeletal Radiol 35:814–822
9. Zeisig E, Ohberg L, Alfredson H (2006) Sclerosing polidocanol injections in chronic painful tennis elbow–promising results in a pilot study. Knee Surg Sports Traumatol Arthrosc 14:1218–1224