JOURNAL OF PATHOLOGY, VOL. **182:** 356–361 (1997)

METASTATIC LESIONS FROM PROSTATE CANCER DO NOT EXPRESS OESTROGEN AND PROGESTERONE RECEPTORS

ALFRED HOBISCH[1], ANTON HITTMAIR[2], GÜNTER DAXENBICHLER[3], STEFAN WILLE[1], CHRISTIAN RADMAYR[1], PETRA HOBISCH-HAGEN[4], GEORG BARTSCH[1], HELMUT KLOCKER[1] AND ZORAN CULIG[1]*

[1]*Department of Urology, University of Innsbruck, Austria*
[2]*Department of Pathology, University of Innsbruck, Austria*
[3]*Department of Gynecology and Obstetrics, University of Innsbruck, Austria*
[4]*Department of Anaesthesia and Intensive Care Medicine, University of Innsbruck, Austria*

SUMMARY

Oestrogen receptors (ER) and progesterone receptors (PR) have been reported by several authors in the stromal cells of the human prostate. Controversial results exist on the expression of ER and PR in epithelial cells of the prostate. Some recent publications, in contrast to previous findings, have suggested that these receptors are also present in human prostate cancer cell lines derived from metastatic lesions. The expression of ER and PR in these cell lines has been re-examined to determine their presence in lymph node metastases from patients who did not receive any kind of endocrine therapy and in distant metastases obtained from patients who failed endocrine treatment. ER and PR expression in LNCaP, PC-3, and DU-145 cells was assessed by means of the reverse transcriptase-polymerase chain reaction, ligand binding assays, and immunohistochemistry. With all the techniques applied, the three cell lines were found to be negative for both ER and PR. Immunohistochemical analyses were performed in four lymph node metastases obtained at radical prostatectomy from patients who did not receive endocrine therapy and in 17 distant metastases obtained at palliative surgery from patients who failed endocrine therapy. All 21 metastases were negative for ER and PR on immunohistochemistry. These results do not support the recently developed concept that receptors for oestrogenic and progestagenic steroids are present in metastases from human prostate cancer. © 1997 by John Wiley & Sons, Ltd.

J. Pathol. 182: 356–361, 1997.
No. of Figures 2. No of Tables 2. No. of References 39.

KEY WORDS—**prostatic carcinoma; cell lines; metastatic specimens; oestrogen receptor; progesterone receptor; androgen receptor; endocrine therapy; tumour progression**

INTRODUCTION

Oestrogen receptor (ER) and progesterone receptor (PR) are members of a superfamily of ligand-induced nuclear transcription factors. They differ in their hormone-responsive element specificity: the ER recognizes the sequence GGTCA nnn TGACC and the PR targets the glucocorticoid response element. The functional role of oestrogenic and progestagenic steroids in the prostate is not well understood. This is largely due to controversial results regarding the presence of their respective receptors in prostatic tissue.

Early studies on ER and PR in prostatic tissue were performed almost exclusively by means of binding assays.[1,2] This technique does not allow intraprostatic cellular localization of steroid receptors.[3] Elucidation of the cDNA sequence of the ER and PR has rendered possible the generation of specific antibodies directed against these receptors.[4,5] In rhesus monkey prostate, stromal fibroblasts and smooth muscle cells were found to stain for the ER, whereas there was no staining in the glandular epithelium.[6,7] Several immunohistochemical studies have revealed stromal localization of these receptors in the normal human prostate and in benign prostatic hyperplasia.[8–10] Few or no ER and PR were detected in malignant prostatic epithelium. ER and PR were not found in the prostate cancer cell line LNCaP by the groups of Berns, Sonnenschein, and Brolin.[11–13] Nevertheless, proliferation of these cells is stimulated by oestrogenic and progestagenic steroids. This seems to be due to the mutant LNCaP androgen receptor (AR) which has an increased binding affinity for oestradiol and various progestins and is activated by these steroids.[14] In contrast to the studies mentioned above, Castagnetta and co-workers have recently reported the presence of ER mRNA and protein in LNCaP and PC-3 cells when assessed by means of the reverse transcriptase-polymerase chain reaction (RT-PCR), radioligand binding assays, and immunocytochemical analyses.[15,16] These authors also found positive staining for PR in LNCaP cells.[15]

There is increasing evidence that both the ER and the PR are also functionally activated by several growth factors and cellular regulators.[17–19] If the ER and the PR

*Correspondence to: Zoran Culig, MD, Research Laboratory, Department of Urology, University of Innsbruck, Anichstrasse 35, A-6020 Innsbruck, Austria.
Contract grant sponsor: Austrian Research Foundation; Contract grant number: SFB 002-Project F203.

CCC 0022–3417/97/070356–06 $17.50

Received 18 September 1996
Accepted 19 December 1996

are present in metastatic lesions from prostate cancer, this type of activation may be important for regulation of the growth of prostate cancer cells. All three human prostatic tumour cell lines were derived from metastatic lesions.[20–22] We have therefore decided to re-evaluate ER and PR expression in prostate cancer cell lines and to investigate whether these receptors are present in metastatic samples obtained from patients who did not receive therapy and from those who failed endocrine therapy.

MATERIALS AND METHODS

Cell lines

LNCaP (passages 44–49 and 21–23), PC-3; (passages 51–55 and 19–21), and DU-145 (passages 74–78) prostate cancer cells were purchased from the American Type Culture Collection (Rockville, MD, U.S.A.). ZR 75-1 and MCF-7 cells were kindly provided by Dr C. Marth, Department of Gynecology and Obstetrics, University of Innsbruck. Foreskin and skin fibroblasts from patients with partial androgen insensitivity are routinely cultured in our laboratory. The tumour cells were routinely maintained in RPMI-1640 medium containing 5 per cent fetal calf serum and antibiotics (penicillin/streptomycin, Gibco-BRL, Paisley, U.K.). A subline of LNCaP cells was cultured in RPMI-1640 medium supplemented with charcoal–dextran-treated fetal calf serum over 16 months. In a separate experiment, prostate cancer cells were cultured in phenol red-free RPMI-1640 medium (Biological Industries, Kibbutz Beit Haemek, Israel) 2 weeks before receptor assessment.

Metastatic specimens

Twenty-one specimens of metastatic lesions were obtained from 19 prostate cancer patients. The metastatic lesions were localized in lymph nodes (4 cases), bone (12 cases), periosteum (1 case), and the epidural space (4 cases). The lymph node metastases were obtained at radical prostatectomy from patients who did not receive any kind of endocrine therapy prior to surgery. The specimens from distant metastases were obtained at palliative surgery. Although these patients did receive some kind of endocrine therapy prior to surgery, they had all failed therapy by the time the specimens were taken. Samples derived from metastatic lesions from human breast cancer served as a positive control.

The bone metastases from prostate and breast cancer specimens were fixed in 10 per cent formalin, decalcified by 3-chloro-acetic acid, embedded in paraffin, cut at 5 μm thickness, and stained with haematoxylin and eosin. The tumours were graded according to WHO recommendations.[23]

Polymerase chain reaction (PCR) for ER and PR fragments

Cells were grown to near-confluence in 175 cm^2 flasks. They were washed once in phosphate-buffered saline (PBS) and harvested with trypsin–EDTA. The cell pellets were immediately frozen at -80°C. RNA isolation and cDNA synthesis were performed as described before.[24] The ER cDNA fragments were synthesized with the primers GGACCATATCCACCGAGTCCTG (nucleotides 1648–1669, sense) and GCCTCCCCCGTGATGTAATAC (nucleotides 1995–1975, antisense). The PR cDNA fragments were amplified with the oligonucleotides CTTTAAGAGGGCAATGGAAGG (nucleotides 1770–1790, sense) and GACTTCGTAGCCCTTCCAAAG (nucleotides 2512–2492, antisense). The house-keeping glyceraldehyde-3 phosphate dehydrogenase (GAPDH) fragment was amplified as an internal control. Each of the fragments was amplified by a 30-cycle PCR.

Binding assays

The ER and the PR contents in prostate cancer cell lines were determined by binding assays. The pellets were prepared as described above and stored at -80°C until use. The binding assays were carried out according to the recommendations of the European Organization for Research and Treatment of Cancer (EORTC) Receptor and Biomarker Study Group.[25,26] Aliquots of cytosol were incubated with increasing concentrations of either [^{3}H]-oestradiol or the synthetic progestin [^{3}H]-ORG 2058, either alone or in the presence of a 200-fold excess of diethylstilboestrol or ORG 2058 to correct for non-specific binding. Separation of bound and free ligand was realized by dextran-coated charcoal.

Antibodies

The monoclonal anti-ER antibody 1D5 was purchased from DAKO (Glostrup, Denmark). The monoclonal antibody 1A6 used for PR immunostaining was from YLEM (Rome, Italy). In addition, commercially available Abbott kits were used for ER and PR immunohistochemistry in cell lines and applied according to the manufacturer's instructions. Alternatively, the slides were incubated with the primary antibody for 24 h.

Immunohistochemistry

For immunohistochemistry analyses, the confluent prostate and breast cancer cell lines were trypsinized, cytospun, resuspended in PBS, fixed in 1 per cent paraformaldehyde, permeabilized by adding 0·1 per cent Triton X-100, and stained for ER and PR expression.

The tissue sections were deparaffinized in xylene and rehydrated in a series of alcohol solutions. After microwave irradiation in citrate buffer, endogenous peroxidase was blocked with sodium azide, glucose, and glucose-oxidase (reagents from Sigma, Deisenhofen, Germany).

ER and PR staining was performed according to a streptavidin–biotin–peroxidase protocol. The monoclonal antibodies were applied to the tissue sections at room temperature for 60 min. After two washes in PBS, the biotinylated secondary antibody was applied for

Table I—Expression of the oestrogen receptor in prostate and breast tumour cell lines and in patient material

Material	Method		
	Immunohisto-chemistry	Binding assay (fmol/mg protein)	PCR
Prostate cancer			
LNCaP cells	−	<3	−
PC-3 cells	−	<3	−
DU-145 cells	−	<3	−
Lymph node metastases	−	n.d.	n.d.
Distant metastases	−	n.d.	n.d.
Breast cancer			
MCF-7 cells	+ + +	182	+
ZR 75-1 cells	+ + +	118	+
Distant metastases	+[a]	n.d.	n.d.

n.d. = not determined.

Immunohistochemical staining: − = no staining; + + + = >50 per cent of cells positive; +[a] = variable percentage of positive cells in breast cancer metastases.

30 min, followed by peroxidase-labelled streptavidin for another 30 min. The enzymatic reaction was developed in a freshly prepared solution of diaminobenzidine (0·5 mg/ml; Sigma) and 0·01 per cent H_2O_2 for 5 min. The sections were then counterstained with haemalum, dehydrated, cleared in xylene, and mounted with Entellan (Merck, Darmstadt, Germany).

Semiquantitative evaluation of ER and PR staining was performed on the basis of a 4-point scale (−, no staining; +, <10 per cent of cells positive; + +, 10–50 per cent of cells positive; and + + +, >50 per cent of cells positive).

RESULTS

ER and PR cDNA fragments

The expression of ER and PR mRNA was studied in cell lines derived from prostate and breast cancers. ER and PR cDNA fragments were detected in the breast cancer cells MCF-7 and ZR 75-1 and in foreskin and skin fibroblasts, but they could not be amplified either from the prostate cancer cell lines LNCaP, PC-3 and DU-145, or from LNCaP cells which had been exposed to androgen withdrawal conditions by culturing in steroid-depleted medium over 16 months (Tables I and II and Fig. 1). The PCR was performed with three different cDNA preparations, all of which yielded the same results. GAPDH cDNA fragments, which served as internal controls, were isolated from all tumour cell lines and fibroblasts.

Binding assays

We investigated the three human prostate cancer cell lines for the presence of oestrogen and progesterone binding sites in two different experiments. In the first experiment, the ER and PR contents were measured after culturing the cells in standard RPMI medium. RPMI, however, contains phenol red, which has oestrogenic properties; we therefore maintained the cells in phenol red-free RPMI medium for 2 weeks, after which the binding assays were repeated.[27] Both experiments revealed that specific binding for ER and PR was lower than 3 fmol/mg of protein in all three cell lines (Tables I and II).

Immunohistochemistry

In the breast cancer cell lines, intensive nuclear staining for both the ER and the PR was achieved. In the three prostate cancer cell lines, no ER or PR staining was detected at all. The use of the commercial Abbott ER and PR immunohistochemical assays or cells in earlier passages, and prolonged incubation with the primary antibody (24 h), did not yield any positivity in the LNCaP cells; nor did the androgen-depleted LNCaP cells display any positivity for ER and PR (Tables I and II).

The absence of ER and PR immunopositivity in these cell lines does not necessarily mean that these receptors are not contained in metastatic specimens. We therefore studied the expression of these receptors *in vivo*. On immunohistochemical analysis, neither ER nor PR staining was detectable in four lymph node samples obtained from untreated patients, nor in 17 distant metastases from patients in whom endocrine therapy had failed. There was also no ER or PR staining in tumour-adjacent tissue (Tables I and II). Metastatic specimens derived from human breast cancer stained for ER (Fig. 2) and PR, demonstrating that the processing of samples derived from metastases does not yield artificially negative results.

Table II—Expression of the progesterone receptor in prostate and breast tumour cell lines and in patient material

Material	Method		
	Immunohisto-chemistry	Binding assay (fmol/mg protein)	PCR
Prostate cancer			
LNCaP cells	−	<3	−
PC-3 cells	−	<3	−
DU-145 cells	−	<3	−
Lymph node metastases	−	n.d.	n.d.
Distant metastases	−	n.d.	n.d.
Breast cancer			
MCF-7 cells	+ + +	1227	+
ZR 75-1 cells	+ + +	2685	+
Distant metastases	+[a]	n.d.	n.d.

n.d. = not determined.

Immunohistochemical staining: − = no staining; + + + = >50% of cells positive; +[a] = variable percentage of positive cells in breast cancer metastases.

DISCUSSION

The present study clearly demonstrates that none of the three human prostate carcinoma cell lines examined expresses ER or PR. These findings were obtained by means of the PCR, radioligand binding assays, and immunohistochemistry and are in line with previous work.[11–13] Berns *et al.* reported that these receptors are not detectable in the nuclear extracts and cytosol of LNCaP cells incubated with [^{3}H]-oestradiol or the synthetic progestin [^{3}H]-R5020,[11] nor were Sonnenschein *et al.*, who performed both binding assays and immunohistochemical analysis, able to detect ER.[12]

Our results do not support the concept put forward by Castagnetta *et al.* that in advanced prostate cancer, the action of oestradiol and progesterone is mediated by their respective receptors. According to these authors, the level of ER expression in the cytosol of LNCaP cells was about 50 fmol/mg of protein, only slightly lower than that of MCF-7 and ZR 75-1 breast cancer cell lines.[15] Significantly lower amounts of ER were expressed in PC-3 cells, in which, contrary to LNCaP

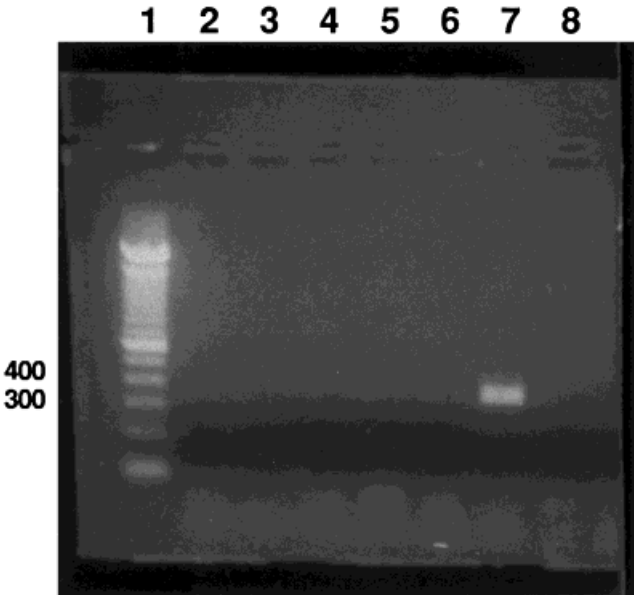

Fig. 1—ER cDNA fragments amplified by RT-PCR. An amplification of the 347 bp ER fragment was attempted in 30 PCR cycles from fibroblasts and prostate cancer cell lines. Aliquots of the samples were electrophoresed in 2 per cent agarose gel and the fragments were visualized by ethidium bromide staining and ultraviolet fluorescence. Lane 1: DNA size markers; lane 2: LNCaP cells; lane 3: PC-3 cells; lane 4: DU-145 cells; lanes 5 and 6: foreskin fibroblasts; lane 7: skin fibroblasts; lane 8: negative control

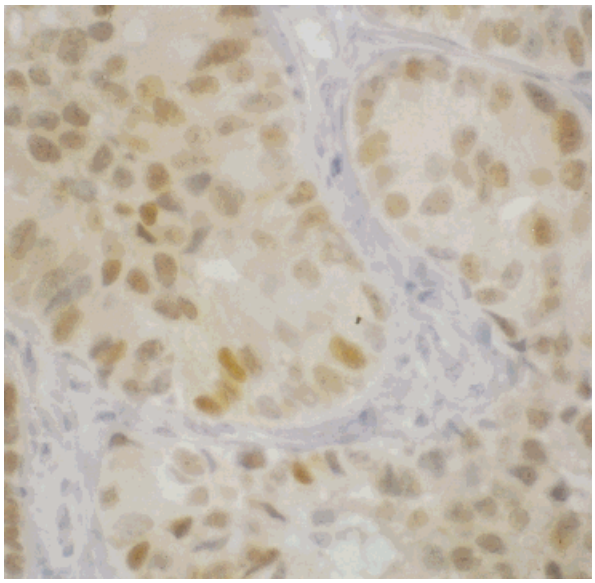

Fig. 2—ER-positive cells in a distant metastasis from breast cancer (×400). Paraffin-embedded sections fixed in formalin were stained with the monoclonal antibody 1D5 as described in the Materials and Methods section

cells, oestradiol displayed a growth-inhibitory effect.[16] Furthermore, our findings on immunohistochemistry are not in agreement with those of Castagnetta *et al.* who were able to visualize ER and PR after incubation with respective antibodies for 24 h.[15] In our experiments, the cells were invariably negative for ER and PR, regardless of the time they had been exposed to the primary antibody. In the studies by Castagnetta's group, LNCaP cells in passage 19 and PC-3 cells in passage 17 were used. In our study, we used routinely passage 44 of LNCaP and 51 of PC-3 cells. To be certain that continuous passaging of cells in the culture did not down-regulate the steroid receptor content, we obtained earlier passages of LNCaP and PC-3 cells and performed receptor determination again. Nevertheless, ER and PR were not detected. Thus, LNCaP cells express only AR among receptors for sex hormones.[24] Discrepancies also exist regarding ER expression in DU-145 cells, which were found to be negative for ER in both Brolin *et al.*'s and our study.[13] In a recent publication by Viljoen *et al.*, the existence of ER in DU-145 cells was postulated on the basis of results obtained by means of whole cell binding assays,[28] but the authors did not attempt additional techniques to verify the presence of the ER mRNA and/or protein in the DU-145 cell line.

In the present study, all 21 metastases obtained from prostate cancer patients were absolutely negative for both ER and PR. In a previous study, lymph node metastases obtained from patients undergoing pelvic lymphadenectomy prior to radical prostatectomy were also found to contain no ER or PR.[13] The data obtained in the present study confirm these results and, in addition, provide the first evidence that distant metastases from patients who have failed endocrine therapy do not express receptors for oestrogenic and progestagenic steroids. Interestingly enough, the presence of AR in lymph node, bone, and epidural metastases from prostate cancer has recently been documented.[29–31] It may be important to know that the activity of androgen receptors, which are expressed in prostate cancer metastases, is regulated by non-steroidal factors[32,33] in addition to androgens.

Furthermore, our study also indicates that during prostate carcinogenesis, there is no intercompartmental shift in expression of receptors for oestrogenic and progestagenic steroids.[8,34] There is increasing evidence suggesting that in the embryonal and the adult prostate, the stromal cells are targets for these steroids. In the adult human prostate, the ER is predominantly localized in the periglandular zone.[8]

Immunohistochemical analysis and *in situ* hybridization have shown that endocrine therapy for benign prostatic hyperplasia and prostate cancer apparently leads to an increase in ER and PR content in the prostatic stroma.[35–37] This phenomenon is confined to stromal cells; metastatic lesions obtained from patients previously subjected to endocrine therapy do not express ER or PR.

In conclusion, this study has provided convincing data that prostate cancer metastases, even those obtained during tumour progression, lack ER and PR. However, these steroids at higher concentrations were shown to stimulate AR activity.[38] Together with recent work on AR expression and structure in advanced prostate cancer (for review see ref. 39), this study should contribute to a better understanding of signal transduction in therapy-resistant carcinoma of the prostate.

ACKNOWLEDGEMENTS

This work was supported by grant SFB 002-Project F203 from the Austrian Research Foundation. We appreciate the expert technical assistance of I. Tschörner, E. Perkmann, T. Sierek, R. Höllinger, and E. Tafatsch, and thank Dr C. Marth for providing the breast cancer cell lines used in this study.

REFERENCES

1. Ekman P, Barrack ER, Greene GL, Jensen EV, Walsh PC. Estrogen receptors in human prostate: evidence for multiple binding sites. *J Clin Endocrinol Metab* 1983; **54:** 166–176.
2. Wolf RM, Schneider SL, Edson Pontes J, *et al.* Estrogen and progestin receptors in human prostatic carcinoma. *Cancer* 1985; **55:** 2477–2481.
3. Brolin J, Ekman P. Microassays for androgen and progesterone receptor quantitation as compared with standard saturation analyses in human prostatic tissues. *Urol Res* 1991; **19:** 333–336.
4. Green S, Walter P, Kumar V, *et al.* Human oestrogen receptor cDNA: sequence, expression and homology to v-erb-A. *Nature* 1986; **320:** 134–139.
5. Misrahi M, Atger M, d'Auriol L, *et al.* Complete amino acid sequence of the human progesterone receptor deduced from cloned cDNA. *Biochem Biophys Res Commun* 1987; **143:** 740–748.
6. West NB, Roselli CE, Resko JA, Greene GL, Brenner RM. Estrogen and progestin receptors and aromatase activity in rhesus monkey prostate. *Endocrinology* 1988; **123:** 2312–2322.
7. Brenner RM, West NB, McClellan MC. Estrogen and progestin receptors in the reproductive tract of male and female primates. *Biol Reprod* 1990; **42:** 11–19.
8. Wernert N, Gerdes J, Loy V, Seitz G, Scherr O, Dhom G. Investigations of the estrogen (ER-ICA-test) and the progesterone receptor in the prostate and prostatic carcinoma on immunohistochemical basis. *Virchows Arch A [Pathol Anat Histopathol]* 1987; **412:** 387–391.
9. Schulze H, Claus S. Histological localization of estrogen receptors in normal and diseased human prostates by immunocytochemistry. *Prostate* 1990; **16:** 331–343.
10. Mobbs BG, Liu Y. Immunohistochemical localization of progesterone receptor in benign and malignant human prostate. *Prostate* 1990; **16:** 245–251.
11. Berns EMJJ, de Boer W, Mulder E. Androgen-dependent growth regulation of and release of specific protein(s) by the androgen receptor containing human prostate tumor cell line LNCaP. *Prostate* 1986; **9:** 247–259.
12. Sonnenschein C, Olea N, Pasanen ME, Soto AM. Negative controls of cell proliferation: human prostate and cancer cells and androgens. *Cancer Res* 1989; **49:** 3474–3481.
13. Brolin J, Skoog L, Ekman P. Immunohistochemistry and biochemistry in detection of androgen, progesterone, and estrogen receptors in benign and malignant human prostatic tissue. *Prostate* 1992; **20:** 281–295.
14. Veldscholte J, Ris-Stalpers CA, Kuiper GGJM, *et al.* A mutation in the ligand binding domain of the androgen receptor of human LNCaP cells affects steroid binding characteristics and response to anti-androgens. *Biochem Biophys Res Commun* 1990; **173:** 534–540.
15. Castagnetta LA, Miceli MD, Sorci CMG, *et al.* Growth of LNCaP human prostate cancer cells is stimulated by estradiol via its own receptor. *Endocrinology* 1995; **136:** 2309–2319.
16. Carruba G, Pfeffer U, Fecarotta E, *et al.* Estradiol inhibits growth of hormone non-responsive PC3 human prostate cancer cells. *Cancer Res* 1994; **54:** 1190–1193.
17. Aronica SM, Katzenellenbogen BS. Stimulation of estrogen receptor-mediated transcription and alteration in the phosphorylation state of the rat uterine estrogen receptor by estrogen, cyclic adenosine monophosphate, and insulin-like growth factor-I. *Mol Endocrinol* 1993; **7:** 743–752.
18. Ignar-Trowbridge DM, Teng CT, Ross KA, Parker MG, Korach KS, McLahlan JA. Peptide growth factors elicit estrogen receptor-dependent transcriptional activation of an estrogen-responsive element. *Mol Endocrinol* 1993; **7:** 992–998.
19. Beck CA, Weigel NL, Moyer ML, Nordeen SK, Edwards DP. The progesterone antagonist RU 486 acquires agonist activity upon stimulation of cAMP signalling pathways. *Proc Natl Acad Sci USA* 1993; **90:** 4441–4445.

20. Kaighn ME, Shankar Narayan K, Ohnuki Y, Lechner JF, Jones LW. Establishment and characterization of a human prostatic cell line (PC-3). *Int J Cancer* 1978; **21:** 274–281.
21. Stone KR, Mickey DD, Wunderli H, Mickey GH, Paulson DF. Isolation of a human prostate carcinoma cell line (DU 145). *Int J Cancer* 1978; **21:** 274–281.
22. Horoszewicz JS, Leoung SS, Kawinski E, *et al.* LNCaP model of human prostatic carcinoma. *Cancer Res* 1983; **43:** 1809–1818.
23. Mostofi FK, Sesterhenn IA, Sobin LH. Histological typing of prostate tumors. In: WHO Monograph Series No. 22. Geneva: WHO, 1980.
24. Culig Z, Klocker H, Eberle J, *et al.* DNA sequence of the androgen receptor in prostatic tumor cell lines and tissue specimens assessed by means of the polymerase chain reaction. *Prostate* 1993; **22:** 11–22.
25. EORTC Breast Cancer Cooperative Group. Revision of the standard for the assessment of hormone receptors in human breast cancer. *Eur J Cancer* 1980; **16:** 1513–1515.
26. Koenders A, Thorpe SM on behalf of the EORTC Receptor Group. Standardization of steroid receptor assays in human breast cancer. II. Samples with low receptor content. *Eur J Cancer* 1983; **19:** 1467–1472.
27. Berthoid Y, Katzenellenbogen JA, Katzenellenbogen BS. Phenol red in tissue culture media is a weak estrogen: implications concerning the study of estrogen-responsive cells in culture. *Proc Natl Acad Sci USA* 1990; **83:** 2496–2500.
28. Viljoen TC, van Aswegen CH, du Plessis DJ. Binding of estradiol to whole prostatic DU-145 cells in the presence and absence of tamoxifen and acetylsalicylic acid. *Prostate* 1995; **27:** 160–165.
29. Hobisch A, Culig Z, Radmayr C, Bartsch G, Klocker H, Hittmair A. Distant metastases from prostatic carcinoma express androgen receptor protein. *Cancer Res* 1995; **55:** 3068–3072.
30. Hobisch A, Culig Z, Radmayr C, Bartsch G, Klocker H, Hittmair A. Androgen receptor status of lymph node metastates from prostatic carcinoma. *Prostate* 1996; **28:** 129–135.
31. Taplin ME, Bubley GJ, Shuster TD, *et al.* Mutation of the androgen receptor gene in metastatic androgen-independent prostate cancer. *N Engl J Med* 1995; **332:** 1393–1398.
32. Culig Z, Hobisch A, Cronauer MV, *et al.* Androgen receptor activation in prostatic tumor cell lines by insulin-like growth factor-I, keratinocyte growth factor, and epidermal growth factor. *Cancer Res* 1994; **54:** 5474–5478.
33. Ikonen T, Palvimo JJ, Kallio PJ, Reinikainen P, Jänne OA. Stimulation of androgen-regulated transactivation by modulators of protein phosphorylation. *Endocrinology* 1994; **135:** 1359–1366.
34. Cooke PS, Young P, Hess RA, Cunha GR. Estrogen receptor expression in developing epididymis, efferent ductules, and other male reproductive organs. *Endocrinology* 1991; **128:** 2874–2879.
35. Ehara H, Koji T, Deguchi T, *et al.* Expression of estrogen receptor in diseased human prostate assessed by non-radioactive *in situ* hybridization and immunohistochemistry. *Prostate* 1995; **27:** 304–313.
36. Kirschenbaum A, Ren M, Erenburg I, Scachter B, Levine AC. Estrogen receptor messenger RNA in benign prostatic hyperplasia: detection, localization, and modulation with a long-acting gonadotropin-releasing hormone agonist. *J Androl* 1994; **15:** 528–533.
37. Kruithof-Dekker IG, Tetu B, Janssen PJA, van der Kwast TH. Elevated estrogen receptor expression in human prostatic stromal cells by androgen ablation therapy. *J Urol* 1996; **156:** 1194–1197.
38. Kemppainen JA, Lane MV, Sar M, Wilson EM. Androgen receptor phosphorylation, turnover, nuclear transport, and transcriptional activation. *J Biol Chem* 1992; **267:** 968–974.
39. Klocker H, Culig Z, Hobisch A, Cato ACB, Bartsch G. Androgen receptor alterations in prostatic carcinoma. *Prostate* 1994; **25:** 266–273.