Graefes Arch Clin Exp Ophthalmol (2009) 247:1285–1288
DOI 10.1007/s00417-009-1098-2

CASE REPORT

Intravitreal ranibizumab for choroidal neovascularization related to traumatic Bruch's membrane rupture

Feng Liang · Nathalie Puche · Gisèle Soubrane · Eric H. Souied

Received: 24 December 2008 / Revised: 3 April 2009 / Accepted: 16 April 2009 / Published online: 26 May 2009

Abstract
Purpose Choroidal neovascularization (CNV) secondary to traumatic rupture of Bruch's membrane is a rare condition, without standardized treatment. Here we describe one case of CNV related to traumatic rupture of Bruch's membrane which was successfully treated with intravitreal injection of ranibizumab.
Methods A 14-year-old patient was referred for ocular contusion, complicating interpapillomacular rupture of Bruch's membrane in left eye. Indeed, a correct initial visual acuity, juxtafoveolar CNV appeared 4 months later on the border of Bruch's membrane rupture. The patient was treated with an off-label intravitreal ranibizumab because of worsening of visual acuity.
Results One month after intravitreal injection, visual acuity improved, from 20/40 to 20/25. At 12-month follow-up, visual acuity remained at 20/25, fundus examination. Fluorescein angiography, indocyanine green angiography and optic coherence tomography showed fibrotic evolution of CNV. The Bruch's membrane rupture remained stable. No side-effect of intravitreal injection of ranibizumab was observed.
Conclusion For this patient affected with CNV secondary to traumatic Bruch's membrane, one single intravitreal ranibizumab injection was efficient, with 1-year follow-up.

The authors have no proprietary interest in the materials used in this study.

F. Liang · N. Puche · G. Soubrane · E. H. Souied (✉)
Department of Ophthalmology,
Centre Hospitalier Intercommunal de Creteil, Université Paris 12 ,
40 Avenue de Verdun,
Creteil 94000, France
e-mail: eric.souied@chicreteil.fr

Keywords Intravitreal ranibizumab · Lucentis · Bruch's membrane rupture · Choroidal neovascularization

Introduction

Traumatic Bruch's membrane rupture is a rare event, and choroidal neovascularization (CNV) may occur secondarily. Depending on CNV localization in relation to foveal area, multiple approaches to therapeutic management, including laser photocoagulation, photodynamic therapy or anti-vascular endothelial growth factor (VEGF), could be proposed.

In this interventional case report, we describe a case of a young patient affected with juxtafoveolar CNV, secondary to traumatic rupture of Bruch's membrane, who underwent treatment with intravitreal ranibizumab.

Case report

A 14-year-old boy was referred to our department for ocular contusion in the left eye, caused by a stone. Visual acuity (VA) was 20/32 in left eye and 20/20 in right eye. Clinical examination of left eye showed a wound to the upper eyelid, a cornea ulcer, a recession of angle and 1 + anterior chamber cells. Fundus examination revealed an inter-papillamacular rupture of Bruch's membrane and a peripapillary hemorrhage. Infra-red frames (IR), fluorescein angiography (FA) and optic coherence tomography (OCT; Heidelberg HRA Spectralis) confirmed existence of a Bruch's membrane rupture without other complications at presentation. Ophthalmologic examination of the right eye was normal. One week later, visual acuity increased to 20/25 in the left eye after complete resolution of cornea ulcer.

Four months later, the patient complained of slight intermittent blurring vision. Visual acuity had decreased to 20/40 in the left eye. FA showed early hyperfluorescence and late leakage on the border of rupture of Bruch's membrane, overlaying the macular area. Indocyanine green angiography (ICGA) showed a focal hyperfluorescence area corresponding to the presence of CNV (Fig. 1). OCT showed a moderately reflective lesion protruding from the retinal pigment epithelium, associated with serous detachment in the juxtafoveolar area. A complete ophthalmologic examination including FA and OCT was performed 2 weeks after the diagnosis of CNV, and no spontaneous improvement was observed.

Owing to the juxtafoveolar localization, progressing decreased VA and macular menace, patient was treated with one off-label intravitreal injection of ranibizumab 0.5 mg/0.05 ml (Genentech, Inc., South San Francisco, CA, USA) in left eye, after discussions and information of therapeutic options. Written informed consent was obtained from parents in accordance with the Declaration of Helsinki, French legislation and our local ethics committee.

At 1-month follow-up, VA had improved to 20/32. FA and ICGA showed absence of leakage of CNV at the borders of Bruch's membrane rupture. OCT revealed resolution of subretinal fluid. Follow-up was performed monthly during the first 3 months, and then quarterly until month 12. At 12-month follow-up, VA had improved to 20/25. FA and ICGA showed a fibrotic juxtafoveolar CNV, without leakage. OCT showed absence of recurrence of serous detachment.

Discussion

The pathogenesis of CNV implicated a variety of mechanisms, including breaks in the Bruch's membrane, inflammatory process and angiogenic stimuli [1]. The Bruch's membrane constituted a physiologic barrier to CNV development [2, 3]. Localized laser trauma to the Bruch's membrane in animal models has revealed an important implication of the central elastic lamina which have a

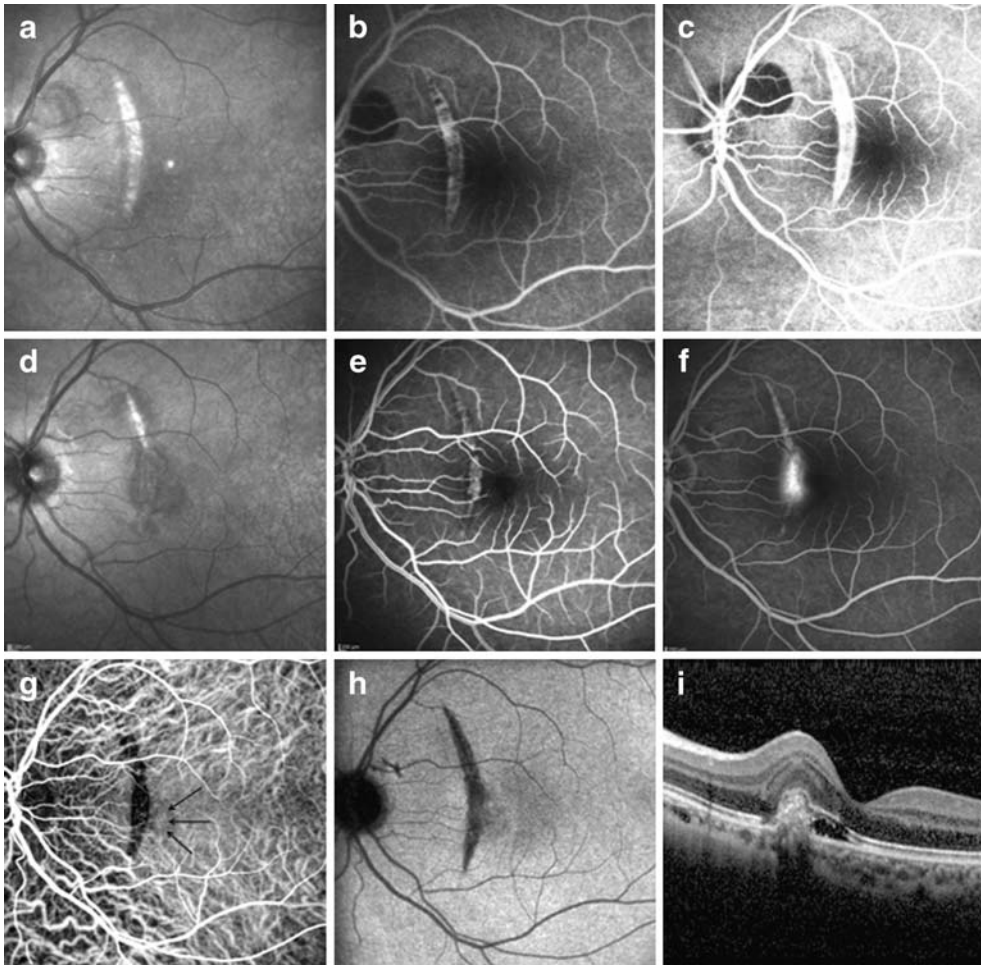

Fig. 1 Imaging of the Bruch's membrane rupture and occurrence of choroidal neovascularization (CNV). **a-c** Infrared and fluorescein angiography (FA) at the time of initial Bruch's membrane rupture. Peripapillary hemorrhage is observed, with absence of leakage. **d-f** Infrared and FA at 4 months after initial Bruch's membrane rupture. Horizontal line (**d**) indicates the localization of OCT scan (**i**). Late leakage is adjacent to the border of Bruch's membrane rupture. **g**,**h** Indocyanine green angiography, early phase and late phase, show hyperfluorescent lesion on the border of the rupture (*arrows*). **i** Spectralis optical coherence tomography confirms juxtafoveolar CNV localization with subretinal fluid

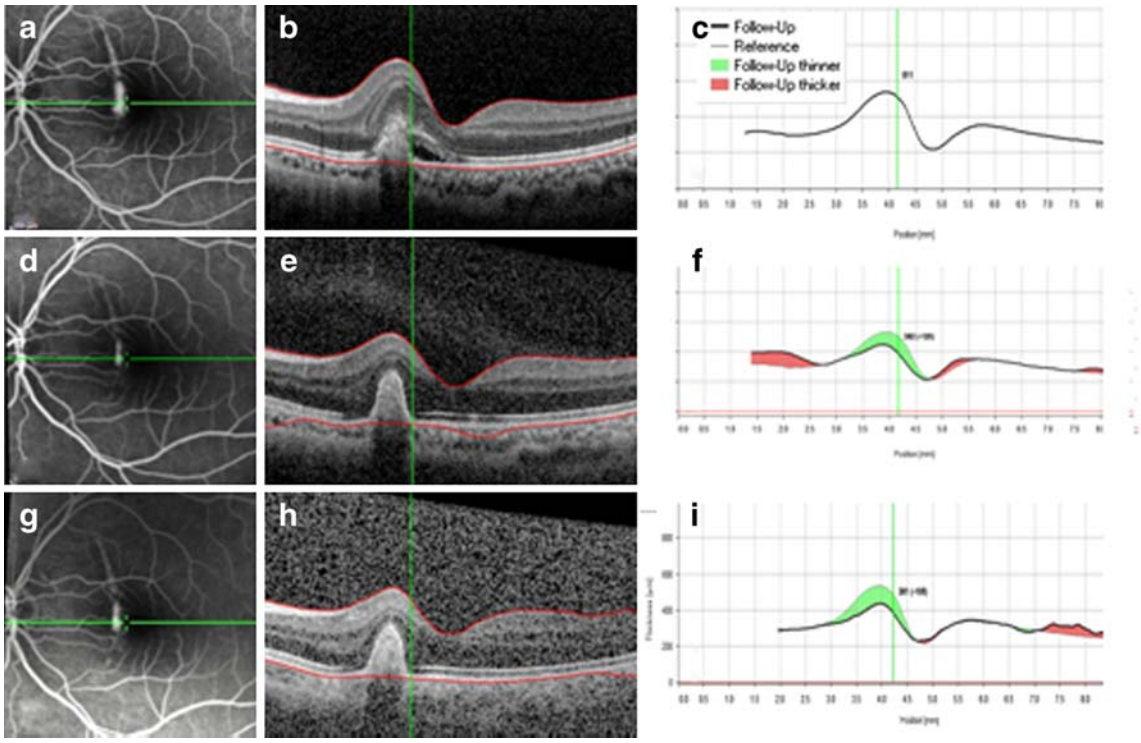

Fig. 2 Follow-up of choroidal neovascularization secondary to Bruch's membrane rupture before and after ranimizumab injection. **a**,**d**,**g** Fluorescein angiography before intravitreal ranibizumab injection, at 1-month follow-up and at 12-month follow-up. **b**,**e**,**h** Spectralis OCT before intravitreal ranibizumab injection, at 1-month follow-up and at 12-month follow-up. **c**,**f**,**i** Macular thickness profile before intravitreal ranibizumab injection, at 1-month follow-up and at 12-month follow-up. We observed a decrease of juxtafoveolar thickness for approximately 120 µm (*green area*) which corresponded to a complete resolution of subretinal fluid at 1-month follow-up. The lesion remained stable at 12-month follow-up

physical role of containment; a local higher level of elastin-derived peptides could also mediate VEGF upregulation. VEGF induce the proliferation and migration of vascular endothelial cells, resulting in neoangiogenesis and an increase in vascular permeability, leading to disruption of the blood-retina barrier.

In this case, disruption of the Bruch's membrane and inflammation secondary to trauma contributed to trigger upregulation of VEGF-A and angiogenesis process. Juxtafoveolar CNV appeared 4 months after initial rupture of the Bruch's membrane. One single intravitreal ranibizumab injection induced total regression of CNV, and vision improvement, at the 1-month follow-up (Fig. 2). A favorable outcome remained at the 12-month follow-up. No side-effects was observed.

Effective in the treatment of neovascular AMD, ranibizumab targets all active VEGF-A isoforms. It has been successfully used in off-label treatment of CNV in other retinal diseases in which VEGF is upregulated [4–8]: diabetic retinopathy, pathologic myopia, angioid streaks and central venous occlusion. Treatment for traumatic CNV has been recently described with anti-VEGF [8], but with a different drug, bevacizumab.

To our knowledge, this is the first report of the use of ranibizumab for CNV secondary to traumatic Bruch's membrane rupture. Security and safety of anti-VEGF therapy in teenagers remain to be established with more cases and long-term follow-up.

References

1. Bakri SJ, Snyder MR, Reid JM, Pulido JS, Ezzat MK, Singh RJ (2007) Pharmacokinetics of intravitreal ranibizumab(Lucentis). Ophthalmology 114:2179–2182, doi:10.1016/j.ophtha.2007.09.012
2. Deissler H, Deissler H, Lang S, Lang GE (2008) VEGF-induced effects on proliferation, migration and tight junctions are restored by ranibizumab(Lucentis) in microvascular retinal endothelial cells. Br J Ophthalmol 92:839–843, doi:10.1136/bjo.2007.135640
3. Yu HG, Liu X, Kiss S, Connolly E, Gragoudas ES, Michaud NA, Bulgakou OV, Adamian M, Deangelis, Miller JW, Li T, Kim IK (2008) Increased choroidal neovascularization following laser induction in mice lacking lysyl oxidase-like 1. Invest Ophthalmol Vis Sci 49:2599–2605, doi:10.1167/iovs.07-1508
4. Silva RM, Ruiz-Moreno JM, Nascimento J, Carneiro A, Rosa P, Barbosa A, Carvalheira F, Abreu JR, Cunha-Vaz JG (2008) Short-

term efficacy and safety of intravitreal ranibizumab for myopic choroidal neovascularization. Retina 28:1117–1123, doi:10.1097/IAE.0b013e31817eda41

5. Benevento JD, Jager RD, Noble AG, Latkany P, Mieler WF, Sautter M, Meyers S, Mets M, Grassi MA, Rabiah P, Boyer K, Swisher C, McLeod R (2008) Toxoplasmosis Study Group.Toxoplasmosis-associated neovascular lesions treated successfully with ranibizumab and antiparasitic therapy. Arch Ophthalmol 126:1152–1156, doi:10.1001/archopht.126.8.1152
6. Narayanan R, Shah VA (2008) Intravitreal bevacizumab in the management of choroidal neovascular membrane secondary to choroidal osteoma. Eur J Ophthalmol 18:466–468
7. Pieramici DJ, Rabena M, Castellarin AA, Nasir M, See R, Norton T, Sanchez A, Risard S, Avery RL (2008) Ranibizumab for the treatment of macular edema associated with perfused central retinal vein occlusions. Ophthalmology 115:e47–e54, doi:10.1016/j.ophtha.2008.06.021
8. Chanana B, Azad RV, Kumar N. Intravitreal bevacizumab for subfoveal choroidal neovascularization secondary to traumatic choroidal rupture. Eye, 2009 Jan 23. [Epub ahead of print]