Catheterization and Cardiovascular Diagnosis 45:409–412 (1998)

# Relief of Factitious Coarctation Following Occlusion of Large Patent Ductus Arteriosus With Gianturco-Grifka Vascular Occluder

**Frank F. Ing,[1]* MD, Charles E. Mullins,[1] MD, Stephen B. Wolfe,[2] MD, and Ronald G. Grifka,[1] MD**

**We report an infant with a large patent ductus arteriosus (PDA) and a hypoplastic aortic isthmus presenting with factitious coarctation due to high ductal flow. Following transcatheter occlusion of the PDA with a Gianturco-Grifka vascular occluder, the aortic gradient resolved, thereby eliminating the need for surgery on the isthmus. *Cathet. Cardiovasc. Diagn. 45:409–412, 1998.*** 

**Key words: patent ductus arteriosus; coarctation; occlusion; Gianturco-Grifka vascular occluder**

## INTRODUCTION

The coexistence of patent ductus arteriosus (PDA) with coarctation of the aorta (COA) or hypoplastic isthmus is well documented in the literature [1–3]. While percutaneous occlusion of the PDA has been demonstrated to be safe and effective, this procedure is rarely performed in the presence of COA or hypoplastic isthmus [4,5]. Instead, surgical repair of both lesions is usually performed. We report a patient presenting with echocardiographic evidence of a large PDA and coarctation with a hypoplastic isthmus. In the cardiac catheterization laboratory, the coarctation was found to be ''factitious'' due to left-to-right ductal shunting and increased flow across a hypoplastic isthmus. Test occlusion of the PDA demonstrated complete relief of the gradient across the isthmus. The ductus was occluded using a Gianturco-Grifka vascular occluder device (GGVOD) and surgery was avoided. This case demonstrates the value of measuring the hemodynamics of coexistent PDA and isthmic hypoplasia in the cardiac catheterization laboratory where test occlusion of the PDA can disclose exaggeration of the isthmic gradient and simple transcatheter ductal occlusion can avoid unnecessary surgical repair of the isthmus.

## CASE REPORT

A 4-month-old, 4.6-kg infant with Down syndrome presented with congestive heart failure. Cardiovascular findings included a grade III/VI continuous murmur heard over the left sternal border with wide radiation, a grade II/VI apical diastolic rumble, and a 12–22 mm Hg arm-leg pressure gradient by cuff blood pressure measurement. Echocardiography demonstrated a large PDA with continuous left-to-right shunting and a dilated left atrium and ventricle. The aortic isthmus appeared narrow with a Doppler velocity of 3–4 m/sec. At cardiac catheterization, right ventricular systolic pressure was found to equal 60% systemic arterial pressure and the Qp:Qs was 2.9:1. A 42–48 mm Hg systolic gradient across the isthmus was present (Fig. 1A). Aortography demonstrated a large tubular PDA (type C), which measured 5.3 mm in diameter at the aortic ampulla and a hypoplastic aortic ishmus with a minimum diameter of 3.9 mm (Fig. 2). The PDA was test-occluded with a 7-mm Gianturco-Grifka vascular occlusion device (Cook Inc., Bloomington, IN) (Fig. 3). Repeat pressure measurements across the isthmus demonstrated only a 5–10 mm Hg gradient (Fig. 1B) and the device was released. Pulmonary artery and right ventricular systolic pressures promptly decreased to 1/3 systemic arterial systolic pressure. Repeat aortography showed complete occlusion of the PDA, no change in the dimensions of the transverse aorta or isthmus, and no obstruction to aortic flow by the device (Fig. 4). A main pulmonary arteriogram demonstrated no obstruction of branch pulmonary flow by the device (Fig. 5). Cefazolin (12.5 mg/kg) was intravenously administered every 6 hr for four doses. Digoxin and Lasix were discontinued

[1]Department of Pediatric Cardiology, Baylor College of Medicine, Texas Children's Hospital, Houston, Texas
[2]Division of Pediatric Cardiology, University of Texas Houston Medical Center, Herman Hospital, Houston, Texas

*Correspondence to: Frank F. Ing, M.D., Children's Hospital of San Diego, Division of Pediatric Cardiology, 3020 Children's Way, San Diego, CA 92123.

Received 20 March 1998; Revision accepted 19 June 1998

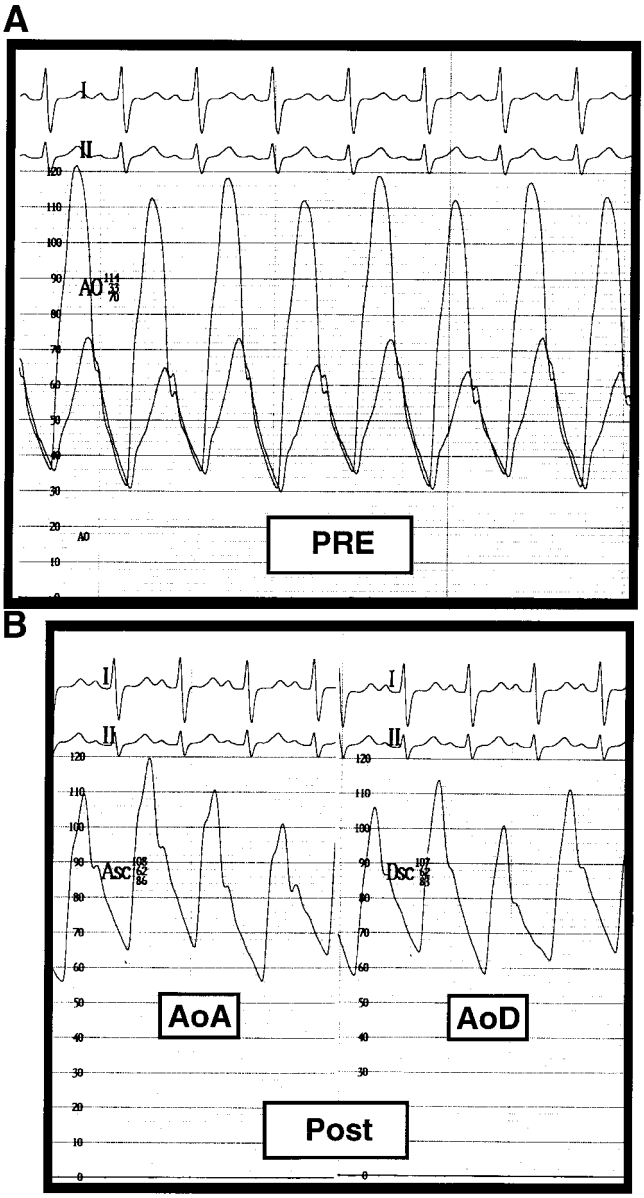


**Fig. 1. A: Simultaneous blood pressure recordings from the ascending and descending aorta prior to occlusion of the PDA showing a 42–48 mm Hg gradient. B: With the GGVOD implanted but not yet released within the PDA, a pull-back pressure recording from the ascending to descending aorta showed only a 5–10 mm Hg gradient.**

and the patient was discharged home the day following PDA occlusion. At 1, 6, and 16 month follow-up, there was no significant arm-leg gradient by cuff blood pressure measurement (3–8 mm Hg) and no evidence of systemic hypertension. Echocardiography demonstrated no residual shunting across the ductus, hypoplasia of the aortic isthmus, and mild acceleration of flow in the descending aorta (1.3–2.4 m/sec) without a diastolic gradient.

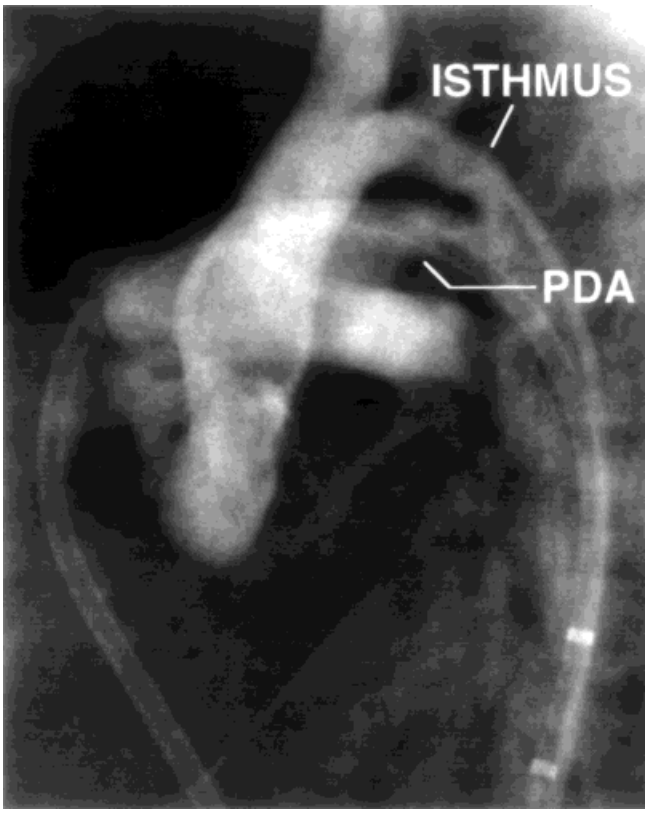


**Fig. 2. Descending aortogram demonstrating a large tubular PDA with an ampulla diameter of 5.3 mm and mild hypoplasia of the isthmus measuring 3.9 mm in diameter. A 10-mm marker catheter in the descending aorta was used as a measurement reference.**

## DISCUSSION

Despite the hypoplastic appearance of the aortic isthmus and the presence of a significant Doppler gradient in our patient, there was continuous left-to-right shunting via the PDA, suggesting that systemic output was not ductal-dependent and that the severity of the hypoplasia was probably exaggerated. Hence, we proceeded with cardiac catheterization and test occlusion of the PDA to determine whether the isthmus was severely hypoplastic. The retrievable feature of the new Gianturco-Grifka vascular occlusion device made it ideal for test occlusion of the PDA [6]. During test occlusion, no significant gradient persisted across the isthmus, confirming that the gradient found prior to test occlusion was indeed attributable to increased aortic flow caused by the large left-to-right shunt through the PDA (Qp:Qs = 2.9:1). Occlusion of the ductus removed the left-to-right shunt, normalized the arch flow, and thereby eliminated the pressure gradient despite a hypoplastic-appearing isthmus. At 16-month follow-up, no arm-leg blood pressure gradient had recurred, although Doppler echocardiography continued to

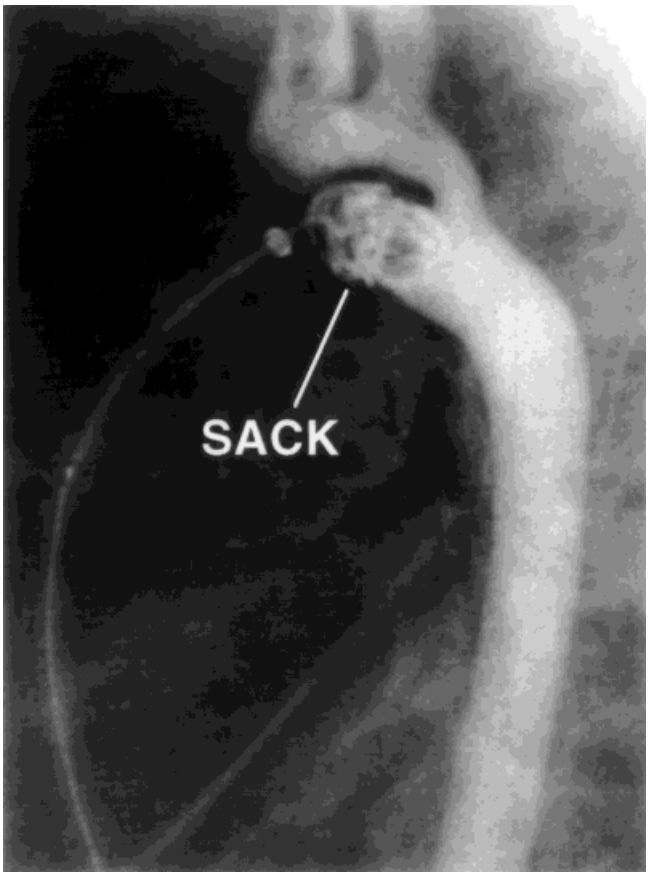


**Fig. 3. Descending aortogram with the GGVOD implanted but not yet released demonstrating total occlusion of the PDA and no change in the aortic dimensions.**

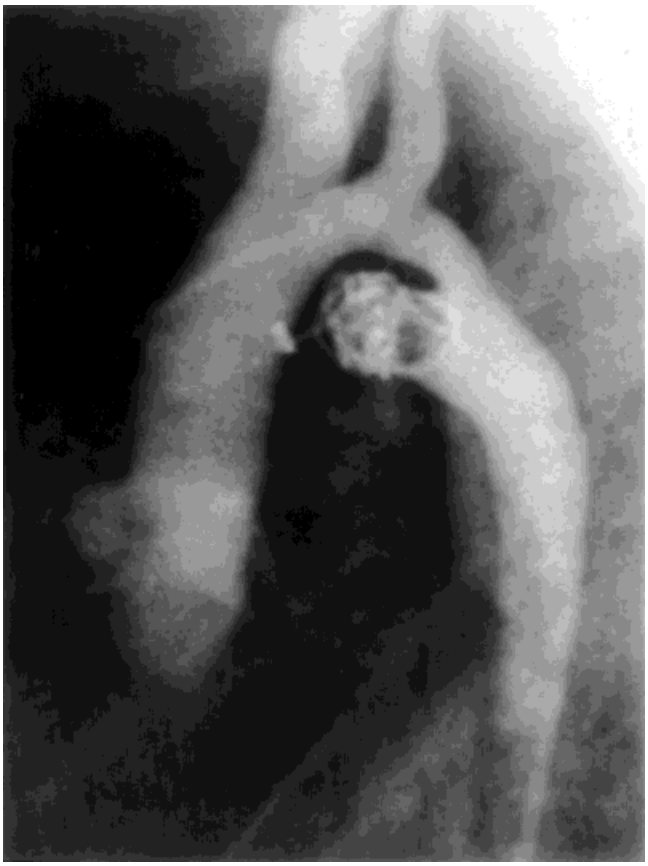

**Fig. 4. Descending aortogram after release of the GGVOD demonstrating no obstruction of aortic flow by the device.**

show mildly increased flow velocity in the descending aorta.

It is often possible to surgically repair coarctation of the aorta following echocardiographic diagnosis without cardiac catheterization [7]. However, it is important to distinguishing a significant Doppler gradient across true juxtaductal aortic coarctation from the gradient across a hypoplastic isthmus, which is exaggerated by the presence of a large PDA. When such a factitious coarctation is present, or if the arch anatomy is unclear, it is advantageous to evaluate the patient in the catheterization laboratory with test occlusion of the PDA. If factitious coarctation is present, the PDA can be occluded.

Interestingly, while obstruction from aortic coarctation can worsen with postnatal constriction of the ductus arteriosus, presumably due to projection of a posterior shelf into the aortic lumen, the opposite occurred in our case [2,3]. That is, the factitious coarctation across the hypoplastic isthmus was eliminated with closure of the ductus. A previous study involving transcatheter closure (Rashkind device) of PDAs as-

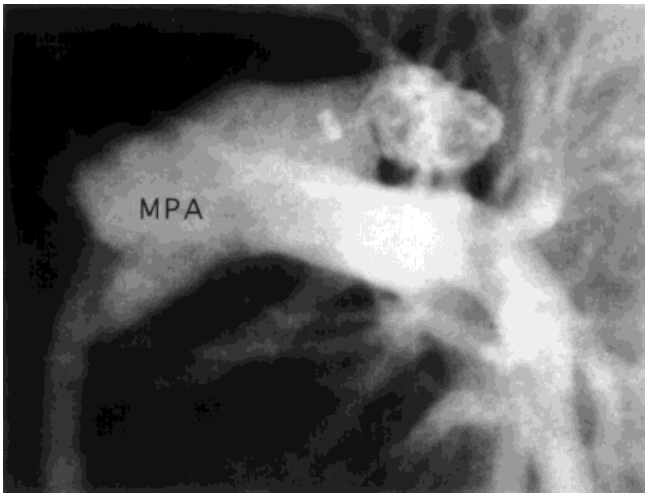


**Fig. 5. Lateral projection of main pulmonary arteriogram (MPA) demonstrating proper position of the GGVOD within the ductus and no obstruction of flow to the branch pulmonary arteries.**

sociated with mild isthmic hypoplasia reported safety and efficacy with no change in the isthmic gradient following the procedure [4]. However, all patients had a small PDA with a diameter ranging from 1.0 to 2.3 mm and very mild isthmic hypoplasia with 0–15 mm Hg gradients.

In conclusion, we report an infant with a large PDA and a hypoplastic aortic isthmus presenting with factitious coarctation due to high ductal flow. Following transcatheter occlusion of the PDA, the gradient resolved, thereby eliminating the need for surgery on the isthmus.

## REFERENCES

1. Behrer MR, Peterson FD, Goldring D, Crawford C: Coarctation of the aorta and associated patent ductus arteriosus. II. Postoperative studies in infants. J Pediatr 56:818, 1960.
2. Rudolph AM, Heymann MA, Spitznas U: Hemodynamic considerations in the development of narrowing of the aorta. Am J Cardiol 30:514–525, 1972.
3. Talner NS, Berman MA: Postnatal development of obstruction in coarctation of the aorta: Role of the ductus arteriosus. Pediatrics 56:562–569, 1975.
4. Nykanen DG, Hayes AM, Benson LN, Freedom RM: Transcatheter occlusion of the patent ductus arteriosus in the presence of mild isthmal hypoplasia. Cath Cardiovasc Diagn 29:273–276, 1993.
5. Ing FF, McMahon WS, Johnson GL, Vick W, Mullins CE: Single therapeutic catheterization to treat coexisting coarctation of the aorta and patent ductus arteriosus. Am J Cardiol 79:535–537, 1997.
6. Grifka RG, Ing FF, McMahon WS, Nihill MR, O'Laughlin MP, Morrow WR, Wiggins JW, Mullins CE: Transcatheter occlusion of patent ductus arteriosus and aorto-pulmonary collaterals using the Gianturco-Grifka vascular occlusion device. J Am Coll Cardiol 29(suppl A):172A, 1997.
7. George B, DiSessa TG, Williams R, Friedman WF, Laks H: Coarctation repair without cardiac catheterization in infants. Am Heart J 114:1421–1425, 1987.