Digestive Diseases and Sciences, Vol. 33, No. 2 (February 1988), pp. 185–188

Improvement of Oral Colonic Lavage with Supplemental Simethicone

WILLIAM A. SHAVER, MD, PATRICK STORMS, MD, and WALTER L. PETERSON, MD

We have noted that colons of patients prepared for colonoscopy with Golytely, a nonabsorbable electrolyte lavage solution, frequently contain foam which may obscure small mucosal lesions. Therefore, a randomized, blinded controlled trial was performed to determine the prevalence of Golytely-induced foam and the effect of supplemental simethicone in decreasing the prevalence of foam. Foam was present in 32% of colons prepared with Golytely alone but in none of the colons prepared with Golytely supplemented with simethicone. In addition, only 5% of colons prepared with supplemental simethicone had residual stool noted at the time of colonoscopy, a significant improvement over the 39% prevalence of residual stool in colons prepared with Golytely alone. Addition of simethicone to Golytely lavage decreases the prevalence of colonic foam and residual stool.

KEY WORDS: colonoscopy; colonic lavage; simethicone.

Oral administration of nonabsorbable electrolyte solutions has become the method of choice to prepare patients for colonoscopy. Clinical trials in which Golytely (Braintree Labs, Braintree, Massachusetts) has been utilized report up to 98% "good quality" preparations (1–5). However, we have frequently noted the presence of extensive foaming in colons of patients prepared in this manner (Figure 1), an occurrence which may obscure visualization of small mucosal or polypoid lesions. Simethicone has been shown to be effective in eliminating a similar problem with foam occurring during upper gastrointestinal endoscopy (6, 7). We report here the results of a randomized, blinded controlled trial designed to determine the frequency of occurrence of foam in colons prepared with Golytely and the effectiveness of supplemental simethicone in decreasing this frequency.

Manuscript received September 2, 1986; revised manuscript received November 18, 1986; accepted December 5, 1986.

From the Departments of Internal Medicine, Veterans Administration Medical Center, and The University of Texas Health Science Center at Dallas, Southwestern Medical School.

Dr. Shaver's current address is: Texas Tech University Health Science Center, School of Medicine, Department of Internal Medicine, Lubbock, Texas 79430.

Address for reprint requests: Dr. Walter L. Peterson, Gastroenterology 111B1, Dallas VA Medical Center, 4500 S. Lancaster Rd., Dallas, Texas 75216.

MATERIALS AND METHODS

One hundred twenty men scheduled to undergo elective colonoscopy were randomly assigned on the morning of their examination to receive Golytely or Golytely supplemented with simethicone. Sixty patients received Golytely alone as a control group (group I). Antifoam C Emulsion (Dow Corning Corporation, Midland, Michigan) containing 30% simethicone, 1.6% methyl cellulose, and 0.075% sorbic acid in water was administered to 30 patients mixed directly with Golytely at a concentration of 15 ml Antifoam per liter of solution (group IIA). Because the manufacturer advises against any additions to the Golytely formulation, an additional group was studied in which simethicone was administered as a separate oral dose. We anticipated approximately 5 liters of Golytely would be required by a typical patient, for a total Antifoam dosage of 75 ml. Therefore, 30 patients

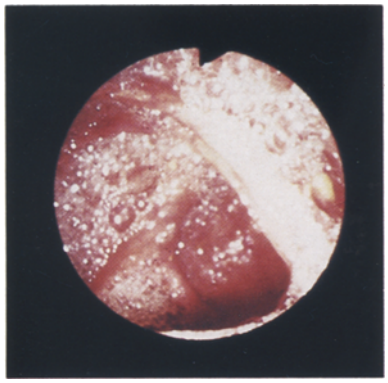

Fig 1. Colonoscopic photograph of foam obscuring colonic mucosa.

(group IIB) received 75 ml Antifoam as a separate oral dose given as 45 ml before and 30 ml after ingestion of Golytely. Patients were assigned to each group in random order.

A gastroenterology laboratory technician supervised administration of the appropriate preparation, encouraging patients to consume 240 ml Golytely every 15 min and recording the volume required to produce a clear rectal effluent. Colonoscopy was performed within 2 hr by two investigators who were unaware of which preparation the patient received. During colonoscopy, visual assessment was made of the presence or absence of colonic foam. To ensure that the addition of simethicone to Golytely would not in some way reduce overall cleansing of the colon, the presence or absence of residual particulate material in the colon was also noted in each patient. Only the complete absence of stool or particulate material qualified as a good preparation; all others were recorded as poor.

Volumes of lavage solution consumed among the groups were expressed as mean ± SEM and compared utilizing the unpaired Student's *t* test. The physicians' assessments of colonic foam and residual particulate material were analyzed by the chi-square method. *P* values less than 0.05 were considered significant.

This study was approved by the Human Studies Committee of the Dallas Veterans Administration Medical Center.

RESULTS

Five patients failed to complete the study. One patient in the control group refused colonoscopy. In the simethicone-treated group, one patient refused colonoscopy, one experienced persistent nausea and vomiting, another could not consume Golytely at a rate sufficient to produce cleansing, and a fourth patient's colonoscopy was cancelled due to an acute worsening of his chronic pulmonary disease. Clinical characteristics of the remaining 115 patients are shown in Table 1. There were no significant differences among the groups in ages or in indications for the procedure.

TABLE 1. CLINICAL CHARACTERISTICS OF STUDY POPULATION

	*Group I** (*N* = 59)	*Group IIA†* (*N* = 28)	*Group IIB‡* (*N* = 28)
Age (years)			
Mean ± SE	63.1 ± 1.5	62.3 ± 1.8	61.6 ± 1.6
Range	36–89	41–89	43–72
Indications (% each group)			
Polyp	56	53	61
Mass	13	18	31
Bleeding	29	25	8
Inflammatory bowel disease	2	4	0

*Golytely alone.
†Golytely plus 15 ml simethicone per liter.
‡Golytely plus 45 ml simethicone before Golytely and 30 ml simethicone after Golytely.

Results in patients receiving Golytely alone (group I) or Golytely plus supplemental simethicone are shown in Table 2. Since results in groups IIA and IIB were virtually identical, they were combined. Foam was present in group I in 19 of 59 patients (32%). Foam was present in none of the 56 patients who were administered simethicone (group II), $P < 0.005$ compared to group I. Residual particulate material was noted in 23 of 59 (39%) group I patients, but in only three of 56 (5%) of group II patients ($P < 0.005$). Differences in foam and residual stool noted between patients in group I and group II could not be explained by a difference in the volume of lavage solution consumed (Table 2). Furthermore, the presence of foam in a substantial portion of group I patients did not influence the colonoscopists' decision concerning residual stool. In group I patients, particulate material was present in 6/19 (32%) of colons where foam was present and in 17/40 (42%) of colons where foam was absent. The lack of a significant difference between these percentages makes it unlikely that the presence or

TABLE 2. RESULTS IN PATIENTS RECEIVING GOLYTELY ALONE OR GOLYTELY PLUS SIMETHICONE

	*Group I**		*Group II†*
Foam present	19/59 (32%)	($P < 0.005$)	0/56 (0%)
Residual particulate material present	23/59 (39%)	(*P* 0.005)	3/56 (5%)
Volume lavage solution consumed (liters)			
Mean ± SE	4.17 ± 0.19		4.23 ± 0.11
Range	2–8		2–6

*Golytely alone.
†Golytely plus simethicone.

absence of foam biased the investigator in independently assessing the cleanliness of the colon.

DISCUSSION

Although superior to the standard colon preparations in terms of efficacy and patient acceptance (1–5), Golytely still produces a suboptimal preparation in some patients, primarily in the right colon. In one report, 42% of colonoscopies completed to the right colon contained residual stool (5), which is similar to the 39% incidence in the present study. In other reports, presence of small amounts of stool was considered acceptable, which may account for the fact that preparations were considered poor in only 2–27% of colons (1–4).

The acceptance of even small amounts of residual stool is of concern in light of recent reports of potentially important pathology in colonic lesions less than 1 cm in size. Diminutive colon polyps, previously reported to be hyperplastic in a majority of cases (8), are now recognized as adenomatous polyps in greater than 50% of cases and increasingly more so in proximal segments of the colon (9–11). Although rare, carcinoma *in situ* and invasive carcinoma have been reported in lesions of this size (9, 12, 13). Also, approximately 20% of acute and chronic lower gastrointestinal bleeding is attributed to colonic angiodysplasia, which typically are less than 0.5 cm in size (14–16). Although there are no data to prove that small amounts of residual stool obscure important lesions, it seems reasonable that all measures should be taken to produce as complete a view of the mucosa as possible in order to ensure the maximum diagnostic and therapeutic benefits of colonoscopy.

Orally administered simethicone acts by decreasing surface tension which, in the stomach, leads to the coalescence of mucus-lined bubbles (6, 7). It is likely that the same mechanism is responsible for the similar beneficial effect of simethicone in the colon. Prior to the present study, we resolved the problem of colonoscopic foam by the local instillation of simethicone through a wash catheter or as an additive to the colonoscopic wash bottle. The former, however, added time to the procedure, and the latter has been noted to occlude the colonoscope if allowed to dry within the wash channel (personal communication, Olympus Corporation). We believe that oral supplementation of Golytely with simethicone either added directly to the lavage solution or given as separate oral doses represents a more efficient and inexpensive method of administering simethicone. The larger doses of Antifoam utilized in this study, in comparison to the usual single 15-ml dose preceding upper gastrointestinal endoscopy, were arbitrarily chosen to ensure that any potential benefit of the agent would not be diluted by the large volume of Golytely consumed in a typical preparation. It remains to be determined whether a smaller liquid dose or a tablet form of simethicone would have a similar beneficial response.

The failure of previous studies to note the occurrence of foam may have several explanations. First, foam may have been considered part of the increased colonic effluent noted to occur in Golytely-prepared colons (2). Second, investigators may not have considered foam important when compared to the presence of residual stool. Finally, in clinical practice Golytely is sometimes administered to patients the evening prior to colonoscopy. If the formation of foam is a transient phenomenon, such an interval between preparation and colonoscopy might explain the lack of foam.

In the original design of this study, observations on the amount of residual stool were intended to ensure that simethicone did not interfere with the cleansing action of Golytely. The marked improvement in overall quality of the preparation was unexpected, and the mechanism by which this improvement occurred is not clear. Regardless of the mechanism, the addition of simethicone to Golytely provides a simple and inexpensive means of improving the quality of colon preparation, both in terms of resolution of foam as well as superior overall cleansing. Thus, simethicone should be considered for addition to any oral lavage regimen administered several hours prior to the colonoscopic examination. It remains to be determined whether a similar beneficial response will occur in patients prepared the evening prior to colonoscopy. In the future, simethicone can perhaps be incorporated directly in oral colonic lavage solutions by the manufacturers, an even greater convenience for patients and physicians.

ACKNOWLEDGMENTS

The authors thank Brunette Moore, Shirley Gabriel, and Tyree Anders, Jr., for expert technical assistance; and Bobbie Bullard for typing the manuscript.

REFERENCES

1. Thomas G, Brozinsky S, Isenberg JI: Patient acceptance and effectiveness of a balanced lavage solution (Golytely) versus

the standard preparation for colonoscopy. Gastroenterology 82:435–437, 1982
2. Goldman J, Reichelderfer M: Evaluation of rapid colonoscopy preparation using a new gut lavage solution. Gastrointest Endosc 28:9–11, 1982
3. Adler M, Quenon M, Even-Adin P, Jeanmart J, VanGossum A, Bourgeois N, Cremer M: Whole gut lavage for colonoscopy–a comparison between two solutions. Gastrointest Endosc 30:65–67, 1984
4. DiPalma JA, Brady CE, Stewart DL, Karlin DA, McKinney MK, Clement DJ, Coleman TW, Pierson WP: Comparison of colon cleansing methods in preparation for colonoscopy. Gastroenterology 86:856–860, 1984
5. Ernstoff JJ, DeGrasia A, Marshall JB, Jumshyd A, McCullough AJ: A randomized blinded clinical trial of a rapid colonic lavage solution (Golytely) compared with standard preparation for colonoscopy and barium enema. Gastroenterology 84:1512–1516, 1983
6. Hirschowitz BI, Bolt RJ, Pollard HM: Defoaming in gastroscopy with silicone. Gastroenterology 27:649–651, 1954
7. Gasster M, Westwater JO, Molle WE: Use of a defoaming agent in gastroscopy. Gastroenterology 27:652–655, 1954
8. Lane N, Kaplan H, Pascal RR: Minute adenomatous and hyperplastic polyps of the colon: Divergent patterns of epithelial growth with specific associated mesenchymal changes. Gastroenterology 60:537–551, 1971
9. Wayne JD, Frankel A, Braunfeld SF: The histopathology of small colon polyps. Gastrointest Endosc 26:80, 1980 (abstract)
10. Tedesco FJ, Hendrix JG, Pickens CA, Brady PG, Mills LR: Diminutive polyps: Histopathology, spatial distribution, and clinical significance. Gastrointest Endosc 28:1–5, 1982
11. Feczko PJ, Bernstein MA, Halpert RD, Ackerman LV: Small colonic polyps: A reappraisal of their significance. Radiology 152:301–303, 1984
12. Shinya H, Wolff WI: Morphology, anatomic distribution and cancer potential of colonic polyps; an analysis of 7000 polyps endoscopically removed. Ann Surg 190:679–683, 1979
13. Spencer RJ, Melton LJ, Ready RL, Ilstrup DM: Treatment of small colorectal polyps: A population-based study of the risk of subsequent carcinoma. Mayo Clin Proc 59:305–310, 1984
14. Wright HK, Pelliccia O, Higgins E, Sreenivas V, Gupta A: Controlled, semielective, segmental resection for massive colonic hemorrhage. Am J Surg 139:535–538, 1980
15. Richter JM, Hedberg SE, Athanasoulis CA, Schapiro RH: Angiodysplasia: Clinical presentation and colonoscopic diagnosis. Dig Dis Sci 29:481–485, 1984
16. Hochter W, Weingart J, Kuhner E, Frimberger E, Ottenjam R: Angiodysplasia in the colon and rectum. Endoscopic morphology, localization and frequency. Endoscopy 17:182–185, 1985