J. Vet. Med. B 35, 84—95 (1988)

ISSN 0931—1793

Department of Veterinary Anatomy, University of Munich

Histological Evaluation of Wound Healing in Horses Treated with the Protein-Free Hemodialysate Solcoseryl and its Hexosylceramide Fraction

H. G. LIEBICH[1], D. HAMM[2] and W. JÖCHLE[3]

Address of authors: [1]Dept. of Veterinary Anatomy, University of Munich, Veterinärstr. 13, D-8000 München 22, FRG
[2]Research for Animal Health, Inc., Fayetteville, AR 72701, USA
[3]WOLFGANG JÖCHLE Assoc., Inc., Denville, NJ 07834, USA

With 10 figures and one table

(Received for publication November 17, 1987)

Summary

Histological evidence is presented from biopsies taken from burn wounds and surgical lesions in horses, treated double blind with Solcoseryl cream 5 %, the Solcoseryl Fraction 3 (4 ×) or (8 ×) in a cream base, and Placebo cream.

Solcoseryl treatment speeded up and enhanced tissue repair, i. e. wound healing.

Effects of Solcoseryl were characterized by an initially enhanced basophilic infiltration of the wound bed, but also an earlier decline in perivascular infiltration. Collagen fiber formation and arrangement occurred earlier, almost two weeks ahead of placebo treatment. Epithelization was well synchronized with advanced stages of tissue repair. This synchronization was less good and tissue repair in general less well organized in placebo treated animals.

Effects of Fraction 3 (8 ×) differed from Solcoseryl by showing less infiltration and less fiber forming activities, but showed earlier signs of fiber arrangement (scar formation) and earlier epithelization.

These results are in good agreement with highly significant clinical observations on wound size reduction over time and the clinical impression on epithelization (wound closure) in the same animals.

Key words: Wound healing, horse, hemodialysate, histological evaluation

Introduction

Solcoseryl (Solco Basle Ltd., Birsfelden, Switzerland) is a deproteinized, virtually non-toxic, non-antigenic and low-molecular hemodialysate of calf blood. Solcoseryl acts as a tissue repair factor in animals and man: its effects on wound healing, including burns, have been described in detail (HAIGIS, NASRIN-MONFARED et al., 1983; NIINIKOSKI and RENVALL, 1979) and are open to observations and measurements. Attempts to identify chemically defined entities responsible, at least in part, for these activities resulted in the isolation and purification of a fraction containing hexosylceramides (Fraction 3). In wound healing models in lab animals, Fraction 3 showed beneficial effects by increasing vascularization, cell formation and the accumulation of collagen and glycosamino glycans (FRAEFEL and TSCHANNEN, 1984; NIINIKOSKI, LAATO et al., 1984; NIINIKOSKI, RENVALL et al., 1986).

U.S. Copyright Clearance Center Code Statement: 0931—1793/88/3502—0084$02.50/0

Solcoseryl and its Fraction 3 were evaluated in double-blind trials in horses with experimental surgical lesions in the thoracolumbar regions, and with heat-cauterized punch wounds (burns) in the metacarpal region of each front leg (JÖCHLE and HAMM, 1983). Significant effects of Solcoseryl as well as of Fraction 3, used in two concentrations, were observed over placebo in both models, both products accelerated wound closure as well as epithelization (JÖCHLE and HAMM, 1983). The purpose of this study reported here was to evaluate histologically in a blind fashion biopsies taken from both kind of lesions during the course of this study. This evaluation focused on those parameters identifying the progress of tissue repair over time: the phagocytic, basophilic infiltration of the lesion and the penetration of the scab; the perivascular infiltration; the collagen fiber production, formation and arrangement in the lower and upper parts of the lesions, and their epithelization.

Material and Methods

Twenty four mature, healthy horses of the quarter horse type were used in this study. Under general anesthesia (tranquilization with acepromazine maleate; anesthesia with sodium thiamylate) wounds were induced on both sides of each animal in the anterior, middle, and posterior thoracolumbar region (3.5 × 7.0 cm and 6.8 cm apart) for a total of six thoracic wounds per animal. These wounds were induced by aseptic technique and penetrated through the subcutaneous tissue until the fascia was exposed. These wounds were regarded as "surgical lesions" with little necrosis.

Wounds were also induced on the anteriolateral aspect of each metacarpal region (six each leg, 1 cm in diameter and approximately 2.5 cm apart, in three rows). These wounds were surgically induced, penetrating to the subcutaneous tissues, then thoroughly cauterized with a conical red-hot iron (1 cm in diameter, 1 cm long) until bleeding stopped to induce surface necrosis. These leg wounds were regarded as "burns". All wounds, thoracic and metacarpal, were induced using a die to produce standardized wound sizes.

Four preparations were tested, using two letter codes for each preparation for blinding:

1. Solcoseryl cream, 5 %: Codes A and F.
2. Fraction 3 cream (4 × the yield in fraction 3): Codes D and G.
3. Fraction 3 cream (8 × the yield in fraction 3): Codes C and H.
4. Placebo cream (cream base used for preparations 1. to 3.): Codes E and B.

Horses were treated in three replicates of eight horses each. Animals were assigned to replicates, and within replicates to one of the coded test products, at random. Only the lesions on one side of each animal were treated; lesions on the contralateral side served as untreated controls. The side of treatment was determined at random. Test products were applied once daily, beginning on the 3rd day after wound inducement. The preparation was spread evenly over wounds as a thin film, less than 1 mm thick, but was not rubbed in. Treatment was continued until healing occurred in at least one set of wounds in any one animal. Neither antimicrobials nor any other medication was used simultaneously. The wounds were not bandaged. Observations were made and recorded every other day after treatment was initiated. The progress of wound healing was evaluated and rated according to the following criteria: (1) wound discharge type; (2) wound drainage; (3) granulation level; (4) epithelization (distance from edge of original wound); (5) scab quality; (6) wound size (measured every 3rd day).

Biopsies were taken from both types of the lesions, on days 14, 21, 28 and 35 after wound inducement. These biopsies, shaped like lemon wedges, ranged across the entire lesion, from healthy tissue to healthy tissue, and included the entire wound bed.

Biopsies were fixed in 4 % formaldehyde, embedded in paraffin, slides prepared and stained with hematoxilin-eosin.

A scoring system was used to evaluate the following parameters, at magnifications of 13 ×, 80 × and 200 ×:

1. Epithelization;
2. Basophilic cell infiltration of the surface of the lesions;
3. Basophilic cell infiltration of the lower region of lesions;
4. Perivascular cell infiltrations;
5. Changes in formation and organization of collagen fibers in the superficial regions of both types of lesion;
6. Changes in formation and organization of collagen fibers in the lower regions of both types of lesions.

7. Changes in the arrangement of newly formed collagen fibers in superficial regions of both types of lesions.

8. Changes in the arrangement of newly formed collagen fibers in the lower regions of both types of lesions.

Scores were based on the evaluation of three slides from each lesion. Details of the scores used are shown in the legends to Figs. 1 to 6.

Results

1. Comparison of the effects of treatments with SOLCOSERYL (SS) vs treatment with Placebo (PL)

As shown in Table 1 and in Figures 1 to 6, the picture at *day 14* of treatment indicates that in both kinds of lesions, the two treatments already show marked differences in the progress of healing:

While basophilic infiltrations in general are heavier with SS, perivascular infiltrations seem to have regressed and collagen fiber formation, especially in lower regions of both

Table 1. Histological Evaluation of Wound Healing Trial III with SOLCOSERYL and Placebo, Comparison of Scores for SOLCOSERYL 5 % Cream (SS) and Placebo (PL)

	Days of Treatment							
	14		21		28		35	
Parameter	SS	PL	SS	PL	SS	PL	SS	PL
1. Epithelization of burn wounds at the legs	0.5	0.5	0.6	1.5	2.4	2.7	3.3	3.3
2. Epithelization of surgical wounds at the thorax	0.2	0.5	0.3	1.4	1.8	1.4	1.6	2.2
3. Basophilic infiltration, superficial regions at the legs	3.3	1.6	3.0	2.8	1.6	2.0	1.7	1.3
4. Basophilic infiltration, lower regions, legs	1.6	1.0	1.8	1.3	0.6	1.2	0.6	1.1
5. Basophilic infiltration, superficial regions, thorax	3.6	1.8	2.8	3.2	1.2	2.0	1.4	1.8
6. Basophilic infiltration, lower regions, thorax	2.0	1.0	1.5	1.1	0.6	0.4	0.9	0.6
7. Perivascular infiltration, burn wounds, legs	2.8	3.0	2.4	3.1	1.1	1.8	1.3	1.7
8. Perivascular infiltration, surgical wounds, thorax	2.8	3.0	2.3	2.8	1.6	1.8	1.2	1.6
9. Collagen fiber formation, superficial regions, legs	0.9	0.2	1.9	0.3	2.6	1.3	2.5	1.8
10. Collagen fiber formation, lower regions, legs	2.2	0.5	3.0	0.8	3.8	2.3	3.4	2.3
11. Collagen fiber formation, superficial regions, thorax	1.1	0.1	2.0	0.9	3.5	1.7	3.0	1.7
12. Collagen fiber formation, lower regions, thorax	2.5	0.3	3.0	1.5	3.4	1.6	3.2	2.2
13. Arrangement of fibers, superficial regions, legs	1.0	0.5	1.5	1.1	1.7	1.5	1.8	1.8
14. Arrangement of fibers, lower regions, legs	1.2	1.0	1.6	1.1	2.3	1.7	2.7	2.2
15. Arrangement of fibers, superficial regions, thorax	1.0	0.5	1.5	0.8	1.8	1.3	1.8	1.9
16. Arrangement of fibers, lower regions, thorax	1.1	1.0	1.7	1.1	3.0	2.0	3.0	2.5

Legend: Underlined score values indicate a more advanced stage of tissue repair and wound healing.

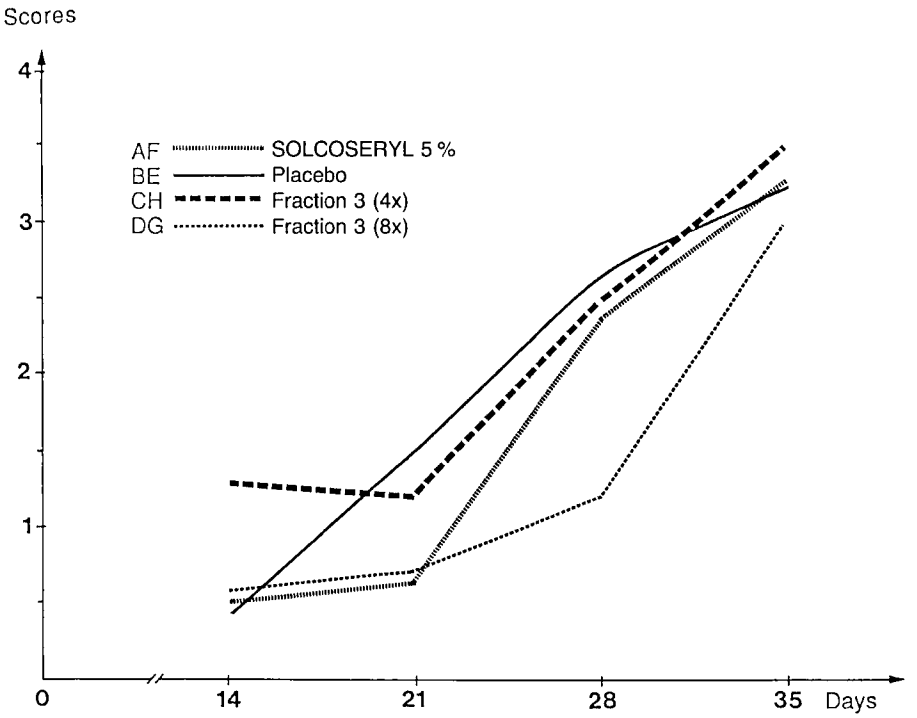

Fig. 1. Epithelization of Burn Wounds at the Front Legs in Response to Treatments
Score 0: No epithelization of importance.
Score 1: Insignificant formation of epithelium along the wound's rim.
Score 2: Significant epithelization, but limited to the wound's margin and little development of papillary bodies.
Score 3: Progressive epithelization and differentiation of papillary bodies.
Score 4: Epithelial cover complete with a well developed papillary body.

types of wounds, is in full progress; even first signs of fiber arrangement can be recognized. With PL treatment, little fiber formation or fiber arrangement is recognizable.

Little epithelization is seen with either SS or PL.

At *day 21*, basophilic infiltration, especially at the surface, is still heavier with SS, but perivascular infiltrations have receded ahead of PL. While SS stimulated increased fiber production in lower as well as superficial regions of both kinds of wounds, and clear movement toward their arrangement can be seen, PL treated animals are slow to follow and are > 8 days behind in fiber formation as well as fiber arrangement. But PL treatment seems to move epithelization ahead of SS at this stage, indicating a discrepancy in the steps of healing by advancing epithelization without sufficient tissue repair beneath.

At *day 28*, fiber formation in the SS group reaches its peak and is about two weeks ahead of PL, while fiber arrangement, especially in lower regions, is fully developed and well advanced, > 8 days ahead of PL.

Patterns of epithelization are now similar, but its advancement in the PL group is still out of synchronization with the connective tissue repair.

At *days 28 and 35*, basophilic and perivascular infiltrations have regressed faster with SS. Epithelization is almost complete with the smaller leg wounds at day 35, and less advanced at the larger wounds on the thorax. Tissue repair, i. e. fiber formation and fiber arrangement, are still clearly ahead in the SS group at this time and are approaching

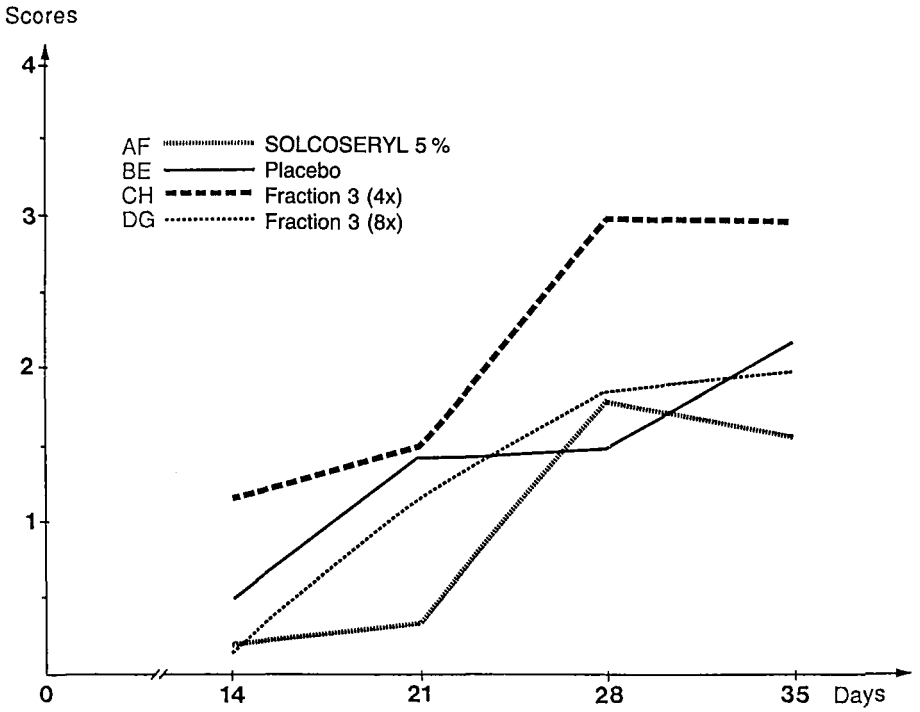

Fig. 2. Epithelization of Surgical Lesions at the Thorax in Response to Treatments
Score 0: No epithelization of importance.
Score 1: Insignificant formation of epithelium along the wound's rim.
Score 2: Significant epithelization, but limited to the wound's margin and little development of papillary bodies.
Score 3: Progressive epithelization and differentiation of papillary bodies.
Score 4: Epithelial cover complete with a well developed papillary body.

completion. Examples of treatment effects with SS and PL on collagen fiber formation and on basophilic cell infiltration on day 21, and on epithelization and capillarization on day 28, are shown in figures 7 and 8, and figures 9 and 10, respectively.

2. *Comparison of effects of treatment with SOLCOSERYL (SS) and Fraction 3 (F3)*

In general, treatments with F3 (4 ×) and F3 (8 ×) gave results similar to those with SS. Slight differences were seen with F3 (8 ×) on days 14 and 21 only: low levels of basophilic and perivascular infiltration were seen, accompanied by low levels of collagen fiber formation but simultaneously signs of advanced fiber arrangements and of epithelization.

3. *Comparison between treatment effects on surgical lesions and burns* (Table 1)

A parameter by parameter comparison of scores over time between surgical lesions and burns treated with *placebo cream* shows the following differences: Epithelization advances faster in burns, from day 21 on, and is about 50 % ahead by day 35.

Superficial basophilic infiltration levels differ only slightly, while at lower levels it disappears faster and earlier in surgical lesions. Perivascular infiltration scores are very similar, and so is the degree of collagen fiber formation in the upper level; in the lower level, formation of collagen fibers in burns seems ahead by day 28. Scores for arrangements of fibers, superficially and deeper, vary little between burns and surgical lesions.

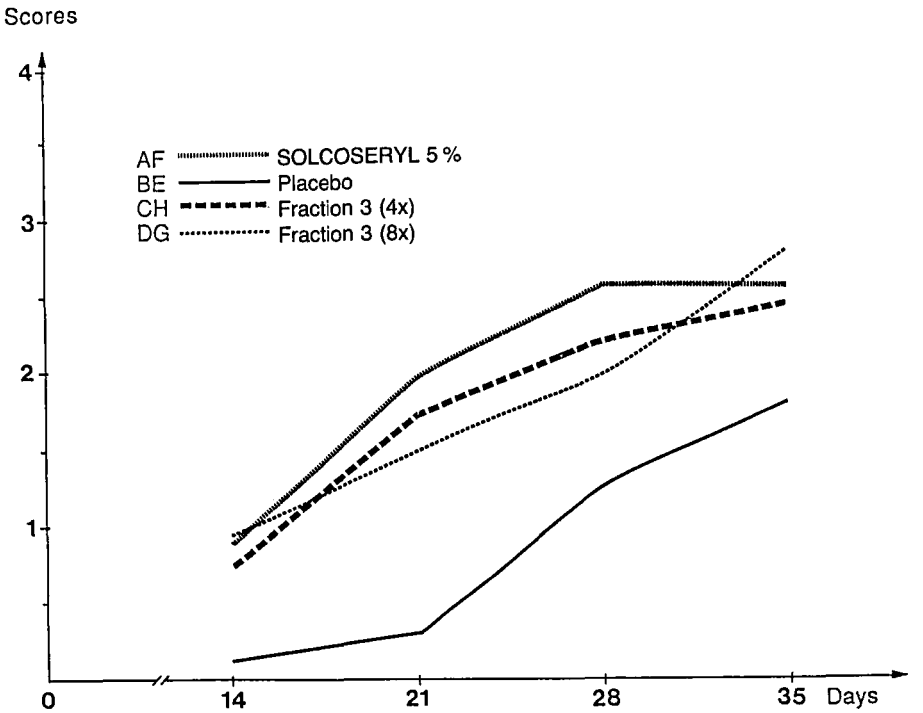

Fig. 3. Changes in the Organization by Collagen Fibers of Superficial Regions of Burn Wounds at the Front Legs in Response to Treatments (Determination via Polarization)
Score 0: No formation of collagen fibers.
Score 1: Sparse occurrence of filamentous, thin collagen fibers.
Score 2: Increased occurrence of spindle shaped, broader collagen fibers.
Score 3: Marked increase in bundles of collagen fibers.
Score 4: Thick, regularly broadened bundles of collagen fibers.

A comparison of *Solcoseryl treated* wounds reveals again a more rapid epithelization in burn wounds. Basophilic infiltrations disappear slightly ahead in surgical lesions, at least superficially. Perivascular infiltration scores are similar, with the exception of a lower score for burns at 28 days. Collagen fiber formation, superficially, is clearly more advanced with surgical lesions, while in the deeper regions of the wounds burns score higher on days 28 and 35. Fiber arrangement scores are very similar at the superficial level, but are more advanced in lower regions of surgical lesions from day 21 on.

Discussion

Treatment with Solcoseryl had clinically accelerated wound healing processes (Jöchle and Hamm, 1983). This histological evaluation of the same study revealed that Solcoseryl had beneficial effects on several of its parameters responsible for a functionally and cosmetically acceptable scar formation: Although treatment with Solcoseryl may have caused initially a more heavy basophilic infiltration, its decline in the perivascular region started earlier. Fiber formation and arrangement (scar formation) were clearly almost two weeks ahead of the placebo. Epithelization occurred when tissue repair had advanced and seemed well synchronized with it, while there was less synchronisation and slower, and possibly poorer tissue repair with the placebo. The effects Solcoseryl had on tissue repair

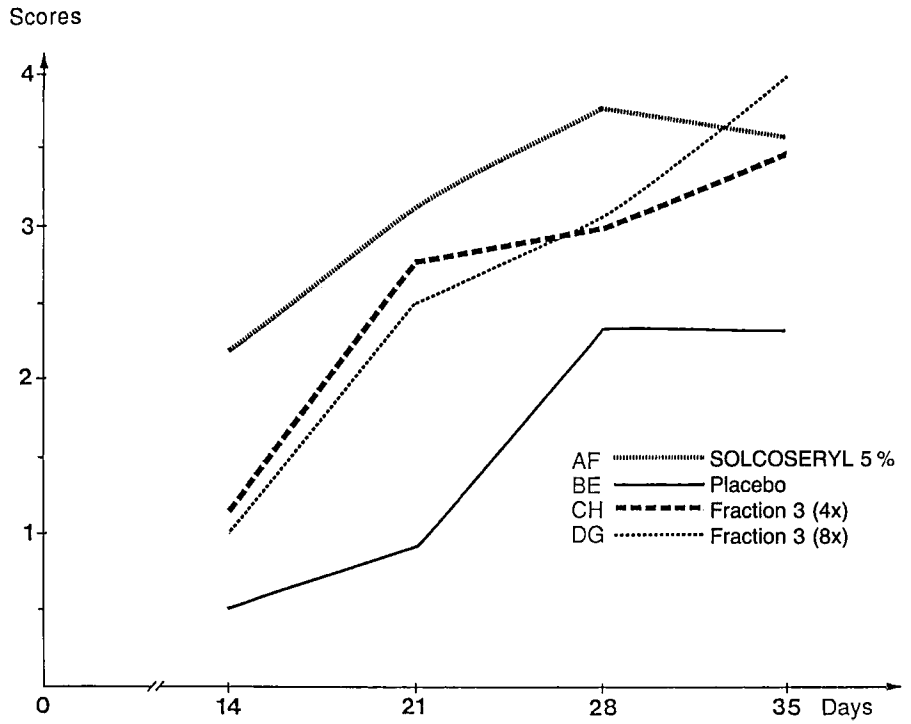

Fig. 4. (Legend, see next page)

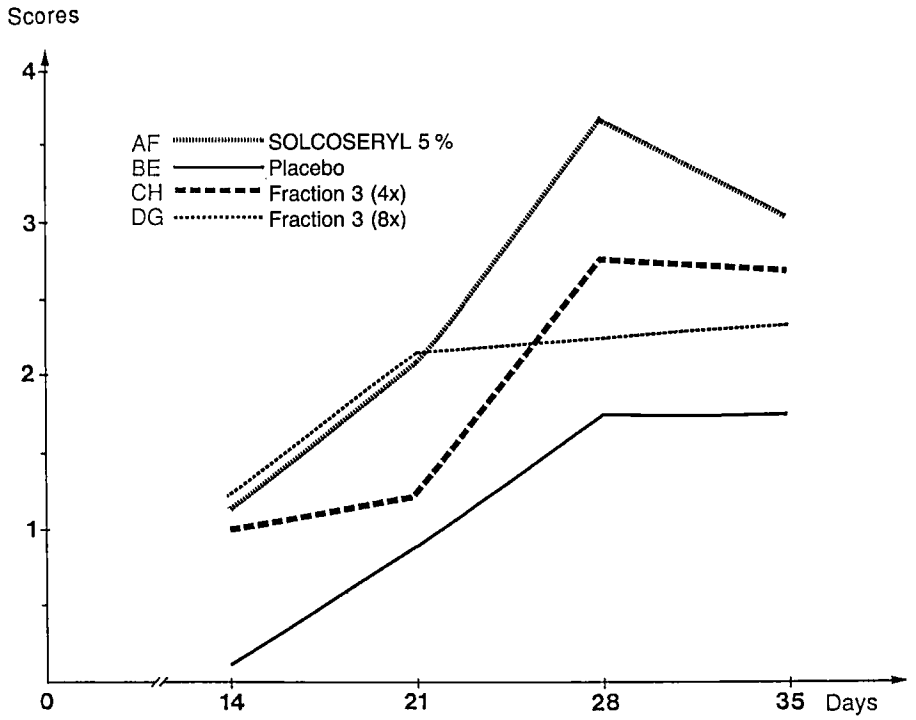

Fig. 5. (Legend, see next page)

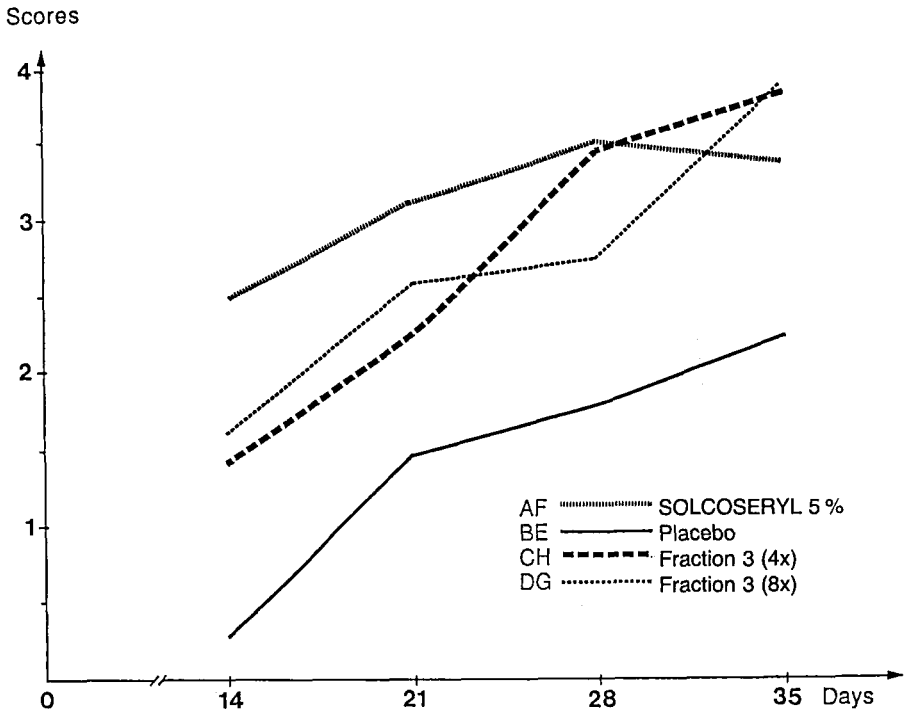

Fig. 6. Changes in the Organization by Collagen Fibers of Lower Regions of Surgical Wounds at the Thorax in Response to Treatment (Determination via Polarization)
Score 0: No formation of collagen fibers.
Score 1: Sparse occurrence of filamentous, thin collagen fibers.
Score 2: Increased occurrence of spindle shaped, broader collagen fibers.
Score 3: Marked increase in bundles of collagen fibers.
Score 4: Thick, regularly broadened bundles of collagen fibers.

Fig. 4. Changes in the Organization by Collagen Fibers of Lower Regions of Burn Wounds at the Front Legs in Response to Treatment (Determination via Polarization)
Score 0: No formation of collagen fibers.
Score 1: Sparse occurrence of filamentous, thin collagen fibers.
Score 2: Increased occurrence of spindle shaped, broader collagen fibers.
Score 3: Marked increase in bundles of collagen fibers.
Score 4: Thick, regularly broadened bundles of collagen fibers.

Fig. 5. Changes in the Organization by Collagen Fibers of Superficial Regions by Surgical Wounds at the Thorax in Response to Treatment (Determination via Polarization)
Score 0: No formation of collagen fibers.
Score 1: Sparse occurrence of filamentous, thin collagen fibers.
Score 2: Increased occurrence of spindle shaped, broader collagen fibers.
Score 3: Marked increase in bundles of collagen fibers.
Score 4: Thick, regularly broadened bundles of collagen fibers.

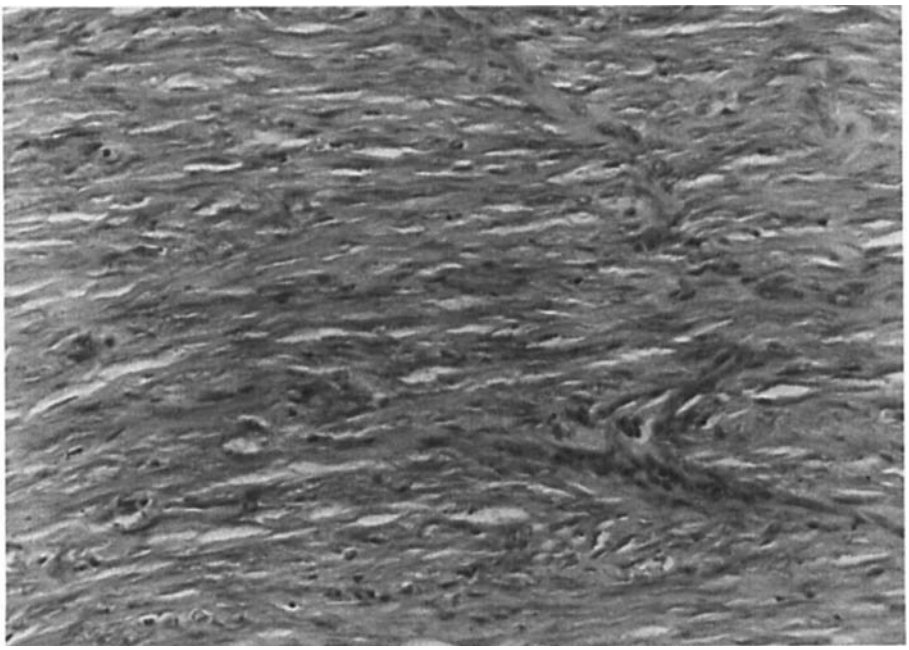

Fig. 7. Example of Solcoseryl treatment effects on collagen fiber formation in lower regions of experimental wounds in horses on day 21 of the study: Collagen fibers are already arranged in parallel bundles; little basophilic cell infiltration (Magnification: 140 ×)

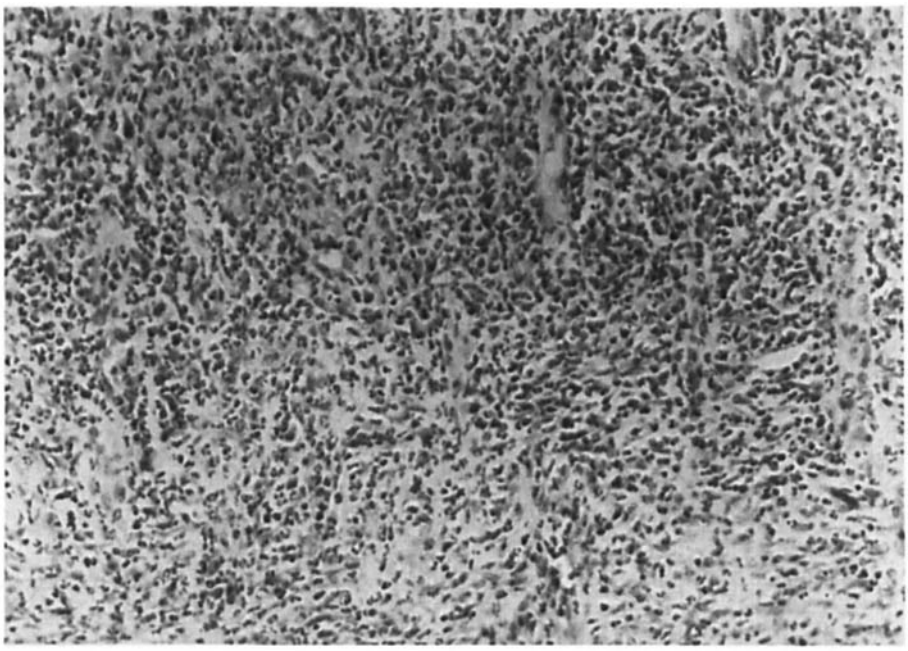

Fig. 8. Example of placebo treatment effects on collagen fiber formation in lower regions of experimental wounds in horses on day 21 of the study: Small bundles of collagen fibers have formed a loose, unstructured latticework; significant basophilic cell infiltration (Magnification: 140 ×)

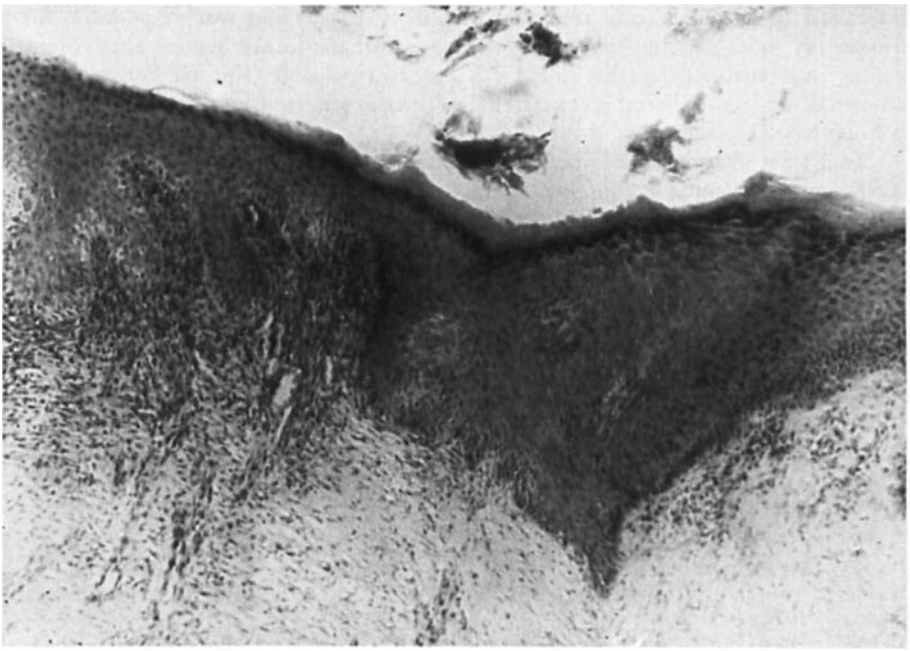

Fig. 9. Example of Solcoseryl treatment effects on epithelization of experimental wounds in horses, on day 28 of the study: Wound closure is almost complete due to epithelization, the development of a papillary body and adequate subepithelial angiogenesis (Magnification: 56 ×)

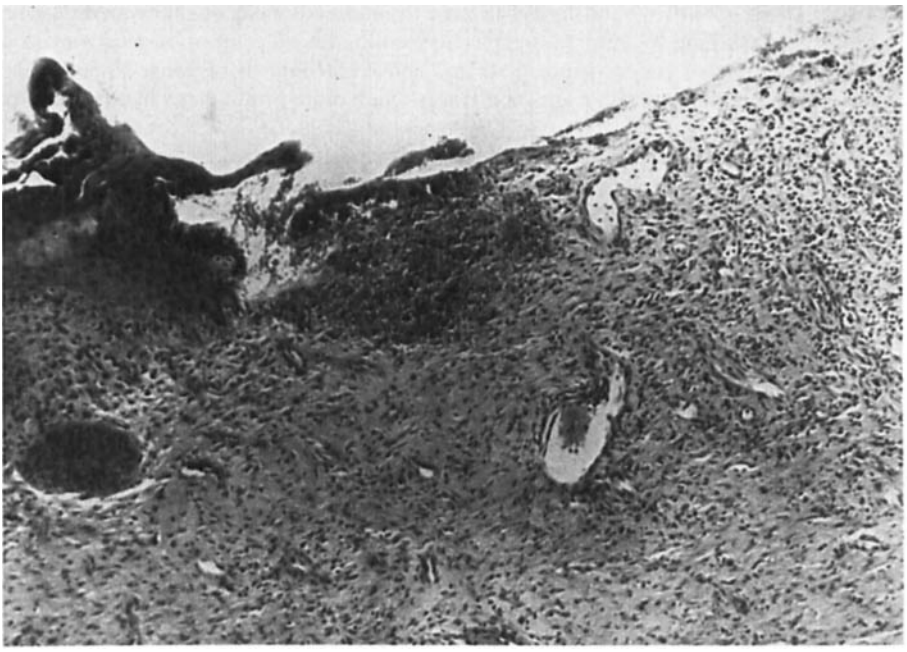

Fig. 10. Example of placebo treatment effects on epithelization of experimental wounds in horses, on day 28 of the study: Wound closure is not complete; remnants of fibrin are still detectable and unorganized bundles of collagen reach the surface. Subepithelial angiogenesis is poor (Magnification: 56 ×)

could lead to increased scar resistance (tensile strength) and was responsible for a cosmetically more pleasing appearance of the area of the former lesions after complete healing. Scars were smaller, less visible and less easily palpable. This had been repeatedly commented on by the clinical investigator (D. H.) as an attractive feature of treatment with Solcoseryl vs the placebo.

Treatment with the hexosylceramide Fraction 3 resulted in effects different from the placebo and very similar to those of Solcoseryl. Fraction 3 (8 ×) seems to have caused less infiltration and less fiber formation, but also earlier signs of fiber arrangement and of epithelization.

These effects of Solcoseryl and Fraction 3 on histological parameters of wound healing are in agreement with the clinical observations on wound size and wound closure in the same horses (JÖCHLE and HAMM, 1983). They are in general agreement with data and observations on wound healing in *in vitro* models. Those studies indicated that Solcoseryl repaired reversibly damaged cells in culture, e. g. fibroblasts, and hastened the return to a normal replication rate (FRAEFEL and TSCHANNEN, 1984). Solcoseryl increased in accordance with cell proliferation the transport of glucose, resulting via the availability of easily metabolized substrate in a high ATP/ADP ratio. This in turn allows cells to function and multiply better in an adverse environment (FRAEFEL and TSCHANNEN, 1984) created by surgical lesions or burns. Consequently, granulation tissue hemoglobin was increased in one very detailed study by 21 %, and the DNA content and that of collagen hydroxyproline in granulation tissue of rats by 48 % and 31 %, respectively (NIINIKOSKI and RENVALL, 1979).

These effects may have been caused by a change-over of tissue metabolism, under the influence of Solcoseryl, from anaerobic to more aerobic pathways, known to favor collagen formation (NIINIKOSKI and RENVALL, 1979). Simultaneously, angiogenesis in artificial wounds was accelerated by Solcoseryl in rats (NIINIKOSKI and RENVALL, 1979) and by its Fraction 3 in rabbits (NIINIKOSKI, LAATO et al., 1984; NIINIKOSKI, RENVALL et al., 1986). Using a burn wound model in rats, thymidine uptake was measured 21 days after injury, confirming by autoradiography in histological slides from biopsies a marked increase in the rate of cell division in stroma and epithelium in response to Solcoseryl (ROHR, 1984). Simultaneously, angiogenesis was much more pronounced in burns treated with Solcoseryl.

Similar studies with Fraction 3 revealed an increase in wound tissue DNA by 35 % (< 0.01), and a significant elevation in RNA-ribose, and in collagen hydroxyproline and in glycosamino glycans as well (NIINIKOSKI, RENVALL et al., 1986).

Together all these Solcoseryl related changes in wound healing characteristics translated into a significantly increased tensile strength of surgical lesions in rats which were closed by sutures, after 6 and 12 days (NIEBAUER, DORCSI et al., 1980).

Observations made in the study reported here in horses are complemented as well as interpreted by these observations from Solcoseryl treatment effects in lab animals. Altogether, they provide a background for understanding the beneficial clinical effects Solcoseryl is known to exert on wound healing in animals (FACKELMAN, 1973; FICUS and JÖCHLE, 1984; JÖCHLE and HAMM, 1983; LEBIS, 1983; SHOKRY, FOUAD et al., 1981) and man (HAIGIS, NASRIN-MONFARED et al., 1985). Our observations and these studies underline the importance of early and complete wound bed repair before epithelization occurs. The correct timing of cellular infiltration and of its removal, of collagen fiber formation and of its organization, of vascularization and of growing over by the epithelium when the time is right, together constitutes satisfactory tissue repair. The result is a functional as well as esthetically acceptable scar, and the prevention of excessive granulation (proud flesh), of hypertrophic scars or of hypotrophic scars with low tensile strength. Our results have shown that treatment with Solcoseryl resulted in a tissue repair pattern combining accelerated wound bed repair with early epithelial wound closure. These patterns and their satisfying results, were similar with surgical lesions and with burn wounds in horses treated topically with Solcoseryl.

Zusammenfassung

Histologische Untersuchung der Wundheilung bei Pferden nach Behandlung mit dem proteinfreien Hämodialysat Solcoseryl und dessen Hexosylceramid-Fraktion

In einer Doppelblind-Studie wurden Biopsien von chirurgischen Läsionen und Brandwunden bei Pferden histologisch untersucht, die mit einer 5%igen Solcoseryl Creme, einer Creme mit der Solcoseryl Fraktion 3 (4 ×) oder (8 ×), oder mit einer Plazebo Creme behandelt worden waren.

Die Behandlung mit Solcoseryl und mit der Fraktion 3 begünstigte die Gewebs-Reparaturvorgänge und verkürzte damit die Zeit für die Wundheilung.

Solcoseryl zeigte seine Wirkungen zuerst durch eine verstärkte basophile Infiltration des Wundbettes, aber auch eine frühere Reduzierung perivaskulärer Infiltration. Die Kollagenfaser-Bildung und deren typische Organisation waren etwa zwei Wochen früher als mit dem Plazebo erkennbar. Epithelisierung war gut mit der rascher fortschreitenden Gewebsreparatur synchronisiert. Mit dem Plazebo war diese Synchronisation deutlich weniger gut ausgeprägt und die Gewebsreparatur-Vorgänge waren weniger gut organisiert.

Wirkungen der Fraktion 3 (8 ×) unterschieden sich vom Solcoseryl durch geringere Infiltration als auch geringere Kollagenfaser-Bildung, dafür waren Faser-Anordnung und Epithelisierung früher erkennbar.

Diese Ergebnisse stimmen gut mit den hochsignifikanten klinischen Beobachtungen über den Ablauf des Wundverschlusses bei den gleichen Tieren überein.

References

1. Bradley, W. E. C., and L. A. Culp, 1974: Stimulation of 2-deoxyglucose uptake in growth-inhibited BALB/c 3 T 3 and revertant SV 40-transformed 3 T 3 cells. Experimental Cell Research **84**, 335—350.
2. Fackelman, G. E., 1973: A new technique of skin transplantation and a preliminary evaluation of the effects of Solcoseryl on graft acceptance. Equine Vet. J. **5**, 105—110.
3. Ficus, H. J., und W. Jöchle, 1984: Wirkungen eines oral verabreichten, proteinfreien Dialysates aus Kälberblut (Solcoseryl/Actimhaemyl) auf postoperative Wundheilung und Komplikationen nach ein- oder beidseitiger Mammaleisten-Amputation bei der Hündin. Kleintierpraxis **29**, 233—241.
4. Fraefel, W., and R. Tschannen, 1984: Isolation and partial characterization of a proliferation enhancing Fraction of Solcoseryl. A paper presented at the 2nd Assembly of Cytoprotection Research Society on Feb. 1984 in Tokyo.
5. Haigis, E., H. Nasrin-Monfared, R. Tschannen, and W. Fraefel, 1985: Biological and clinical profile of Solcoseryl. Care of the Burn Wound, Int. Congr. Geneva 1983, pp. 70—76 (Karger, Basel).
6. Jöchle, W., and D. Hamm, 1983: Effects of topical treatment with Solcoseryl and its fraction 3 on wound healing after burns and surgical lesions in horses. Care of the Burn Wound, Int. Congr. Geneva 1983, pp. 84—89 (Karger, Basel).
7. Lebis, C., 1983: Contribution a l'étude de la cicatrisation des plaies. Expérimentation clinique d'un extrait déprotéine de sang de veau: Solcoseryl (N. D.). Vet. Med. Diss., Ecole Nat. Vet. Nantes, France.
8. Niebauer, G. W., M. Dorci und L. Pfeil, 1980: Die Wirkung von homöopathischen Arnica D und Actihaemyl (Solcoseryl) auf die Wundheilung im Tierexperiment. Der praktische Tierarzt, **61**, 128—132.
9. Niinikoski, J., and S. Renvall, 1979: Effect of a deproteinized blood extract on experimental granulation tissue. Acta Chir. Scand. **145**, 287—291.
10. Niinikoski, J., M. Laato, R. Tschannen, and W. Fraefel, 1984: Effect of a hexosylceramide fraction of the hemodialysate Solcoseryl on wound healing angiogenesis. European Surg. Res. Supp. 16/51, 106—107.
11. Niinikoski, J., S. Renvall, M. Laato, R. Tschannen, and W. Fraefel, 1986: Effect of a hexosylceramide fraction of the hemodialysate Solcoseryl on experimental granulation tissue. European Surg. Res. **18**, 58—64.
12. Rohr, H. P., 1984: The effect of Solcoseryl treatment on angiogenesis and reepithelization of burn wounds in rats. To be published.
13. Shokry, M., S. Fouad, M. Abd Al-Rahim, and G. F. Rifat, 1981: Evaluation of the effect of Solcoseryl on wound healing in animals. Egyptian Vet. Med. J. **XXIX**/29.